



National Comprehensive
Cancer Network®

NCCN Clinical Practice Guidelines in Oncology (NCCN Guidelines®)

Melanoma: Uveal

Version 2.2021 — June 25, 2021

NCCN.org

Continue



National
Comprehensive
Cancer
Network®

NCCN Guidelines Version 2.2021

Melanoma: Uveal

[NCCN Guidelines Index](#)
[Table of Contents](#)
[Discussion](#)

***Susan M. Swetter, MD/Chair** ☐
Stanford Cancer Institute

***John A. Thompson, MD** ‡ †/Vice-Chair
Fred Hutchinson Cancer Research Center/
Seattle Cancer Care Alliance

Mark R. Albertini, MD †
University of Wisconsin
Carbone Cancer Center

Christopher A. Barker, MD §
Memorial Sloan Kettering Cancer Center

Joel Baumgartner, MD ¶
UC San Diego Moores Cancer Center

Genevieve Boland, MD, PhD ¶
Massachusetts General Hospital
Cancer Center

Bartosz Chmielowski, MD, PhD ‡ †
UCLA Jonsson Comprehensive
Cancer Center

Dominick DiMaio, MD ≠
Fred & Pamela Buffett Cancer Center

Alison Durham, MD ☐
University of Michigan
Rogel Cancer Center

Ryan C. Fields, MD ¶
Siteman Cancer Center at Barnes-
Jewish Hospital and Washington
University School of Medicine

Martin D. Fleming, MD ¶
The University of Tennessee
Health Science Center

Anjela Galan, MD ≠
Yale Cancer Center/
Smilow Cancer Hospital

NCCN
Nicole McMillian, MS
Mai Nguyen, PhD

Brian Gastman, MD ¶
Case Comprehensive Cancer Center/
University Hospitals Seidman Cancer
Center and Cleveland Clinic Taussig
Cancer Institute

Kenneth Grossmann, MD, PhD †
Huntsman Cancer Institute
at the University of Utah

Samantha Guild ¥
AIM at Melanoma

Ashley Holder, MD ¶
O'Neal Comprehensive
Cancer Center at UAB

Douglas Johnson, MD, MSCI †
Vanderbilt-Ingram Cancer Center

Richard W. Joseph, MD ‡ †
Mayo Clinic Cancer Center

Giorgos Karakousis, MD ¶
Abramson Cancer Center at the
University of Pennsylvania

Kari Kendra, MD, PhD †
The Ohio State University Comprehensive
Cancer Center - James Cancer Hospital
and Solove Research Institute

Julie R. Lange, MD, ScM ¶
The Sidney Kimmel Comprehensive
Cancer Center at Johns Hopkins

Ryan Lanning, MD, PhD §
University of Colorado Cancer Center

Kim Margolin, MD †
City of Hope National Medical Center

Miguel Materin, MD ☐
Duke Cancer Institute

Anthony J. Olszanski, MD, RPh †
Fox Chase Cancer Center

Patrick A. Ott, MD, PhD † ‡ †
Dana-Farber/Brigham and Women's
Cancer Center

***P. Kumar Rao, MD** ☐
Siteman Cancer Center at Barnes-
Jewish Hospital and Washington
University School of Medicine

Ramesh Rengan, MD, PhD §
Fred Hutchinson Cancer Research Center/
Seattle Cancer Care Alliance

Merrick I. Ross, MD ¶
The University of Texas
MD Anderson Cancer Center

April K. Salama, MD †
Duke Cancer Institute

Rohit Sharma, MD ¶
UT Southwestern Simmons
Comprehensive Cancer Center

Joseph Skitzki, MD ¶
Roswell Park Cancer Institute

Jeffrey Sosman, MD ‡
Robert H. Lurie Comprehensive Cancer
Center of Northwestern University

Katy Tsai, MD †
UCSF Helen Diller Family Comprehensive
Cancer Center

Evan Wuthrick, MD §
Moffitt Cancer Center

☐ Dermatology	¥ Patient advocacy
‡ Hematology/ Hematology oncology	§ Radiotherapy/ Radiation oncology
† Internal medicine	¶ Surgery/Surgical oncology
† Medical oncology	* Discussion Section Writing Committee
☐ Ophthalmology	
≠ Pathology	

Continue



National
Comprehensive
Cancer
Network®

NCCN Guidelines Version 2.2021

Melanoma: Uveal

[NCCN Guidelines Index](#)
[Table of Contents](#)
[Discussion](#)

UVEAL MELANOMA SUBCOMMITTEE

***P. Kumar Rao, MD/Lead**

Siteman Cancer Center at Barnes-Jewish
Hospital and Washington University School of
Medicine

Christopher A. Barker, MD §

Memorial Sloan Kettering Cancer Center

Samantha Guild ¥

AIM at Melanoma

Richard Joseph, MD ‡ †

Mayo Clinic Cancer Center

Miguel Materin, MD

Duke Cancer Institute

Ramesh Rengan, MD, PhD §

Fred Hutchinson Cancer Research Center/
Seattle Cancer Care Alliance

Jeffrey Sosman, MD ‡

Robert H. Lurie Comprehensive Cancer
Center of Northwestern University

***Susan Swetter, MD** ⚡

Stanford Cancer Institute

***John A. Thompson, MD** ‡ †

Fred Hutchinson Cancer Research
Center/Seattle Cancer Care Alliance

Evan Wuthrick, MD §

Moffitt Cancer Center

[NCCN Guidelines Panel Disclosures](#)

Continue

⚡ Dermatology
‡ Hematology/Hematology oncology
† Medical oncology
 Ophthalmology
¥ Patient advocacy
§ Radiotherapy/Radiation oncology
* Discussion Section Writing Committee



National
Comprehensive
Cancer
Network®

NCCN Guidelines Version 2.2021

Melanoma: Uveal

[NCCN Guidelines Index](#)
[Table of Contents](#)
[Discussion](#)

[NCCN Uveal Melanoma Panel Members](#)
[NCCN Uveal Melanoma Subcommittee Members](#)
[Summary of the Guidelines Updates](#)

[Clinical Presentation, Workup and Diagnosis, Clinical Staging \(UM-1\)](#)
[Workup and Staging, Tumor Size, Primary Treatment \(UM-2\)](#)
[Additional Primary Treatment \(UM-3\)](#)
[Systemic Imaging Based on Risk Stratification \(UM-4\)](#)
[Treatment for Recurrence \(UM-5\)](#)
[Treatment of Metastatic Disease \(UM-6\)](#)

[Risk Factors for Development of Uveal Melanoma \(UM-A\)](#)
[Principles of Radiation Therapy \(UM-B\)](#)
[Systemic Therapy for Distant Metastatic Disease \(UM-C\)](#)

[Staging \(ST-1\)](#)

Clinical Trials: NCCN believes that the best management for any patient with cancer is in a clinical trial. Participation in clinical trials is especially encouraged.

Find an NCCN Member Institution:
<https://www.nccn.org/home/member-institutions>.

NCCN Categories of Evidence and Consensus: All recommendations are category 2A unless otherwise indicated.

See [NCCN Categories of Evidence and Consensus](#).

NCCN Categories of Preference: All recommendations are considered appropriate.

See [NCCN Categories of Preference](#).

The NCCN Guidelines® are a statement of evidence and consensus of the authors regarding their views of currently accepted approaches to treatment. Any clinician seeking to apply or consult the NCCN Guidelines is expected to use independent medical judgment in the context of individual clinical circumstances to determine any patient's care or treatment. The National Comprehensive Cancer Network® (NCCN®) makes no representations or warranties of any kind regarding their content, use or application and disclaims any responsibility for their application or use in any way. The NCCN Guidelines are copyrighted by National Comprehensive Cancer Network®. All rights reserved. The NCCN Guidelines and the illustrations herein may not be reproduced in any form without the express written permission of NCCN. ©2021.



Updates in Version 2.2021 of the NCCN Guidelines for Melanoma: Uveal from Version 1.2021 include:

MS-1

- The Discussion has been updated to reflect the changes in the algorithm.

Updates in Version 1.2021 of the NCCN Guidelines for Melanoma: Uveal from Version 3.2020 include:

General

- The Guideline name changed from Uveal Melanoma to *Melanoma: Uveal*.

UM-1

- Workup and Diagnosis, First bullet:
 - ▶ First arrow sub-bullet revised: "H&P, including *personal/family* history of prior or current cancers (outside the eye)" and footnote b added.
 - ▶ Third arrow sub-bullet revised: *Ocular* ultrasound of eye and orbit.
- Footnote d revised: "...Biopsy of the primary tumor ~~does not impact outcome, but~~ may provide prognostic information that can help inform frequency of follow-up and may be needed for eligibility for clinical trials. If biopsy is performed, molecular/*chromosomal* testing for prognostication (~~chromosome analysis or gene expression profiling [GEP]~~) is preferred over cytology alone..." (Also for UM-2A)

UM-2

- Tumor size: The largest diameter was revised as follows:
 - ▶ Largest diameter ~~5–48~~ 5–19 mm and thickness <2.5 mm
 - ▶ Largest diameter ~~≤48~~ ≤19 mm and thickness 2.5–10 mm
 - ▶ Largest diameter ~~≥48~~ >19 mm [any thickness] or Thickness >10 mm...

UM-2A

- Footnote u is new: Pathologic evaluation should follow the uveal melanoma synoptic report recommendations by the College of American Pathologists. Available at: <https://documents.cap.org/protocols/cp-uveal-melanoma-17protocol-4000.pdf>
- Footnote p revised: "...The largest commercially available brachytherapy plaque is ~~22~~ 23 mm in diameter; thus, plaque brachytherapy is recommended only for tumors with largest basal diameter ~~≤48~~ ≤19 mm.

UM-3

- Footnote v regarding "Extraocular extension at the time of enucleation" is new: This is a relatively rare occurrence; data are limited for these recommendations.

UM-4

- First column recommendation revised: Systemic imaging ± blood tests based on risk stratification by genetic testing ± tumor size and histology (at presentation).
- Risk of Distant Metastasis: Under High risk, the following were removed:
 - ▶ Extraocular extension
 - ▶ Ciliary body involvement
- Footnote dd revised: "... Additional imaging modalities may include chest/abdominal/pelvic CT with contrast, *or dual energy subtraction chest x-ray*. However, screening should..."
- Footnote ee is new: 8q gain, especially when numerous copies are found portends greater risk for metastasis.

UM-6

- Treatment of Metastatic Disease:
 - ▶ After "No evidence of disease" revised: Clinical trial, *if available* (preferred).
 - ▶ After "Residual or progressive disease" the arrow was redrawn for clarity.

[Continued](#)

UPDATES



Updates in Version 1.2021 of the NCCN Guidelines for Melanoma: Uveal from Version 3.2020 include:

UM-A Risk Factors for Development of Uveal Melanoma

- First bullet:

- ▶ Third arrow sub-bullet revised: Familial uveal melanoma (eg, germline *mutations in BAP1 mutation, PALB-2, MBD4, or NF-1* (neurofibromatosis) [NF-1], dysplastic nevus syndrome [BK-mole])
- ▶ Three new arrow sub-bullets added:
 - ◊ Higher numbers of atypical cutaneous nevi, common cutaneous nevi, and/or cutaneous freckles
 - ◊ Light skin color, propensity to sunburn, and/or light eye (iris) color
 - ◊ Strong personal or family history of cancer

- Footnote b is new:

- ▶ Evaluate for evidence of hereditary syndrome and refer for genetic counseling and testing if indicated:
 - ◊ Early age of diagnosis (<30 years of age)
 - ◊ History of other primary cancers in the patient
 - ◊ Family or personal history of other cancers known to be associated with a hereditary syndrome:
 - *BAP1*: RCC, mesothelioma, cutaneous melanoma, cholangiocarcinoma, meningioma
 - *BRCA*, *PALB2*: breast, ovarian, or pancreatic cancers

- New references were added.

UM-B Principles of Radiation Therapy

1 of 3

- Treatment Information

- ▶ Second arrow sub-bullet revised: Plaque brachytherapy is appropriate for patients with tumors ≤ 18 ≤ 19 mm in largest base diameter, ≤ 10 mm in thickness
- ▶ Fifth arrow sub-bullet revised: "...MRI or CT may be used for preoperative planning."
- ▶ Sixth arrow sub-bullet revised: Round or custom plaques are most commonly used; ~~although non-round plaques (eg, notched) can be considered for tumors in specific locations (eg, peripapillary). Custom plaques, such as notched plaques, are commonly used for tumors in specific locations (peripapillary).~~
- Treatment Dosing Information, first arrow sub-bullet revised: "...The largest commercially available brachytherapy plaque is 22 23 mm in diameter; thus, plaque brachytherapy is recommended only for tumors with largest basal diameter ≤ 18 ≤ 19 mm.

2 of 3

- Radioembolization, first bullet revised: Selective internal radiation therapy for patients with liver metastases using yttrium-90 has been reported in retrospective studies *and in one prospective study.*

3 of 3

- References updated.

UM-C Systemic Therapy for Distant Metastatic Disease

- Preferred regimens revised:

- ▶ ~~Clinical trial~~ *When available and clinically appropriate, enrollment in a clinical trial is recommended.*
- Footnote a revised: ~~When available and clinically appropriate, enrollment in a clinical trial is recommended.~~ The literature is not directive regarding the specific systemic agent(s) offering superior outcomes, but does provide evidence that uveal melanoma is sensitive to some of the same systemic therapies used to treat cutaneous melanoma. Although there are no systemic therapies that have reliably improved the overall survival in patients with metastatic uveal melanoma, individual patients may derive ~~substantial~~ benefit on occasion. Given the lack of positive phase III studies, clinical trials are preferred.
- New references were added for nivolumab/ipilimumab.



NCCN Guidelines Version 2.2021

Melanoma: Uveal

CLINICAL PRESENTATION

- Suspicious pigmented uveal tumor of ciliary body and/or choroid^a
 - ▶ Symptoms may include:
 - ◊ Vision loss
 - ◊ Vision changes (eg, blurred vision, photopsia, floaters, metamorphopsia)
 - ▶ May be asymptomatic
 - ▶ Assessment of risk factors for developing uveal melanoma^b

WORKUP AND DIAGNOSIS

- Clinical evaluation, including:
 - ▶ H&P, including personal/family history of prior or current cancers (outside the eye)^b
 - ▶ Color fundus photography
 - ▶ Ocular ultrasound
 - ▶ Comprehensive eye exam: Examine the front and back of eye (biomicroscopy)
 - ◊ Dilated fundus exam (indirect ophthalmoscopy)
 - ◊ Measure visual acuity
 - ◊ Measure and document location and the size of the tumor (diameter, thickness), distance from disc and fovea, and ciliary body involvement
 - ◊ Assess and document if present:
 - Subretinal fluid
 - Orange pigment
- Additional testing options include:
 - ▶ Autofluorescence of the ocular fundus
 - ▶ Optical coherence tomography
 - ▶ Retinal fluorescein angiography of the ocular fundus
 - ▶ Transillumination
 - ▶ MRI occasionally needed to confirm diagnosis
- Consider biopsy if needed to confirm diagnosis^c or for prognostic analysis for risk stratification^d

CLINICAL STAGING

Diagnosis uncertain and/or <3 risk factors for growth^e

Observe and re-evaluate for growth or features of malignancy^f

- Every 2–4 months^g as clinically indicated
- Then close follow-up for 5 years^g
- Then annually thereafter

Uveal melanoma

See Workup and Staging for uveal melanoma [\(UM-2\)](#)

^a This guideline does not include the management of iris melanoma.

^b [See Risk Factors for Development of Uveal Melanoma \(UM-A\).](#)

^c Biopsy is usually not necessary for initial diagnosis of uveal melanoma and selection of first-line treatment, but may be useful in cases of uncertainty regarding diagnosis, such as for amelanotic tumors, or retinal detachment.

^d Biopsy of the primary tumor may provide prognostic information that can help inform frequency of follow-up and may be needed for eligibility for clinical trials. If biopsy is performed, molecular/chromosomal testing for prognostication is preferred over cytology alone. The risks/benefits of biopsy for prognostic analysis should be carefully considered and discussed.

^e Risk factors for growth of small melanocytic tumors: presence of symptoms, tumor thickness >2 mm, tumor diameter >5 mm, presence of subretinal fluid and orange pigment, tumor margin within 3 mm of optic disk, ultrasound hollowness, absence of halo.

^f The recommendation to "observe and re-evaluate" consists of tests listed under "Workup and Diagnosis" that would help to clarify if there is progression and determine the natural history of the indeterminate lesion.

^g Frequency of evaluation should depend on index of suspicion, patient age, and medical frailty.

Note: All recommendations are category 2A unless otherwise indicated.

Clinical Trials: NCCN believes that the best management of any patient with cancer is in a clinical trial. Participation in clinical trials is especially encouraged.



NCCN Guidelines Version 2.2021

Melanoma: Uveal

WORKUP AND STAGING

- Ocular imaging if not previously done:
 - ▶ If large tumor, close to nerve or suspicion of extraocular involvement, MRI of orbit with and without IV contrast^h
- Assess and document, if present:
 - ▶ Ciliary body involvement
 - ▶ Extraocular extension
- Extraocular imaging:
 - ▶ Baseline imaging to screen for distant disease^{h,i,j}
- Consider biopsy of primary tumor for prognostic analysis^d

TUMOR SIZE

Largest diameter 5–19 mm^k and thickness <2.5 mm

Largest diameter ≤19 mm^k and thickness 2.5–10 mm

Largest diameter >19 mm^k [any thickness]
or Thickness >10 mm [any diameter]
or Thickness >8 mm with optic nerve involvement [any diameter]

Metastasis^l

PRIMARY TREATMENT^{m,n}

- Options:
 - ▶ Brachytherapy plaque^{o,p,q}
 - ▶ Particle beam radiation^o
- Other options in highly select patients^r

- Options:
 - Brachytherapy plaque^{o,p,q,s}
 - Particle beam radiation^{o,s}
 - Enucleation^{t,u}

- Options:
 - RT
 - ▶ Particle beam radiation^{o,s}
 - ▶ Stereotactic radiosurgery (SRS)^o
 - Enucleation^{t,u}

[See Additional Primary Treatment \(UM-3\)](#)

[See UM-6](#)

See Footnotes on [UM-2A](#)

Note: All recommendations are category 2A unless otherwise indicated.

Clinical Trials: NCCN believes that the best management of any patient with cancer is in a clinical trial. Participation in clinical trials is especially encouraged.



FOOTNOTES

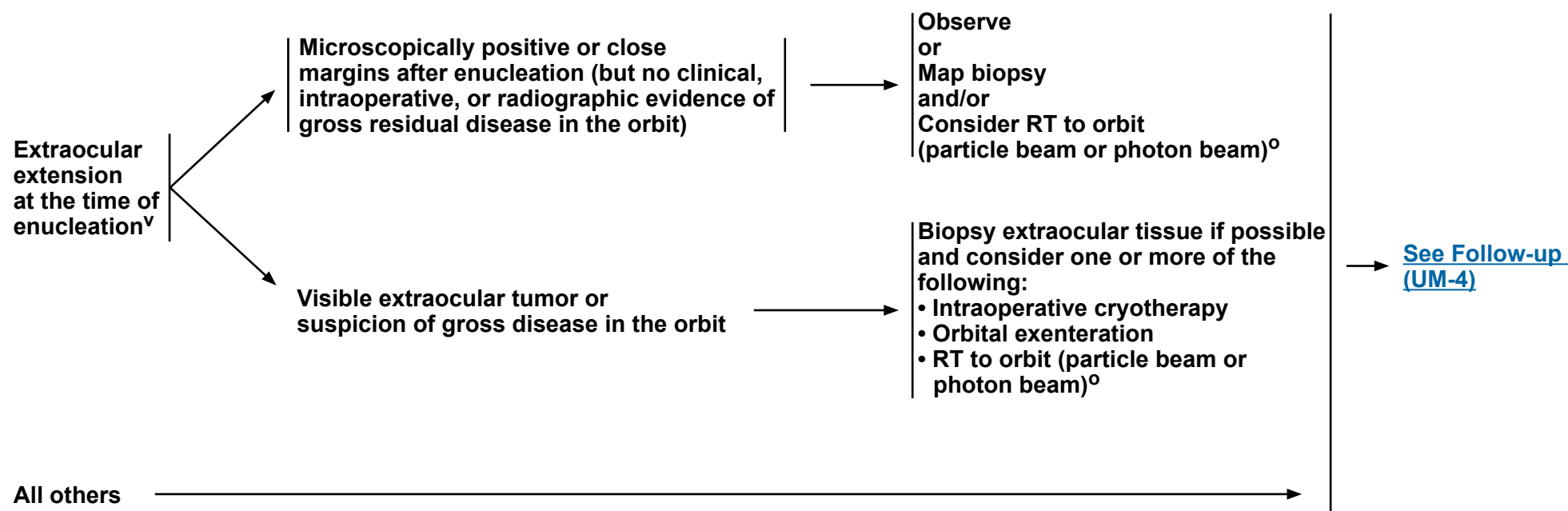
- ^d Biopsy of the primary tumor may provide prognostic information that can help inform frequency of follow-up and may be needed for eligibility for clinical trials. If biopsy is performed, molecular/chromosomal testing for prognostication is preferred over cytology alone. The risks/benefits of biopsy for prognostic analysis should be carefully considered and discussed.
- ^h Unless there is a specific contraindication to the administration of IV contrast (ie, renal impairment or history of a severe allergy), all cross-sectional imaging studies should be performed with and without IV contrast.
- ⁱ Despite lack of treatment options for patients with distant metastatic disease, NCCN favors staging before primary treatment. For small, low-risk tumors, imaging after primary treatment can be considered.
- ^j The most frequent sites of metastasis are liver, lungs, skin/soft tissue, and bones. At minimum, all patients should have contrast-enhanced MR or ultrasound of the liver, with modality preference determined by expertise at the treating institution. Additional imaging modalities may include chest/abdominal/pelvic CT with contrast. However, screening should limit radiation exposure whenever possible.
- ^k The cutoff for largest basal diameter depends on the dimensions of the largest brachytherapy plaque available, so may depend on the type of plaque and isotope selected if brachytherapy is used.
- ^l Patients may be considered for palliative local therapy to the primary tumor in the setting of metastatic disease. Patients who present with advanced metastatic disease and limited life expectancy may elect to have no treatment to their primary tumor.
- ^m An essential feature of high-quality care is that clinical decisions are informed by a variety of case-specific factors (eg, patient characteristics and preferences like age, status of the other eye among others, disease characteristics, medical history), such that for some patients the best clinical approach may be other than one of the listed options.
- ⁿ For small ciliary body and iris tumors (less than 3 clock hours), surgical excision may be considered.
- ^o [See Principles of Radiation Therapy \(UM-B\).](#)
- ^p The plaque should cover the tumor with a ≥ 2 -mm circumferential margin. The exception is for tumors near the optic nerve where it may be impossible to achieve adequate coverage of the margins. The largest commercially available brachytherapy plaque is 23 mm in diameter; thus, plaque brachytherapy is recommended only for tumors with largest basal diameter ≤ 19 mm.
- ^q Brachytherapy with scleral patch graft for cases with limited extraocular extension.
- ^r Consider laser ablation or enucleation for patients who are not good candidates for brachytherapy or particle beam radiation.
- ^s Consider additional treatment with resection, laser ablation, transpupillary thermotherapy, or cryotherapy if concerned that adequate response was not achieved from initial radiation.
- ^t While there is a trend toward avoiding enucleation, it is recommended for patients with neovascular glaucoma, tumor replacing $>50\%$ of globe, or blind, painful eyes. Consider enucleation in cases of extensive extraocular extension.
- ^u Pathologic evaluation should follow the uveal melanoma synoptic report recommendations by the College of American Pathologists. Available at: <https://documents.cap.org/protocols/cp-uveal-melanoma-17protocol-4000.pdf>

Note: All recommendations are category 2A unless otherwise indicated.

Clinical Trials: NCCN believes that the best management of any patient with cancer is in a clinical trial. Participation in clinical trials is especially encouraged.



ADDITIONAL PRIMARY TREATMENT



^o [See Principles of Radiation Therapy \(UM-B\).](#)

^v This is a relatively rare occurrence; data are limited for these recommendations.

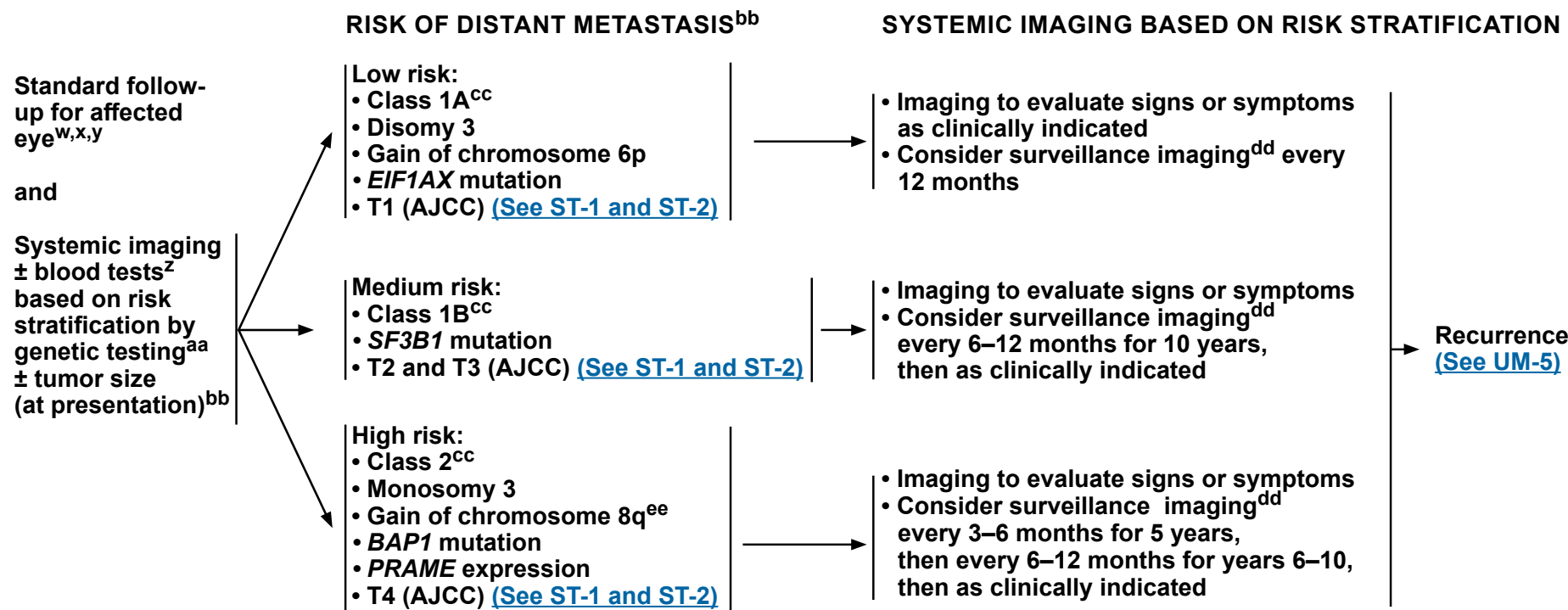
Note: All recommendations are category 2A unless otherwise indicated.

Clinical Trials: NCCN believes that the best management of any patient with cancer is in a clinical trial. Participation in clinical trials is especially encouraged.



NCCN Guidelines Version 2.2021

Melanoma: Uveal



^{bb} Risk stratification to determine the frequency of follow-up should be based on the highest risk factor present.

^w The affected eye should be imaged with color fundus photography and ultrasonography every 3–6 months for 3–5 years, then every 6–12 months thereafter, if stable. The frequency of follow-up should depend on the size and location (eg, juxtapapillary location, ciliary body involvement) of the tumor at presentation. Radiation-related retinopathy and other treatment-related complications may occur at any time following treatment.

^x The contralateral eye is not at increased risk of uveal melanoma, and can be followed with routine ophthalmologic care.

^y Additional risk factors for recurrence: Juxtapapillary location and ciliary body involvement.

^z Liver function tests (LFTs) may be considered as part of follow-up, although some studies showed poor sensitivity for early detection of liver metastases.

^{aa} If biopsy not performed, then follow medium- or high-risk pathways, depending on whether any high-risk features are present.

^{cc} Onken MD, Worley LA, Char DH, et al. Collaborative ocular oncology group report number 1: prospective validation of a multi-gene prognostic assay in uveal melanoma. *Ophthalmology* 2012;119:1596-1603.

^{dd} The most frequent sites of metastasis are liver, lungs, skin/soft tissue, and bones. For patients who elect to have surveillance imaging, options include: contrast-enhanced MR or ultrasound of the liver, with modality preference determined by expertise at the treating institution. Additional imaging modalities may include chest/abdominal/pelvic CT with contrast, or dual energy subtraction chest x-ray. However, screening should limit radiation exposure whenever possible. Scans should be performed with IV contrast unless contraindicated. Recognizing that there are limited options for systemic recurrence, and that regular imaging may cause patient anxiety, patients should discuss with their treating physician the benefits of surveillance imaging, and some patients may elect to forgo surveillance imaging. Participation in a clinical trial is strongly encouraged.

^{ee} 8q gain, especially when numerous copies are found, portends greater risk for metastasis.

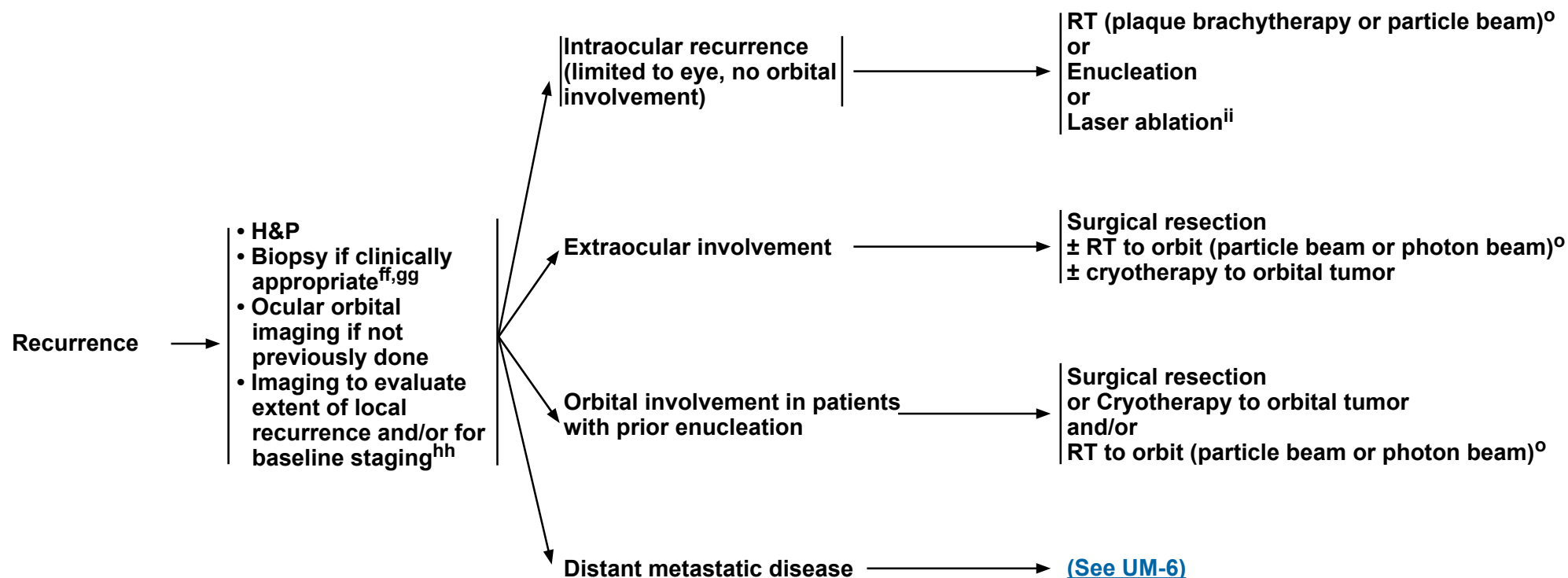
Note: All recommendations are category 2A unless otherwise indicated.

Clinical Trials: NCCN believes that the best management of any patient with cancer is in a clinical trial. Participation in clinical trials is especially encouraged.



WORKUP

TREATMENT FOR RECURRENCE



^o See Principles of Radiation Therapy (UM-B).

^{ff} Extraocular recurrence or metastasis should be confirmed histologically whenever possible or if clinically indicated. Biopsy techniques may include FNA or core. Obtain tissue for genetic analysis (screening for mutations that may be potential targets for treatment or determine eligibility for a clinical trial) from either biopsy of the metastasis (preferred) or archival material if the patient is being considered for targeted therapy. Consider broader genomic profiling if the test results might guide future decisions or eligibility for participation in a clinical trial.

⁹⁹ Intraocular recurrence can often be diagnosed and managed without a biopsy. Additional prognostic FNA biopsy may be valuable.

^{hh} The most frequent sites of metastasis are liver, lungs, skin/soft tissue, and bones. Imaging options include: contrast-enhanced MR or ultrasound of the liver, with modality preference determined by expertise at the treating institution. Additional imaging may include chest/abdominal/pelvic CT with contrast and/or whole-body FDG PET/CT; however, screening should limit radiation exposure whenever possible. Brain MRI with IV contrast may be performed if neurologic symptoms are present, but routine CNS imaging is not recommended. Scans should be performed with IV contrast unless contraindicated.

ⁱⁱ For small recurrences in patients who cannot undergo RT or surgery, transpupillary thermotherapy is recommended.

Note: All recommendations are category 2A unless otherwise indicated.

Clinical Trials: NCCN believes that the best management of any patient with cancer is in a clinical trial. Participation in clinical trials is especially encouraged.

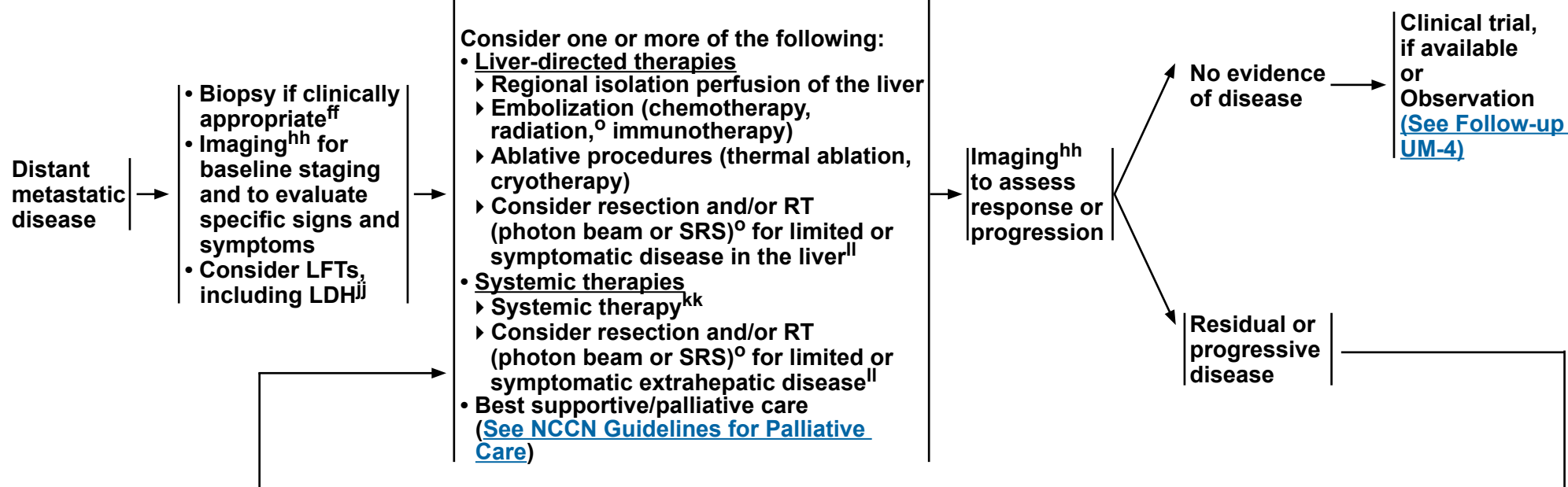


NCCN Guidelines Version 2.2021

Melanoma: Uveal

WORKUP

TREATMENT OF METASTATIC DISEASE



^o See Principles of Radiation Therapy (UM-B).

^{ff} Extraocular recurrence or metastasis should be confirmed histologically whenever possible or if clinically indicated. Biopsy techniques may include FNA or core. Obtain tissue for genetic analysis (screening for mutations that may be potential targets for treatment or determine eligibility for a clinical trial) from either biopsy of the metastasis (preferred) or archival material if the patient is being considered for targeted therapy. Consider broader genomic profiling if the test results might guide future decisions or eligibility for participation in a clinical trial.

^{hh} The most frequent sites of metastasis are liver, lungs, skin/soft tissue, and bones. Imaging options include: contrast-enhanced MR or ultrasound of the liver, with modality preference determined by expertise at the treating institution. Additional imaging may include chest/abdominal/pelvic CT with contrast and/or whole-body FDG PET/CT; however, screening should limit radiation exposure whenever possible. Brain MRI with IV contrast may be performed if neurologic symptoms are present, but routine CNS imaging is not recommended. Scans should be performed with IV contrast unless contraindicated.

^{jj} LDH is a validated prognostic indicator in cutaneous melanoma. However, its role in risk stratification of metastatic uveal melanoma is unknown.

^{kk} In general, there are no systemic therapies that have reliably improved the overall survival in patients with metastatic uveal melanoma; however, individual patients may derive substantial benefit on occasion. If disease is confined to the liver, regionally hepatic-directed therapies such as chemoembolization, radioembolization, or immunoembolization should be considered. See Systemic Therapy for Metastatic or Unresectable Disease (UM-C).

^{ll} See Principles of Radiation for Metastatic Disease (ME-H 3 of 7) in the NCCN Guidelines for Melanoma: Cutaneous.

Note: All recommendations are category 2A unless otherwise indicated.

Clinical Trials: NCCN believes that the best management of any patient with cancer is in a clinical trial. Participation in clinical trials is especially encouraged.



RISK FACTORS FOR DEVELOPMENT OF UVEAL MELANOMA

- Patients with the following risk factors are at increased risk of developing uveal melanoma:
 - ▶ Choroidal nevi^a
 - ▶ Ocular/oculodermal melanocytosis (hyperpigmentation of episclera, uvea, and skin)
 - ▶ Familial uveal melanoma (eg, germline mutations in *BAP1*, *PALB2*, *MBD4*, or NF-1 [neurofibromatosis])¹⁻⁶
 - ▶ Higher numbers of atypical cutaneous nevi, common cutaneous nevi, and/or cutaneous freckles
 - ▶ Light skin color, propensity to sunburn, and/or light eye (iris) color
 - ▶ Strong personal or family history of cancer^b
- The presence of cutaneous melanoma does not increase the risk of uveal melanoma. Among patients with cutaneous melanoma, routine screening for uveal melanoma is not required.

^a Risk factors for growth of small melanocytic tumors: presence of symptoms, tumor thickness >2 mm, tumor diameter >5 mm, presence of subretinal fluid and orange pigment, tumor margin within 3 mm of optic disk, ultrasound hollowness, absence of halo.

^b Evaluate for evidence of hereditary syndrome and refer for genetic counseling and testing if indicated:

- Early age of diagnosis (<30 years of age)
- History of other primary cancers in the patient
- Family or personal history of other cancers known to be associated with a hereditary syndrome:
 - ▶ *BAP1*: RCC, mesothelioma, cutaneous melanoma, cholangiocarcinoma, meningioma
 - ▶ *BRCA*, *PALB2*: breast, ovarian, or pancreatic cancers

Note: All recommendations are category 2A unless otherwise indicated.

Clinical Trials: NCCN believes that the best management of any patient with cancer is in a clinical trial. Participation in clinical trials is especially encouraged.

[References](#)



RISK FACTORS FOR DEVELOPMENT OF UVEAL MELANOMA

REFERENCES

- ¹ Walpole S, Pritchard AL, Cebulla CM, et al. Comprehensive Study of the Clinical Phenotype of Germline BAP1 Variant-Carrying Families Worldwide. J Natl Cancer Inst 2018;110:1328-1341.
- ² Abdel-Rahman MH, Pilarski R, Cebulla CM, et al. Germline BAP1 mutation predisposes to uveal melanoma, lung adenocarcinoma, meningioma, and other cancers. J Med Genet 2011;48:856-859.
- ³ Pilarski R, Carlo M, Cebulla C, Abdel-Rahman M. BAP1 Tumor Predisposition Syndrome. In: Adam MP, Ardinger HH, Pagon RA, et al. eds. GeneReviews. Seattle, WA: University of Washington, Seattle. Copyright © 1993-2020, University of Washington, Seattle. GeneReviews is a registered trademark of the University of Washington, Seattle. All rights reserved; 2020.
- ⁴ Derrien AC, Rodrigues M, Eeckhoutte A, et al. Germline MBD4 mutations and predisposition to uveal melanoma. J Natl Cancer Inst 2021;113:80-87.
- ⁵ Abdel-Rahman MH, Sample KM, Pilarski R, et al. Whole exome sequencing identifies candidate genes associated with hereditary predisposition to uveal melanoma. Ophthalmology 2020;127:668-678.
- ⁶ Abdel-Rahman MH, Pilarski R, Ezzat S, et al. Cancer family history characterization in an unselected cohort of 121 patients with uveal melanoma. Fam Cancer 2010;9:431-438.
- ⁷ Singh N, Singh R, Bowen RC, et al. Uveal Melanoma in BAP1 Tumor Predisposition Syndrome: Estimation of Risk. Am J Ophthalmol 2020;224:172-177.

Note: All recommendations are category 2A unless otherwise indicated.

Clinical Trials: NCCN believes that the best management of any patient with cancer is in a clinical trial. Participation in clinical trials is especially encouraged.

**PRINCIPLES OF RADIATION THERAPY****Plaque Brachytherapy****• Treatment Information**

- ▶ Plaque brachytherapy is a common form of definitive radiotherapy for the primary tumor.¹ A prospective trial found no difference in cause-specific survival among patients with tumors 2.5–10 mm in apical height (2.5–8 mm if peripapillary) and ≤16 mm in maximum basal diameter randomized to plaque brachytherapy or enucleation.²
- ▶ Plaque brachytherapy is appropriate for patients with tumors ≤19 mm^a in largest base diameter, ≤10 mm in thickness.
- ▶ Plaque brachytherapy is appropriate as an upfront therapy after initial diagnosis, or after local recurrence following a prior local therapy.
- ▶ Plaque brachytherapy should be performed by an experienced multidisciplinary team including an ophthalmic oncologist, radiation oncologist, and brachytherapy physicist.³
- ▶ Tumor localization for brachytherapy may be performed using indirect ophthalmoscopy, transillumination, light pipe diathermy, and/or ultrasound (intraoperative and/or preoperative).⁴ MRI or CT may be used for preoperative planning.
- ▶ Round or custom plaques are most commonly used. Custom plaques, such as notched plaques, are commonly used for tumors in specific locations (peripapillary).

• Treatment Dosing Information

- ▶ Using iodine-125 Collaborative Ocular Melanoma Study (COMS) plaques, 85 Gy should be prescribed to the apex of the tumor at low dose rate (≥0.6 Gy/h). Dose adjustments may need to be made for non-COMS plaques.⁵ The plaque margin on the tumor border should be ≥2 mm when feasible (diameter of plaque ≥4 mm larger than largest base diameter of tumor). The exception is for tumors near the optic nerve where it may be impossible to achieve adequate coverage of the margins. The largest commercially available brachytherapy plaque is 23 mm^a in diameter; thus, plaque brachytherapy is recommended only for tumors with largest basal diameter ≤19 mm.
- ▶ Using other radioisotopes (eg, ruthenium-106, palladium-103, strontium-90, cobalt-60, cesium-131), or non-COMS iodine-125 plaques, 60–100 Gy may be prescribed at low dose rate to the tumor apex; alternatively, a minimum dose may be prescribed to the base of the tumor. The plaque margin on the tumor border may vary for other radioisotopes.

Particle Beam Therapy**• Treatment Information**

- ▶ Particle beam therapy is a common form of definitive radiotherapy for the primary tumor.¹ A prospective trial found no difference in cause-specific survival among patients with tumors ≤15 mm in maximum basal diameter and ≤11 mm in apical height randomized to plaque brachytherapy or particle beam therapy.⁶
- ▶ Particle beam therapy is appropriate as upfront therapy after initial diagnosis, after margin-positive enucleation, or for intraocular or orbital recurrence.
- ▶ Particle beam therapy should be performed by an experienced multidisciplinary team including an ophthalmic oncologist, radiation oncologist, and particle beam physicist.⁷
- ▶ Tumor localization for particle beam therapy may be performed using indirect ophthalmoscopy, transillumination, and/or ultrasound (intraoperative and/or preoperative), MRI, and/or CT.

^a The cutoff for largest basal diameter depends on the dimensions of the largest brachytherapy plaque available, so may depend on the type of plaque and isotope selected if brachytherapy is used.

Note: All recommendations are category 2A unless otherwise indicated.

Clinical Trials: NCCN believes that the best management of any patient with cancer is in a clinical trial. Participation in clinical trials is especially encouraged.

[Continued](#)
[References](#)

UM-B
1 OF 3



PRINCIPLES OF RADIATION THERAPY

Particle Beam Therapy (continued)

• Treatment Dosing Information

▶ For intraocular tumors:

- ◊ Using protons, 50–70 cobalt Gray equivalent (CGyE) in 4–5 fractions should be prescribed to encompass the planning target volume surrounding the tumor.⁷⁻⁹
- ◊ Using carbon ions, 60–85 CGyE in 5 fractions should be prescribed to encompass the planning target volume surrounding the tumor.¹⁰
- ◊ Fiducial markers (tantalum clips) are encouraged to permit eye and tumor position verification for image-guided radiotherapy delivery.
- ◊ Volumetric planning in 3 dimensions (with or without CT and/or MRI) is encouraged to maximize radiation delivery to tumor and minimize radiation delivery to organs and tissues at risk of injury from radiation.

Stereotactic Radiosurgery (SRS)

• Treatment Information

- ▶ SRS is the least often used form of definitive radiotherapy for the treatment of primary or recurrent intraocular tumors.^{11,12}
- ▶ Few prospective studies have assessed the efficacy and safety of radiosurgery.^{13,14}
- ▶ Tumor localization, fiducial marker use, and planning for SRS are generally consistent with particle beam therapy approaches.

• Treatment Dosing Information

- ▶ Using fractionated SRS: 45–70 Gy in 2–5 fractions should be prescribed.
- ▶ Using single-fraction SRS: 18–45 Gy in 1 fraction should be prescribed.

Photon Beam Radiotherapy

• Treatment/Dosing Information

- ▶ Photon beam radiotherapy is a preferred option as an adjuvant to surgery for orbital involvement.
 - ◊ Adjuvant radiotherapy can be used in patients at risk for local recurrence (margin-positive enucleation or exenteration) or regional recurrence (resected regional metastases).
 - Adjuvant RT Dosing
 - A dose of 20–30 Gy in 5 fractions should be prescribed to the clinical target volume at risk for recurrence^{15,16} using intensity-modulated techniques with image guidance.
- ▶ Photon beam radiotherapy can be used for treatment of distant metastases at risk for causing symptoms or for palliation of symptomatic distant metastases.
 - RT Dosing for Distant Metastases
 - Doses of 8–30 Gy in 1–10 fractions should be prescribed to the appropriate target volume¹⁷ using appropriate 3-D or intensity-modulated radiation therapy (IMRT) techniques with or without image guidance.

Radioembolization

- Selective internal radiation therapy for patients with liver metastases using yttrium-90 has been reported in retrospective studies and in one prospective study.^{18,19}
- Further study is required to determine the appropriate patients for and risks and benefits of this approach.

Note: All recommendations are category 2A unless otherwise indicated.

Clinical Trials: NCCN believes that the best management of any patient with cancer is in a clinical trial. Participation in clinical trials is especially encouraged.

[References](#)

**PRINCIPLES OF RADIATION THERAPY
REFERENCES**

- ¹ Abrams MJ, Gagne NL, Melhus CS, Mignano JE. Brachytherapy vs. external beam radiotherapy for choroidal melanoma: Survival and patterns-of-care analyses. *Brachytherapy* 2016;15:216-223.
- ² Collaborative Ocular Melanoma Study Group. The COMS randomized trial of iodine 125 brachytherapy for choroidal melanoma: V. Twelve-year mortality rates and prognostic factors: COMS report No. 28. *Arch Ophthalmol* 2006;124:1684-1693.
- ³ American Brachytherapy Society - Ophthalmic Oncology Task Force. The American Brachytherapy Society consensus guidelines for plaque brachytherapy of uveal melanoma and retinoblastoma. *Brachytherapy* 2014;13:1-14.
- ⁴ Almony A, Breit S, Zhao H, et al. Tilting of radioactive plaques after initial accurate placement for treatment of uveal melanoma. *Arch Ophthalmol* 2008;126:65-70.
- ⁵ Rivard MJ, Chiu-Tsao ST, Finger PT, et al. Comparison of dose calculation methods for brachytherapy of intraocular tumors. *Med Phys* 2011;38:306-316.
- ⁶ Mishra KK, Quivey JM, Daftari IK, et al. Long-term results of the UCSF-LBNL randomized trial: Charged particle with helium ion versus iodine-125 plaque therapy for choroidal and ciliary body melanoma. *Int J Radiat Oncol Biol Phys* 2015;92:376-383.
- ⁷ Hrbacek J, Mishra KK, Kacperek A, et al. Practice patterns analysis of ocular proton therapy centers: The International OPTIC Survey. *Int J Radiat Oncol Biol Phys* 2016;95:336-343.
- ⁸ Hartsell WF, Kapur R, Hartsell SO, et al. Feasibility of proton beam therapy for ocular melanoma using a novel 3D treatment planning technique. *Int J Radiat Oncol Biol Phys* 2016;95:353-359.
- ⁹ Gragoudas ES, Lane AM, Regan S, et al. A randomized controlled trial of varying radiation doses in the treatment of choroidal melanoma. *Arch Ophthalmol* 2000;118:773-778.
- ¹⁰ Tsuji H, Ishikawa H, Yanagi T, et al. Carbon-ion radiotherapy for locally advanced or unfavorably located choroidal melanoma: a phase I/II dose-escalation study. *Int J Radiat Oncol Biol Phys* 2007;67:857-862.
- ¹¹ Muller K, Naus N, Nowak PJ, et al. Fractionated stereotactic radiotherapy for uveal melanoma, late clinical results. *Radiother Oncol* 2012;102:219-224.
- ¹² Dunavoelgyi R, Georg D, Zehetmayer M, et al. Dose-response of critical structures in the posterior eye segment to hypofractionated stereotactic photon radiotherapy of choroidal melanoma. *Radiother Oncol* 2013;108:348-353.
- ¹³ Muller K, Nowak PJ, de Pan C, et al. Effectiveness of fractionated stereotactic radiotherapy for uveal melanoma. *Int J Radiat Oncol Biol Phys* 2005;63:116-122.
- ¹⁴ Zehetmayer M, Kitz K, Menapace R, et al. Local tumor control and morbidity after one to three fractions of stereotactic external beam irradiation for uveal melanoma. *Radiother Oncol* 2000;55:135-144.
- ¹⁵ The Collaborative Ocular Melanoma Study (COMS) randomized trial of pre-enucleation radiation of large choroidal melanoma III: local complications and observations following enucleation COMS report no. 11. *Am J Ophthalmol* 1998;126:362-372.
- ¹⁶ Ang KK, Peters LJ, Weber RS, et al. Postoperative radiotherapy for cutaneous melanoma of the head and neck region. *Int J Radiat Oncol Biol Phys* 1994;30:795-798.
- ¹⁷ Huguenin PU, Kieser S, Glanzmann C, et al. Radiotherapy for metastatic carcinomas of the kidney or melanomas: an analysis using palliative end points. *Int J Radiat Oncol Biol Phys* 1998;41:401-405.
- ¹⁸ Jia Z, Jiang G, Zhu C, et al. A systematic review of yttrium-90 radioembolization for unresectable liver metastases of melanoma. *Eur J Radiol* 2017;92:111-115.
- ¹⁹ Gonsalves CF, Eschelmann DJ, Adamo RD, et al. A prospective phase II trial of radioembolization for treatment of uveal melanoma hepatic metastasis. *Radiology* 2019;293:223-231.

Note: All recommendations are category 2A unless otherwise indicated.**Clinical Trials: NCCN believes that the best management of any patient with cancer is in a clinical trial. Participation in clinical trials is especially encouraged.**

**SYSTEMIC THERAPY FOR DISTANT METASTATIC DISEASE^a****Preferred Regimens**

- When available and clinically appropriate, enrollment in a clinical trial is recommended.

Other Recommended Regimens^a

- Consider one or more of the following options:

- ▶ **Immunotherapy^b**

- ◊ Anti PD-1 monotherapy
 - Pembrolizumab
 - Nivolumab
- ◊ Nivolumab/ipilimumab
- ◊ Ipilimumab

- ▶ **Cytotoxic Regimens**

- ◊ Dacarbazine
- ◊ Temozolomide
- ◊ Paclitaxel
- ◊ Albumin-bound paclitaxel
- ◊ Carboplatin/paclitaxel

- ▶ **Targeted Therapy^{c,d}**

- ◊ Trametinib

^a The literature is not directive regarding the specific systemic agent(s) offering superior outcomes, but does provide evidence that uveal melanoma is sensitive to some of the same systemic therapies used to treat cutaneous melanoma. Although there are no systemic therapies that have reliably improved the overall survival in patients with metastatic uveal melanoma, individual patients may derive benefit on occasion. Given the lack of positive phase III studies, clinical trials are preferred.

^b See [NCCN Guidelines for Management of Immunotherapy-Related Toxicities](#).

^c See [Management of Toxicities Associated with Targeted Therapy from the NCCN Guidelines for Melanoma: Cutaneous \(ME-K\)](#).

^d The listed systemic therapy options do not cover *BRAF* or *KIT* mutated tumors. In general, uveal melanomas rarely have *BRAF* or *KIT* mutations.

Note: All recommendations are category 2A unless otherwise indicated.

Clinical Trials: NCCN believes that the best management of any patient with cancer is in a clinical trial. Participation in clinical trials is especially encouraged.

References



SYSTEMIC THERAPY FOR METASTATIC OR UNRESECTABLE DISEASE

REFERENCES

Immunotherapy

Pembrolizumab and Nivolumab

- Kottschade LA, McWilliams RR, Markovic SN, et al. The use of pembrolizumab for the treatment of metastatic uveal melanoma. *Melanoma Res* 2016;26:300-303.
- Algazi AP, Tsai KK, Shoushtari AN, et al. Clinical outcomes in metastatic uveal melanoma treated with PD-1 and PD-L1 antibodies. *Cancer* 2016;122:3344-3353.

Nivolumab/ipilimumab

- Piulats JM, Espinosa E, de la Cruz Merino L, et al. Nivolumab Plus Ipilimumab for Treatment-Naive Metastatic Uveal Melanoma: An Open-Label, Multicenter, Phase II Trial by the Spanish Multidisciplinary Melanoma Group (GEM-1402). *J Clin Oncol* 2021;39:586-598.
- Pelster MS, Gruschus SK, Bassett R, et al. Nivolumab and Ipilimumab in Metastatic Uveal Melanoma: Results From a Single-Arm Phase II Study. *J Clin Oncol* 2021;39:599-607.

Ipilimumab

- Zimmer L, Vaubel J, Mohr P, et al. Phase II DeCOG-study of ipilimumab in pretreated and treatment-naive patients with metastatic uveal melanoma. *PLoS One* 2015;10:e0118564.
- Danielli R, Ridolfi R, Chiarion-Sileni V, et al. Ipilimumab in pretreated patients with metastatic uveal melanoma: safety and clinical efficacy. *Cancer Immunol Immunother* 2012;61:41-48.
- Luke JJ, Callahan MK, Postow MA, et al. Clinical activity of ipilimumab for metastatic uveal melanoma: a retrospective review of the Dana-Farber Cancer Institute, Massachusetts General Hospital, Memorial Sloan-Kettering Cancer Center, and University Hospital of Lausanne experience. *Cancer* 2013;119:3687-3695.

Note: All recommendations are category 2A unless otherwise indicated.

Clinical Trials: NCCN believes that the best management of any patient with cancer is in a clinical trial. Participation in clinical trials is especially encouraged.

[Continued](#)

UM-C
2 OF 3



SYSTEMIC THERAPY FOR METASTATIC OR UNRESECTABLE DISEASE

REFERENCES

Cytotoxic Regimens

Dacarbazine

- Serrone L, Zeuli M, Sega FM, et al. Dacarbazine-based chemotherapy for metastatic melanoma: thirty-year experience overview. J Exp Clin Cancer Res 2000;19:21-34.

Temozolomide

- Bedikian AY, Papadopoulos N, Plager C, et al. Phase II evaluation of temozolomide in metastatic choroidal melanoma. Melanoma Res 2003;13:303-306.

Paclitaxel

- Wiernik PH and Einzig AI. Taxol in malignant melanoma. J Natl Cancer Inst Monogr 1993;15:185-187.

Albumin-bound paclitaxel

- Hersh EM, O'Day SJ, Ribas A, et al. A phase 2 clinical trial of nab-paclitaxel in previously treated and chemotherapy-naïve patients with metastatic melanoma. Cancer 2010;116:155-163.
- Kottschade LA, Suman VJ, Amatruda T, et al. A phase II trial of nab-paclitaxel (ABI-007) and carboplatin in patients with unresectable stage iv melanoma: a north central cancer treatment group study, N057E(1). Cancer 2011;117:1704-1710.

Paclitaxel/carboplatin

- Rao RD, Holtan SG, Ingle JN, et al. Combination of paclitaxel and carboplatin as second-line therapy for patients with metastatic melanoma. Cancer 2006;106:375-382.
- Homsí J, Bedikian AY, Papadopoulos NE, et al. Phase 2 open-label study of weekly docosahexaenoic acid-paclitaxel in patients with metastatic uveal melanoma. Melanoma Res 2010;20:507-510.

Targeted Therapy

Trametinib

- Falchook GS, Lewis KD, Infante JR, et al. Activity of the oral MEK inhibitor trametinib in patients with advanced melanoma: a phase 1 dose-escalation trial. Lancet Oncol 2012;13:782-789.
- Shoushtari AN, Kudchadkar RR, Panageas K, et al. A randomized phase 2 study of trametinib with or without GSK2141795 in patients with advanced uveal melanoma. J Clin Oncol 2016;34:9511-9511.

Note: All recommendations are category 2A unless otherwise indicated.

Clinical Trials: NCCN believes that the best management of any patient with cancer is in a clinical trial. Participation in clinical trials is especially encouraged.

**American Joint Committee on Cancer (AJCC)**
Definitions of TNM for Choroidal and Ciliary Melanoma (8th ed., 2017)**Table 1. Definitions for T, N, M**
Choroidal and Ciliary Body Melanomas

T	Primary Tumor
TX	Primary tumor cannot be assessed
T0	No evidence of primary tumor
T1	Tumor size category 1
T1a	Tumor size category 1 without ciliary body involvement and extraocular extension
T1b	Tumor size category 1 with ciliary body involvement
T1c	Tumor size category 1 without ciliary body involvement but with extraocular extension ≤5 mm in largest diameter
T1d	Tumor size category 1 with ciliary body involvement and extraocular extension ≤5 mm in largest diameter
T2	Tumor size category 2
T2a	Tumor size category 2 without ciliary body involvement and extraocular extension
T2b	Tumor size category 2 with ciliary body involvement
T2c	Tumor size category 2 without ciliary body involvement but with extraocular extension ≤5 mm in largest diameter
T2d	Tumor size category 2 with ciliary body involvement and extraocular extension ≤5 mm in largest diameter
T3	Tumor size category 3
T3a	Tumor size category 3 without ciliary body involvement and extraocular extension
T3b	Tumor size category 3 with ciliary body involvement
T3c	Tumor size category 3 without ciliary body involvement but with extraocular extension ≤5 mm in largest diameter
T3d	Tumor size category 3 with ciliary body involvement and extraocular extension ≤5 mm in largest diameter
T4	Tumor size category 4
T4a	Tumor size category 4 without ciliary body involvement and extraocular extension
T4b	Tumor size category 4 with ciliary body involvement
T4c	Tumor size category 4 without ciliary body involvement but with extraocular extension ≤5 mm in largest diameter
T4d	Tumor size category 4 with ciliary body involvement and extraocular extension ≤5 mm in largest diameter
T4e	Any tumor size category with extraocular extension >5 mm in largest diameter

Notes

1. Primary ciliary body and choroidal melanomas are classified according to the four tumor size categories defined in Figure 1. ([See ST-3](#))
2. In clinical practice, the largest tumor basal diameter may be estimated in optic disc diameters (DD; average: 1 DD = 1.5 mm), and tumor thickness may be estimated in diopters (average: 2.5 diopters = 1 mm). Ultrasonography and fundus photography are used to provide more accurate measurements.
3. When histopathologic measurements are recorded after fixation, tumor diameter and thickness may be underestimated because of tissue shrinkage.

Used with permission of the American College of Surgeons, Chicago, Illinois. The original source for this information is the AJCC Cancer Staging Manual, Eighth Edition (2017) published by Springer International Publishing.



American Joint Committee on Cancer (AJCC)
Definitions of TNM for Choroidal and Ciliary Melanoma (8th ed., 2017)

Table 1. Definitions for T, N, M (continued)

N Regional Lymph Nodes

NX	Regional lymph nodes cannot be assessed
N0	No regional lymph node involvement
N1	Regional lymph node metastases or discrete tumor deposits in the orbit
N1a	Metastasis in one or more regional lymph node(s)
N1b	No regional lymph nodes are positive, but there are discrete tumor deposits in the orbit that are not contiguous to the eye (choroidal and ciliary body).

M Distant Metastasis

M0	No distant metastasis by clinical classification
M1	Distant metastasis
M1a	Largest diameter of the largest metastasis ≤3.0 cm
M1b	Largest diameter of the largest metastasis 3.1–8.0 cm
M1c	Largest diameter of the largest metastasis ≥8.1 cm

G Histologic Grade

GX	Grade cannot be assessed
G1	Spindle cell melanoma (>90% spindle cells)
G2	Mixed cell melanoma (>10% epithelioid cells and <90% spindle cells)
G3	Epithelioid cell melanoma (>90% epithelioid cells)

Note: Because of the lack of universal agreement regarding which proportion of epithelioid cells classifies a tumor as mixed or epithelioid, some ophthalmic pathologists currently combine grades 2 and 3 (non-spindle, ie, epithelioid cells detected) and contrast them with grade 1 (spindle, ie, no epithelioid cells detected).

Table 2. AJCC Prognostic Stage Groups

	T	N	M
Stage I	T1a	N0	M0
Stage IIA	T1b-d	N0	M0
	T2a	N0	M0
Stage IIB	T2b	N0	M0
	T3a	N0	M0
Stage IIIA	T2c-d	N0	M0
	T3b-c	N0	M0
	T4a	N0	M0
Stage IIIB	T3d	N0	M0
	T4b-c	N0	M0
Stage IIIC	T4d-e	N0	M0
Stage IV	Any T	N1	M0
	Any T	Any N	M1a-c

Used with permission of the American College of Surgeons, Chicago, Illinois. The original source for this information is the AJCC Cancer Staging Manual, Eighth Edition (2017) published by Springer International Publishing.



Figure 1: Classification of Ciliary Body and Choroid Uveal Melanoma Based on Thickness and Diameter

Thickness (mm)								
		Largest basal diameter (mm)						
		≤3.0	3.1–6.0	6.1–9.0	9.1–12.0	12.1–15.0	15.1–18.0	>18.0
>15.0						4	4	4
12.1–15.0					3	3	4	4
9.1–12.0			3	3	3	3	3	4
6.1–9.0		2	2	2	2	3	3	4
3.1–6.0		1	1	1	2	2	3	4
≤3.0		1	1	1	1	2	2	4

Used with permission of the American College of Surgeons, Chicago, Illinois. The original source for this information is the AJCC Cancer Staging Manual, Eighth Edition (2017) published by Springer International Publishing.



NCCN Categories of Evidence and Consensus

Category 1	Based upon high-level evidence, there is uniform NCCN consensus that the intervention is appropriate.
Category 2A	Based upon lower-level evidence, there is uniform NCCN consensus that the intervention is appropriate.
Category 2B	Based upon lower-level evidence, there is NCCN consensus that the intervention is appropriate.
Category 3	Based upon any level of evidence, there is major NCCN disagreement that the intervention is appropriate.

All recommendations are category 2A unless otherwise indicated.

NCCN Categories of Preference

Preferred intervention	Interventions that are based on superior efficacy, safety, and evidence; and, when appropriate, affordability.
Other recommended intervention	Other interventions that may be somewhat less efficacious, more toxic, or based on less mature data; or significantly less affordable for similar outcomes.
Useful in certain circumstances	Other interventions that may be used for selected patient populations (defined with recommendation).

All recommendations are considered appropriate.



NCCN Guidelines Version 2.2021

Melanoma: Uveal

Discussion

This discussion corresponds to the NCCN Guidelines for Melanoma: Uveal. Last updated: June 25th, 2021.

Table of Contents

Overview	MS-2	Patterns of Metastases	MS-32
Staging	MS-2	Risk Factors for Metastasis	MS-32
Molecular Characteristics	MS-2	Surveillance Methods for Distant Metastatic Disease	MS-34
Risk Factors for Uveal Melanoma	MS-3	Risk of Developing Secondary Cancers During Follow-up	MS-35
Literature Search Criteria and Guidelines Update Methodology	MS-5	Follow-up for Distant Metastasis	MS-35
Diagnosis and Workup	MS-5	Management of Recurrence	MS-36
Characteristics, Detection, and Differential Diagnosis	MS-5	Workup for Recurrence	MS-36
Initial Workup of Suspicious Pigmented Uveal Lesion	MS-7	Treatment for Local Recurrence	MS-37
Observation for Uncertain Diagnosis in Patients with Low Risk	MS-14	Treatment for Metastatic Disease	MS-37
Further Workup Prior to Treatment	MS-15	References	MS-52
Treatment of Localized Primary Uveal Melanoma	MS-15		
Surgical Options	MS-16		
Radiation Therapy	MS-17		
Other Ablative Techniques	MS-22		
Treatment for Extraocular/Extrascleral Extension	MS-23		
Treatment of Localized Uveal Melanoma	MS-24		
Treatment of Primary Tumor in Patients with Metastatic Disease	MS-25		
Follow-up	MS-25		
Patterns of Local Recurrence	MS-25		
Patterns of Treatment Complications	MS-27		
Surveillance Methods for Local Recurrence or Complications	MS-30		
Follow-up for the Treated Eye	MS-31		
Risk in Contralateral (Fellow) Eye	MS-31		



NCCN Guidelines Version 2.2021

Melanoma: Uveal

Overview

Uveal melanoma is the most common type of primary intraocular malignancy in adults, with new cases occurring in 5 to 10 people per million per year.¹⁻⁷ Uveal melanomas can arise anywhere in the uveal tract, with less than 75% arising in the choroid, and the remainder arising in the iris or ciliary body.^{1,3,6,8,9}

The distribution of uveal melanoma by sex, race, and geography differs from that of cutaneous melanoma.^{1,3,10} Most uveal melanomas are localized at first presentation, and only a small percentage of cases present with metastases (<3%).^{6,10-14} Risk of metastasis varies by stage at presentation, with 5-year risk of metastasis ranging from 3% to 5% for stage I to 44% or greater for stage III.^{8,13} Large population-based analyses have reported disease-specific survival (for uveal melanoma) between 70% to 81% at 5 years,^{2,5,6,10,15-17} and this rate has remained stable over time.⁵ Disease-specific survival varies by the extent of disease at presentation.^{12,13,15,18} For those with early-stage uveal melanoma (stage I–II), 5-year melanoma-specific survival is 85% or better.^{13,15,18} For those with distant metastatic disease, most studies report estimated 5-year survival of less than 20%,^{13,15,19-22} which has not improved over the past few decades.²³

These NCCN Guidelines include recommendations for management of melanomas arising in the choroid or ciliary body. Recommendations for iris melanomas are not included in these guidelines, because iris melanomas are rare (3%–5% of uveal melanomas),^{3,8,9,24,25} have a low rate of systemic metastasis (~5% at 5 years compared with 15%–20% for ciliary body or choroidal melanomas),²⁶ 8,27-30 have a better prognosis than other types of uveal melanoma,^{25,30} have a different AJCC staging system,³¹ and have a different molecular signature.³²⁻³⁶ Treatments for iris melanoma may differ from other types of uveal melanoma due to these factors, as well as anatomic considerations, ease of resection,³⁷⁻⁴⁰ and the negative effects of

radiation to the iris.⁴¹⁻⁴⁶ Moreover, patients with iris melanomas were excluded from many of the large randomized trials that inform treatment recommendations for uveal melanomas.^{14,47,48}

Staging

The patterns of presentation and prognosis for uveal melanoma are completely different from cutaneous melanoma, and the AJCC Staging Manual, 8th Edition, includes separate staging systems for cutaneous, uveal, and conjunctival melanoma.³¹ The staging system for uveal melanoma is further subdivided into separate T-staging for iris versus choroidal or ciliary body melanoma.³¹ Each of these staging systems is empirically based on survival data from large epidemiologic studies, albeit with more data independently validating the staging system for melanoma of the choroid and ciliary body^{12,13,18} compared with the iris²⁹ or conjunctiva.^{49,50}

Molecular Characteristics

Cutaneous, uveal, and conjunctival melanomas also have different molecular signatures.^{34,51-61} Whereas *BRAF*, *NRAS*, *KIT*, and *TERT* promoter mutations are extremely rare in uveal melanoma,^{34,51-54,60,62,63} they are more common in conjunctival and cutaneous melanomas.⁵⁵⁻⁶¹ Most notably, *BRAF* mutations occur in 20% to 50% of conjunctival melanomas, suggesting that conjunctival melanoma may be more similar to cutaneous melanoma than to uveal melanoma.^{55-58,60} Molecular markers common in uveal melanomas (and may have prognostic significance) are not often found in conjunctival or cutaneous melanoma. These include chromosomal abnormalities (particularly chromosomes 3 and 8),^{12,64-68} and mutations in *GNAQ* or *GNA11* (>80% of uveal cases),^{34,51,66,69,70} *BAP1*,^{71,72} *SF3B1*, and *EIFAX*.^{36,73,74}



NCCN Guidelines Version 2.2021

Melanoma: Uveal

Risk Factors for Uveal Melanoma

Studies of large populations of patients with and without uveal melanoma have identified a number of risk factors for the development of uveal melanoma.

Choroidal Nevi

Large population-based studies have found that choroidal nevi occur in 1.9% to 6.5% of the population, depending on the population studied.⁷⁵⁻⁷⁷ Choroidal nevi are more common in whites (4.6%–7.9% in the United States) than in Hispanics or blacks.⁷⁵ Due to differences in prevalence across races, it is not surprising that the reported rate also depends on geography. Several large studies have shown that there is no association between choroidal nevi and cutaneous melanoma.⁷⁵ Choroidal nevi can transform into choroidal melanoma,^{78,79} and one study reported that of uveal melanomas diagnosed, 8% arose from a previously documented nevus.⁷⁸ Others have argued that the fraction of uveal melanomas that arise from nevi may in fact be much higher, as many patients diagnosed with uveal melanoma have not had an ophthalmologic exam for many years.⁸⁰

The rate of transformation from nevi to uveal melanoma is an issue of much debate. Large population studies comparing the prevalence of choroidal melanoma with the prevalence of choroidal nevi have estimated the annual rate of malignant transformation of a choroidal nevus to range from 1/4300 to 1/8845.^{76,81,82} Many studies have aimed to more directly determine the rate at which choroidal nevi transform into uveal melanoma by evaluating changes in presumed nevi or indeterminate melanocytic lesions over time.⁸³⁻⁸⁷ Choroidal nevi can be difficult to distinguish from choroidal melanoma, however, and there is much debate about how to distinguish choroidal nevi from melanoma, as there is evidence from multiple studies that many small lesions presumed to be nevi based on size may actually be melanoma (See *Diagnosis and Workup* section).^{88,89}

Because the criteria for diagnosis of choroidal melanoma differed across studies, and diagnosis was rarely confirmed by histology, there is concern that in many studies some fraction of the population diagnosed with uveal melanoma was in fact misdiagnosed. Given the debate about differential diagnosis, the actual rate of transformation is unclear. Due to uncertainty regarding uveal melanoma diagnosis, other analyses have looked at the likelihood of lesion growth in patients with untreated melanocytic choroidal lesions.^{90,83,84,91-97} Growth has been correlated with risk of metastasis,⁹¹ even though some growing choroidal nevi do not undergo malignant transformation.^{98,99} These studies have found that 13% to 36% of lesions grew by 5 years.^{83,90,94,95} The wide variability in rates across studies is likely due to differences in the population selected for study and the retrospective nature of data collection in some of these studies. More importantly, these studies have also identified factors predictive of growth (Table 1). Several analyses used tumor thickness greater than 2 mm, tumor diameter greater than 5 mm, and tumor margin within 3 mm of the optic disc as cutoffs for these risk factors.^{94,96} Some of these characteristics have also been associated with increased risk of tumor metastasis: proximity to optic disc, documented growth, and tumor thickness.⁹¹

It is important to note that for patients with small lesions presumed to be nevi or indeterminate, who are observed and treated upon evidence of transformation (eg, growth, development of orange pigment, subretinal fluid, other symptoms), the risk of metastasis is low.^{91,95} The risk of death from ocular melanoma in this situation is also low (1/2341 patients per year),⁸⁴ but these risks increase with increasing baseline tumor size.⁸⁴

Patient characteristics that increase the likelihood of choroidal nevi growth include Birt-Hogg-Dubé syndrome, myotonic dystrophy, and immunocompromise. Cases of patients with uveal melanoma and myotonic dystrophy have been reported,^{100,101} and a retrospective study



NCCN Guidelines Version 2.2021

Melanoma: Uveal

found an increased risk of choroidal melanoma in patients with myotonic dystrophy (relative to the general population).¹⁰² Cases of choroidal melanoma have been reported in patients with Birt-Hogg-Dubé syndrome.^{103,104} Cases of ocular melanoma have been reported in immunocompromised patients.^{105,106}

Ocular/Oculodermal Melanocytosis

The rate of ocular/oculodermal melanocytosis, which causes hyperpigmentation of the episclera, uvea, and skin, is much higher in patients with uveal melanoma than in the general population.¹⁰⁷⁻¹¹²

Familial Uveal Melanoma

Although only a small percentage of patients with uveal melanoma have at least one family member with uveal melanoma,^{113,114} this rate is higher than would be expected by coincidence, given the very low incidence of uveal melanoma in the population as a whole.^{115,116} Having a family member with uveal melanoma is therefore considered a risk factor for melanoma. Studies of families with more than one member with uveal melanoma have shown that there are several family cancer syndromes associated with increased risk of uveal melanoma.

BAP1 Tumor Predisposition Syndrome

Certain *BAP1* germline mutations have been associated with predisposition for uveal melanoma, malignant mesothelioma, cutaneous melanoma, and renal cell carcinoma.^{72,116-126} Some families with *BAP1* tumor predisposition syndrome also tend to have atypical Spitz tumors, which are benign/precursor melanocytic lesions that have distinctive clinical and pathologic features.^{116,120,123,127-129} In individuals with germline *BAP1* mutations associated with this syndrome, the risk of uveal melanoma is high (up to ~30%),^{123,129,130} uveal melanoma tends to develop at a younger age,^{122,129} primary lesions tend to be larger and involve the ciliary body,⁷² and the disease has a more aggressive course.^{72,131} Some

individuals with this syndrome develop more than one type of primary cancer,^{129,130,132} and there is a high likelihood of *BAP1*-associated cancers in first- or second-degree relatives.^{116,129}

PALB2

Mutations in *PALB2* have been associated with increased risk for developing breast, ovarian, and pancreatic cancer. Pathogenic variants leading to biallelic inactivation of *PALB2* were identified in tumors of two patients with familial uveal melanoma.¹³³ This finding from a retrospective case series might warrant further investigation into *PALB2* as a uveal melanoma susceptibility gene.

MBD4

MBD4 deleterious mutations have been identified in uveal melanoma tumors at increased incidence compared with the general population and associated with high tumor mutation burden.^{134,135} Questions remain whether *MBD4* germline variants or somatic loss predisposes individuals to uveal melanoma.¹³⁶ How *MBD4* inactivation might affect immunotherapy response is also worth further investigation.^{134,137}

Neurofibromatosis Type 1 (NF-1)

Neurofibromatosis type 1 (NF-1): Based on case reports of uveal melanomas developing in patients with neurofibromatosis,¹³⁸⁻¹⁴⁵ this condition is thought to be a risk factor for uveal melanoma, although population statistics supporting this claim are lacking.¹⁴⁶

Other Potential Risk Factors

Other risk factors include atypical cutaneous nevi, common cutaneous nevi, iris nevi, and cutaneous freckles. These associations are based on moderate-quality evidence from several studies, including meta-analyses, a systematic review, a case study of familial uveal and cutaneous melanoma, and case-controlled studies.¹⁴⁷⁻¹⁵¹ Patient characteristics



associated with increased uveal melanoma risk are fair skin color, light eye color, and propensity to sunburn.^{147,152}

In conclusion, the NCCN Panel recommends evaluation for evidence of hereditary syndrome and referral for genetic counseling and testing in case of: early age of diagnosis (<30 years of age), history of other primary cancers in the patient, or family or personal history of other cancers known to be associated with a hereditary syndrome (eg, *BAP1* – renal cell carcinoma, mesothelioma, cutaneous melanoma, cholangiocarcinoma, meningioma; *BRCA*, *PALB2* – breast, ovarian, and pancreatic cancer).

The Relationship Between Uveal and Cutaneous Melanoma

Clinic-based studies (n < 250) evaluating the likelihood of finding concurrent cutaneous melanoma in patients with ocular melanoma suggest a relationship between these two cancers.^{151,153-155} Most large population-based studies reveal no relationship between preexisting cutaneous melanoma and the subsequent development of uveal melanoma.¹⁵⁶⁻¹⁶⁰ However, one SEER-based study revealed a potential relationship between these two cancers.¹⁶¹ Currently the NCCN Panel does not consider cutaneous melanoma to be a risk factor for uveal melanoma, and patients with cutaneous melanoma do not need more frequent ocular screening than the general population.

For patients who present with uveal melanoma as their first primary cancer, some population-based studies have shown increased risk of subsequent cutaneous melanoma,^{157-159,162} and others have not found the risk to be significantly higher than in the general population.¹⁶³ One analysis based on Swedish Cancer Registry data and re-analysis of archival tissue found that some tumors originally recorded as primary cutaneous melanomas were in fact uveal melanoma metastasis.¹⁶⁰ After correcting the classification, the standardized incidence ratio (SIR) for primary cutaneous melanoma in patients with prior uveal melanoma was no longer significant.¹⁶⁰

Literature Search Criteria and Guidelines Update Methodology

For each update to the NCCN Guidelines for Melanoma: Uveal, an electronic search of the PubMed database was performed to obtain key literature. The search results were narrowed by selecting studies in adult patients published in English. Articles were also excluded if they: 1) involved investigational agents that have not yet received FDA approval; 2) did not pertain to the disease site; 3) were clinical trial protocols; or 4) were reviews that were not systematic reviews. The search results were further narrowed by selecting publications reporting clinical data, meta-analyses and systematic reviews of clinical studies, and treatment guidelines developed by other organizations. The potential relevance of the PubMed search results was examined by the oncology scientist and panel chair, and a list of selected articles was sent to the panel for their review and discussion at the panel meeting. The panel also reviewed and discussed published materials referenced in institutional review comments or provided with submission requests. The Discussion section was developed based on review of data from peer-reviewed publications as well as articles from additional sources deemed as relevant to these guidelines and/or discussed by the panel (eg, e-publications ahead of print, meeting abstracts). Any recommendations for which high-level evidence is lacking are based on the panel's review of lower-level evidence and expert opinion.

The complete details of the development and update of the NCCN Guidelines are available at www.NCCN.org.

Diagnosis and Workup

Characteristics, Detection, and Differential Diagnosis

The majority of uveal melanomas are symptomatic at presentation,^{9,78,164,165} but studies have reported 13% to 30% of patients were asymptomatic at diagnosis (and are discovered by routine eye



NCCN Guidelines Version 2.2021

Melanoma: Uveal

exam).^{9,78,165,166} The most common symptom is blurred vision (38%–49%); other common symptoms include visual field defect/loss, photopsia, irritation and pain, metamorphopsia, floaters, redness, pressure, and change in appearance.^{9,78,165} Although in patients where a lesion was detected, current imaging techniques provide very high accuracy of diagnosis of medium to large uveal melanomas,^{167,168} real-world studies have reported relatively high rates of delay in diagnosis and treatment (23%–37%) due to failure to detect these lesions in the initial ophthalmologic exam.^{9,78,165,169} Another surprising result was the high rate at which uveal melanomas were initially missed in symptomatic patients.^{9,78} These studies underscore the importance of full dilation of the pupil and meticulous examination of the fundus in any patient presenting with symptoms.⁸⁰

Ciliary body melanoma can be difficult to detect,⁹ as it is often hidden behind the iris,¹⁷⁰ and symptoms often do not develop until the tumor is large.^{9,41,46,170} Ciliary body melanoma can cause lens tilting or displacement,^{46,170} cataract development,^{46,170,171} and elevated intraocular pressure,⁴⁶ and is often associated with dilated episcleral “sentinel” vessels,¹⁷⁰ but only rarely has extrascleral extension.¹⁷⁰ Ciliary body melanomas usually present with a dome shape,^{46,170} but occasionally have a circumferential ring shape.^{170,172}

Uveal melanoma typically presents as a pigmented lesion. One study of 8033 eyes with uveal melanoma found that the lesion was pigmented in 55%, nonpigmented in 15%, and 30% had a mixture of pigmented and nonpigmented areas.¹⁷³ Some smaller studies report that a higher percentage of patients have lesions with pigmentation,¹⁶⁶ likely due to varying clinical diagnostic practices resulting in lower detection of nonpigmented lesions. Uveal melanoma most often presents as a dome-shaped tumor (75%), but approximately 20% present with a mushroom shape due to the rupture of Bruch’s membrane and growth into the sub-

retinal space.¹⁷³ A small number of cases present as a diffuse, flat, plateau-shaped tumor (6%) or have a multinodular tapioca appearance (<1%).¹⁷³ Subretinal fluid is present in the majority of cases (75%).¹⁷³ Uveal melanoma tumors are associated with intraocular hemorrhage in ~10% of cases, and extraocular extension is apparent at presentation in 3% of patients.¹⁷³

As described above (see section entitled *Risk Factors for Uveal Melanoma*), several risk factors have been identified that may increase the risk of uveal melanoma. Included among these are rare diseases and family cancer syndromes. When a pigmented lesion on the ciliary body or choroid is discovered, these factors should be evaluated, as they may inform the index of suspicion.

Studies of lesions that were thought to be uveal melanoma but later were assigned an alternate diagnosis showed that the most common simulating lesion is choroidal nevus.¹⁷⁴⁻¹⁷⁷ These studies have reported a variety of other conditions mistaken for uveal melanoma, including congenital hypertrophy of the retinal pigment epithelium (RPE), and choroidal hemangioma, peripheral exudative hemorrhagic chorioretinopathy, hemorrhagic detachment of the retina or pigment epithelium, and age-related macular degeneration.¹⁷⁴⁻¹⁷⁷ There is a considerable overlap in size between small uveal melanomas and large uveal nevi, and there is evidence from several studies that many small lesions presumed to be nevi based on size may actually be melanoma.^{88,89} Although likely but not explored, there is the possibility that some of the treated lesions were nevi and not melanoma. Therefore, size and appearance based on clinical exam may not be sufficient for diagnosis.

It is also important to rule out metastasis to the uvea from other cancers—either known cancers based on patient history or occult primary cancer. Among patients with metastases to the eye or orbit, the most common primary cancer diagnosis is breast cancer, followed by lung cancer, which



NCCN Guidelines Version 2.2021

Melanoma: Uveal

together account for over half of the cases.¹⁷⁸⁻¹⁸⁰ The remainder of uveal metastases arise from a variety of cancers, each cancer type accounting for less than 5% of the population, including cancers of the kidney, gastrointestinal (GI) tract, skin, prostate, thyroid, pancreas, and others.^{179,180}

Initial Workup of Suspicious Pigmented Uveal Lesion

Upon discovery of a suspicious pigmented lesion in the ciliary body or choroid, clinical evaluation should be performed to determine whether the lesion is uveal melanoma, and if so, the extent of disease and other characteristics that should inform management. Clinical evaluation should include a complete history and physical, including personal or family history of prior or current cancers (outside the eye), as this may help determine whether the lesion is primary uveal cancer or a metastasis from another primary cancer. A wide variety of imaging and clinical exam techniques have been tested for their utility in diagnosis and characterization of uveal melanoma. In most cases, the diagnosis of uveal melanoma and characterization for treatment planning (or follow-up) can be achieved based on comprehensive exam of the front and back of the eye including biomicroscopy and dilated fundus exam (indirect ophthalmoscopy), along with color fundus photography, and conventional ocular ultrasound (US).^{45,46,80,181} In some cases, additional imaging may be needed to confirm diagnosis or better characterize the tumor for treatment planning (or monitoring). Additional imaging options that may be useful include autofluorescence of the ocular fundus, optical coherence tomography (OCT), retinal fluorescein angiography of the ocular fundus, transillumination, and MRI.

Features that are essential to measure and document as part of workup include visual acuity (VA), location and size of the tumor (ie, diameter, thickness), distance from the tumor to the disc and to the fovea, ciliary body involvement, and subretinal fluid and orange pigment, if present. The

reason for recording each of these features and the utility of different techniques for diagnosis and assessment of these features is described below.

Features to Record

Visual Acuity

It is important to measure VA during workup, as many uveal melanomas (as well as simulating lesions) can disturb vision, and changes in VA can be an indication of progression, response to treatment, or a side effect of certain treatments. VA or changes in VA can contribute to the differential diagnosis, as benign nevi rarely cause visual impairment,^{76,182} whereas visual impairment or a decline in VA is associated with malignancy.^{9,78,87,96} In patients with uveal melanoma, VA in the affected eye tends to be worse than in the fellow eye.¹⁴ A baseline measure of VA is also important to determine effects of uveal melanoma treatment. Radiation therapy (RT) can cause a decline in VA, although the effects are highly variable.¹⁸³⁻¹⁸⁵ Larger tumor size and tumor location near the optic disc are associated with greater loss of VA and higher rates of local complications that result in lower rates of improvement in VA in eyes treated with iodine-125 brachytherapy.¹⁸⁶⁻¹⁸⁸

Size

The size of the tumor is an element that contributes to the differential diagnosis, particularly when trying to distinguish uveal melanoma from choroidal nevus. Although size alone does not determine diagnosis, it is one of the features that informs the diagnosis, as uveal melanomas are generally larger than choroidal nevi, and size (thickness >2 mm, tumor diameter >5 mm) is predictive of growth in melanocytic lesions.^{94,96} For lesions thought to be nevi, or small lesions with uncertain diagnosis, accurate measurements of size are important for monitoring for growth, as rapid growth is a sign of likely malignancy.⁹¹



NCCN Guidelines Version 2.2021

Melanoma: Uveal

As described in subsequent sections on treatment options for uveal melanoma, tumor size (largest basal diameter and thickness) is also important for selecting and planning treatment. For brachytherapy, selection of the appropriate size plaque is important to ensure that the lesion is fully covered, and alternative or additional treatment options need to be considered for tumors that exceed the size of the largest commercially available plaque. Selection among alternative treatment options (eg, particle beam RT, stereotactic radiosurgery [SRS], enucleation) should also depend on tumor size, and accurate description of size and shape are needed for planning particle beam RT and SRS. Accurate measurements of size and shape of the tumor are also needed for monitoring response or progression after treatment.

As described in subsequent sections, baseline tumor size (ie, largest basal diameter, thickness) is needed to determine the T stage of the tumor, which is one of the elements that determines the prognostic risk category used to inform post-treatment surveillance. (See UM-4 in the algorithm for other determinants of the prognostic risk category).

Location, Distance from Disc and Fovea, Ciliary Body Involvement

Lesion location is one of many features that can contribute to diagnosis. Proximity to the optic disc is considered a diagnostic feature of uveal melanomas, as it is correlated with likelihood of growth in melanocytic choroidal lesions.^{90-92,94} As described in subsequent sections, lesion location, including distance from disc and fovea, and ciliary body involvement, can impact imaging results, such as the ability to detect certain diagnostic features and the ability to accurately discern borders for measurement of tumor size. In some cases, color fundus photography, US, and complete clinical exam may not be sufficient for detection and/or characterization of ciliary body involvement; this is a feature that may require additional imaging approaches.¹⁸¹ As described in subsequent sections, lesion location may also impact the efficacy and safety of specific

treatments, and should be considered when selecting and planning treatment. Lesion location can help explain visual symptoms, which can be helpful for determining whether any of the treatment options are likely to improve visual symptoms. Ciliary body involvement is also one of the elements that determines the T stage of the tumor and prognostic risk category used to inform post-treatment follow-up surveillance.

Subretinal Fluid

Subretinal fluid is another feature that supports the diagnosis of uveal melanoma, as it is rare in benign choroidal nevi,^{85,99} and has been shown to develop during growth of choroidal nevi and transformation to melanoma.^{79,86} The presence of subretinal fluid has been shown to be predictive of growth in choroidal nevi or small indeterminate melanocytic lesions.^{86,91,92,94,189} One study of a large number of uveal melanomas (n = 8033) reported that subretinal fluid was present in 75% of cases.¹⁷³ However, ocular metastases from other types of primary cancer (eg, breast, lung) can also give rise to subretinal fluid,¹⁷⁹ which is why other features must also be considered for a differential diagnosis.

Orange Pigment

Orange pigment, also called lipofuscin, can be present in benign choroidal nevi,^{85,99} however, it has been shown to develop during nevi growth and transformation to uveal melanoma.^{79,86} In nevi or indeterminate small lesions, the presence of orange pigment is predictive of future growth and increased likelihood of future diagnosis as a uveal melanoma.^{83,86,90-96} Therefore, it is important to record the presence of orange pigment during initial clinical exam.

Imaging Methods

Comprehensive Eye Exam (biomicroscopy)

Initial workup should include a comprehensive eye exam using biomicroscopy to examine the front and back of the eye, including a



NCCN Guidelines Version 2.2021

Melanoma: Uveal

dilated fundus exam (indirect ophthalmoscopy). Meticulous analysis of the fundus after full pupil dilation will allow detection of most choroidal melanomas,⁸⁰ and can be used to record many of the relevant features needed for diagnosis and treatment planning. Whereas ciliary body melanomas can be difficult to detect by this method, fundus exam with good indentation can sometimes help.⁴¹

Color Fundus Photography

Color fundus photography is useful for documenting the clinical features of lesions, with the advantage of giving the most identical appearance to clinical examination.¹⁹⁰ Color fundus photography can be used to evaluate the borders of the lesion, and thereby record the location and shape; calculate lesion basal diameter and area; and be used to detect orange pigment, drusen, and halo.^{80,190-192} Areas of orange pigment seen by color fundus photography have been shown to correlate with those seen by fundus autofluorescence.^{191,192} Obtaining a baseline image is important because serial fundus photography helps to monitor nevi or indeterminate lesions for growth, and for those diagnosed with uveal melanoma, helps in monitoring response to treatment and surveillance for recurrence. Because serial images are often compared, it is important that the baseline color photograph includes all the tumor margins.¹⁷¹ A wide-angle camera may be needed to capture choroidal lesions that are particularly large or peripheral.⁸⁰ It is important to note that color fundus photography alone is not sufficient for a differential diagnosis, and diagnostic accuracy based on color fundus photography has wide interobserver variation.¹⁹³

Ocular Ultrasound

In addition to comprehensive clinical ophthalmologic exam and color fundus photography, US of the eye (ocular echography) is one of the most useful tools for diagnosis of choroidal melanomas.^{45,194-196} In experienced hands, US in combination with complete ophthalmologic clinical exam results in a high level of diagnostic accuracy (>99%) for studies of medium

to large uveal melanomas that confirmed diagnosis based on histologic evaluation after enucleation.^{167,168,197} Melanomas tend to exhibit low internal reflectivity as well as an intrinsic acoustic quiet zone on US,¹⁹⁶ features that distinguish them from a variety of other intraocular conditions. US is particularly useful when a mass cannot be visually inspected due to opacity or pathology of structures in the anterior portion of the eye such as corneal scars, cataract, or blood in the vitreous.⁴⁵

US can help in the detection of ciliary body melanomas that may be missed by fundoscopy.¹⁹⁸ US is particularly useful for determining the thickness of the tumor,^{171,194} and has been shown to have a high level of accuracy compared with tumor height measurements based on histopathology of enucleated specimens.^{199,200} For measurements of tumor thickness it is important to place the caliper at the internal scleral surface, hold the probe at right angles to the scleral and tumor surfaces, and account for overlying retinal detachment.¹⁷¹ By facilitating measurement of tumor dimensions, US is useful for detecting lesion growth.^{170,195} US can also be used to detect extraocular extension,⁴⁵ which shows hyporeflexivity on US.⁸⁰

There are two modes of US to evaluate the eye, A-mode and B-mode. Uveal melanomas show low reflectivity on both A-scan and B-scan ultrasonography, although other features differ, and these two modes have different uses.⁸⁰

A-Scan Ultrasonography

Uveal melanomas typically show low to medium internal reflectivity on A-mode US,^{41,45,170,195,201} which further decreases toward the sclera.^{45,80} Other A-scan US hallmarks specific to uveal melanoma are: 1) a regular internal structure with similar height of the inner tumor spikes or regular decrease in height (positive angle kappa sign); 2) solid consistency with no aftermovement of tumor spikes; and 3) echographic sign of vascularization with a fast, spontaneous, continuous, flickering vertical



NCCN Guidelines Version 2.2021

Melanoma: Uveal

motion of single tumor spikes.^{41,201} In contrast, choroidal metastases from other types of cancer typically show an irregular structure on A-mode US,²⁰¹ hemangiomas show much higher reflectivity,^{45,195,201} and nevi and melanocytomas show higher reflectivity and more irregular structures than malignant melanoma.²⁰¹ Fresh choroidal hemorrhages may have similar structure and reflectivity as melanomas, but will show aftermovement following small eye movements.²⁰¹

B-Scan Ultrasound

On B-scan US, posterior uveal melanomas appear as hyperchromic mass with lower reflectivity than the surrounding choroid, thus giving an acoustically hollow appearance.^{41,45,80,170} Posterior uveal melanomas, particularly the larger ones, show choroidal excavation and orbital shadowing on B-scan US.^{41,45,170,195} These features help confirm clinical diagnosis, and are distinct from hemangiomas or metastases to the eye, which typically show high reflectivity.^{170,202} However, some other lesions that may show choroidal excavation include: hemangiomas, long-standing nevi, and choroidal metastases.¹⁹⁷ B-scan US is used for obtaining tumor dimensions, extent, and shape,^{41,195,202} and is useful for characterizing larger ciliary body tumors.⁴¹ Extraocular extension can be observed by B-scan US as areas of hyporeflexivity compared to normal orbital tissue.^{80,170}

Additional Imaging

Depending on the disease characteristics observed by clinical evaluation, additional testing options may be needed to either confirm diagnosis or assess the extent of disease to determine first-line treatment options. Additional imaging options that may be considered in certain situations include: autofluorescence of the ocular fundus, OCT, retinal fluorescein angiography of the ocular fundus, and transillumination. In select situations, MRI is occasionally needed to confirm diagnosis or to plan treatment. In most cases these imaging methods are not needed, as

equivalent or better information can be obtained through standard US combined with comprehensive clinical exam.

Autofluorescence of Ocular Fundus

Fundus autofluorescence has been proposed as a method to help in the diagnosis and characterization of uveal melanomas.^{171,191,203,204} Choroidal melanoma generally shows slight intrinsic hyperautofluorescence and the brightness increases with tumor pigmentation and disrupted RPE.^{205,206} Orange pigment (lipofuscin) is the most highly autofluorescent uveal melanoma feature.^{203,205-210} Drusen can also be detected by autofluorescence,²⁰⁹ and have increased, normal, or decreased autofluorescence.^{203,207,210} Fibrous metaplasia also shows elevated autofluorescence.^{206,207,209} Autofluorescence can be used to distinguish orange pigment from drusen in both pigmented and non-pigmented tumors.¹⁷⁰

Unlike uveal melanoma and choroidal nevi, melanocytomas show hypofluorescence.²¹¹ Comparative studies have shown that the autofluorescence pattern often matches that of orange pigment and hyperpigmentation seen by color fundus photography.^{45,192,207} Based on comparative studies, it is not clear that fundus autofluorescence increases the detection rate of orange pigment relative to standard ophthalmologic exam.²¹²

Optical Coherence Tomography

OCT is another imaging method proposed for assisting diagnosis of uveal melanoma^{45,171} and treatment planning.⁴⁵ Spectral domain OCT (SD-OCT) allows the detailed evaluation of the retina and RPE, changes in which are more common in choroidal melanoma versus choroidal nevi.^{45,203} OCT can help identify overlying retinal detachment or edema, even before clinically apparent.²⁰³ Results differ across comparative studies regarding whether OCT is more sensitive than standard ophthalmologic exam plus US for



NCCN Guidelines Version 2.2021

Melanoma: Uveal

detecting subretinal fluid.²¹²⁻²¹⁴ OCT can detect subretinal and intraretinal fluid, subretinal lipofuscin, retinal epithelium atrophy and degeneration, shaggy photoreceptors, and structural loss of photoreceptors in the neurosensory retina.^{45,170,203,215,216} These features are more likely in choroidal melanoma than in choroidal nevi, although some features are more useful than others for differential diagnosis, especially in small lesions.^{45,214,215,217,218}

In OCT, the structure of the lesion differed between choroidal nevi, melanomas, hemangiomas, and metastases.²¹⁶ Optical density ratio based on OCT can also be used to distinguish choroidal melanomas from choroidal metastases.²¹⁹ Enhanced depth imaging OCT (EDI-OCT) is particularly useful for detecting small lesions, and distinguishing small nevi from small choroidal melanoma. It is less useful for thick tumors.⁴¹ OCT angiography (OCT-A) can be used to distinguish choroidal nevi from choroidal melanoma based on margin character (well-delimited vs. imprecise), reflectivity of choroid capillary vasculature (hyper vs. hypo), and characteristics of lesion vasculature.^{220,221} Both OCT and US have been evaluated for characterizing iris and ciliary body tumors. US biomicroscopy provides better overall visualization and better resolution of the posterior margin, while OCT provides better resolution of the anterior segment anatomy and margin.²²²

Retinal Fluorescein Angiography

Retinal fluorescein angiography can be used to characterize lesion vasculature, which can aid in diagnosis because choroidal melanomas may have intrinsic tumor circulation, sometimes called “double circulation,” in addition to normal choroidal vasculature.^{41,45,80,170,195,196,223} Observation of the tumor vasculature is helpful in distinguishing melanomas from choroidal nevi, hemorrhagic degeneration, or choroidal melanoma.^{45,80,224} After treatment with brachytherapy, fluorescein angiography is also useful for detection of complications such as radiation retinopathy.^{45,80}

Transillumination

Transillumination has been tested as a method for detecting and measuring uveal melanomas that may be difficult to detect or fully characterize by other techniques. Examples include large ciliary body melanomas,^{41,45,80} or tumors obscured by cataracts.²²⁵ Compared with tumor dimension measurements based on histology of enucleated eyes, transillumination tends to overestimate both the thickness and diameter of tumors, and is prone to shadowing artifacts.^{200,226} Therefore, it is only used if other methods have proven inadequate.

MRI

MRI is generally not needed for diagnosis and workup, but occasionally is necessary in cases with features that may make other imaging methods difficult, such as secondary vitreous hemorrhage, extensive retinal detachment, or cataract.^{45,80} MRI may be useful in determining whether cataract is caused by an underlying ciliary body melanoma, and can help distinguish uveal melanomas from hemangiomas.⁴⁵ Uveal melanomas usually have high signal intensity in T1-weighted MRI images and low signal intensity in T2-weighted images.^{41,45,80,170} Although similar signal pattern can be caused by hemorrhage or necrosis,^{45,80} hemangiomas typically have hyperintense signal on T-weighted images and T2-weighted images are isointense with the vitreous.⁴⁵ MRI is useful for detecting and characterizing extraocular extension,^{45,80,170,194,227,228} and is also used for RT planning.^{80,170,194,229,230}

Biopsy

The use of biopsy as part of workup for uveal melanoma is an issue of some debate. Potential benefits of biopsy during workup are 1) cytologic/histologic confirmation of diagnosis; 2) potential for molecular analysis that may impact eligibility for current or future clinical trials; and 3) potential for molecular analyses that may provide more accurate prognostic assessment for risk of metastasis, which may inform future



NCCN Guidelines Version 2.2021

Melanoma: Uveal

follow-up surveillance. Potential harms of biopsy of the primary tumor include 1) risk of complications from the procedure that damage the eye; 2) the risk of tumor seeding leading to local or distant recurrence; and 3) the risk of inadequate sampling resulting in misdiagnoses or inaccurate or inconclusive molecular testing results. As discussed in greater detail below, the likelihood of each of these potential benefits and potential harms is debated, as there are many different biopsy methods than can be used, and the likelihood of benefit versus harm may also vary across practitioners.

There are a wide variety of biopsy techniques that have been tested and are sometimes used for choroidal or ciliary body tumors. Some involve a transscleral (direct) approach, where the tumor is approached from the outside, the needle first puncturing the sclera over the tumor, then the tumor itself, leaving the retina intact.²³¹ Others use a transvitreal (indirect) approach, with anterior entry through the pars plana opposite the tumor, going through the vitreous body and retina to reach the tumor.²³¹ Tumor location is a major determinant of which approach is likely to be successful and safe. Table 2 provides a list of techniques (or categories of techniques) for biopsying choroidal and ciliary body tumors that have been used to assist with diagnosis and/or prognostication in primary uveal melanomas. Key features of these biopsy methods are also included in Table 2: the typical surgical approach (transscleral or transvitreal/transretinal), tumor location(s) for which the biopsy method was developed and/or is most often used, and the type of sample obtained, as some of these methods provide aspirated cells that can be analyzed by cytopathology, whereas other methods can provide tissue samples that can be sectioned for histopathology. Table 2 also lists representative studies that describe these biopsy methods in more detail, report diagnostic and/or prognostic yield for these biopsy options (percent of biopsies providing sufficient material for diagnostic or prognostic analyses), and provide safety data, including intraoperative or

postoperative procedure-related complications and analyses aimed at determining the risk of tumor seeding (eg, evidence of tumor cell tracks/contamination in neighboring tissues; rates of local recurrence during follow-up).

There is some risk of complications with any biopsy procedure. Any of these procedures can result in the following intraocular complications/morbidities, which if severe may require secondary procedures or other interventions for management: hemorrhage (eg, vitreal, subretinal, choroidal, perilesional), decrease in VA, retinal detachment (eg, rhegmatogenous, exudative), retinal perforation, hypotony, and endophthalmitis.²³²⁻²⁴³ Longitudinal population-based studies have shown that biopsy does not impact all-cause mortality or disease-specific death—for better or worse—in patients with uveal melanoma.²⁴⁴⁻²⁴⁶

Fine-Needle Aspiration Biopsy

Fine-needle aspiration biopsy (FNAB) is the simplest, most inexpensive, and most commonly used method for biopsy of choroid or ciliary body tumors presumed to be melanoma.^{231,247,248} Details of the technique are described in several review articles,^{231,247,248} as well as multiple primary reports from many different centers.^{88,232,233,235,249-251} FNAB can be done via a transvitreal or transscleral approach depending on the location of the tumor. The transvitreal approach is generally easier due to better intraoperative illumination and visualization options.^{231,248}

The disadvantage to FNAB is that the amount of material obtained may be small, and multiple passes may be needed to obtain enough material for cytologic and molecular genetic analysis.^{232,236,251,252} The yield from FNAB—both for cytologic confirmation of diagnosis and for molecular analyses for prognostication—varies across studies.^{88,232,233,235,236,245,246,249-258} Some studies suggest that transvitreal (vs. transscleral) approach is



NCCN Guidelines Version 2.2021

Melanoma: Uveal

associated with improved FNAB yield, but some studies found no difference in yield.^{232,233,235,256,258,259} Some studies have suggested that FNAB yield is higher for larger tumors, and is particularly impacted by the thickness of the tumor,^{233,246,250,256-258} but a recent study showed that high yields (>87%) can be obtained even in thin tumors (<3.5-mm thick), for both the transscleral and transvitreal approach.²³² Studies of patients with uncertain diagnoses based on standard noninvasive techniques have shown that FNAB can help distinguish between uveal melanoma and borderline or benign melanocytic nevus, even among small lesions,^{88,257} and can clarify whether a lesion is a primary uveal melanoma versus metastasis from another cancer, another type of primary ocular tumor, a melanocytoma, or RPE proliferation.²⁵¹

For FNAB, the most common complication is vitreal hemorrhage, but its rate varies widely across studies.^{232,233,236,245,250,259} Some studies describe methods to reduce or prevent this.²⁵⁴ Most vitreal hemorrhages are focal/localized and resolve without further intervention,^{232,233,245,250,251,259} but some are diffuse, more extensive, persist and/or impact VA, and require secondary surgical intervention (eg, vitrectomy) for management.^{232,233,235,236} The risk of hemorrhage requiring secondary surgical management varies widely, even across recent studies, ranging from 1% to 15% of patients with FNAB.^{232,233,235,236,250} Some studies have suggested that vitreal hemorrhage is more likely with a transvitreal than with a transscleral approach.^{232,235} FNAB may also impact VA, improving some cases but reducing VA in other cases.²³³ Other complications that have been reported, but are rare, include rhegmatogenous retinal detachment and worsening exudative retinal detachment.^{233,235,236,245,246,251,259}

Concerns about FNAB causing tumor seeding have been raised based on findings of melanoma cells left in the needle track,^{253,255,260-262} and some have suggested procedure adjustments for reducing the likelihood of

tumor cell seeding FNAB.^{248,253,261} A few case reports found local recurrences at FNAB entry sites.²⁶³⁻²⁶⁵ However, multiple follow-up studies with large patient populations have revealed no local recurrences after FNAB (and non-surgical treatment),^{88,232,235,245,246,250,251,254,255,259} and one case series found no increased risk of metastasis among untreated patients who had post-biopsy evidence of melanoma cell dissemination inside the eye.²⁶⁰ FNAB is therefore generally thought to be safe and to have low risk of seeding.

Other Biopsy Techniques

Other biopsy techniques that have been tested in large populations of patients with uveal melanoma are those that use tools from vitrectomy systems both to access tumor via a transvitreal/transretinal approach and to extract tumor tissue using the vitreous cutter and aspiration through the canula. These procedures do not necessarily include a vitrectomy. There are a variety of procedures that fall into this category, and are described in a series of publications based on clinical practices both in the United States and Europe, including several reviews.^{231,237,238,240,248,266,267} These techniques have been used successfully on anterior, posterior, equatorial, and peripapillary lesions.^{237-240,268} They generally result in larger sample sizes than FNAB, although like FNAB multiple passes may be necessary.^{237,238,266,267} For this reason it has been suggested that these methods may be useful in patients with tumors that are too small or inaccessible for FNAB, or for tumors where FNAB has failed. One study reported that for choroidal melanomas with thickness of 2.0 mm or less, sufficient sample for prognostic evaluation was obtained in 100% of patients.²³⁷ Reported yields from these procedures range from 89% to 99% for diagnosis of choroidal lesions, and 97% to 100% for prognostic testing on uveal melanomas.^{237-240,267,268} Studies have shown that these biopsy techniques can be used to diagnose tumors that are unclassifiable based on standard noninvasive diagnostic techniques, and can



NCCN Guidelines Version 2.2021

Melanoma: Uveal

differentiate uveal melanoma from benign nevus, metastases from other cancers, vasoproliferative tumor, hemorrhage, gliosis, and scleritis.^{240,268}

These approaches are less broadly used than FNAB, are more expensive, and require additional expertise.^{231,248} Like FNAB, hemorrhage is the most common complication with these biopsy procedures, is normally localized, and usually resolves without intervention.^{237,239,240} Because these techniques are more invasive, however, retinal detachment and severe hemorrhage are more common, and more patients require intervention for management, either at the time of biopsy or as a later procedure.^{234,238-240,248} Decrease in VA due to these procedures is not uncommon.^{238,239}

Like FNAB, studies have published evidence that these procedures may leave tumor cells along the access pathways, but most studies, including those with large patient samples, have not observed local recurrence during follow-up.^{239,240} There are a few cases reported of local recurrences at biopsy entry sites.^{264,268-270} Incisional biopsy techniques are more invasive than vitrectomy system-assisted biopsies, and likewise yield more material, but also are more likely to lead to complications.²⁴¹⁻²⁴³ These methods have been used for cases that are particularly hard to diagnose. Excisional biopsy, using either transscleral resection or endoresection, was also explored as an option for both biopsy and primary treatment,²⁷¹ but is not included in Table 2 because it is no longer used due to technical challenges, risk of complications, and concerns about tumor seeding.^{170,272-282}

NCCN Biopsy Recommendations

Biopsy may be considered if needed to confirm diagnosis or for prognostic analysis for risk stratification. Biopsy is usually not necessary for initial diagnosis of uveal melanoma and selection of first-line treatment, but may be useful in cases of uncertainty regarding diagnosis, such as for amelanotic tumors or retinal detachment. Biopsy of the primary tumor may provide prognostic information that can help inform frequency of follow-up

and may be needed for clinical trial eligibility. If biopsy is performed, molecular/chromosomal testing for prognostication is preferred over cytology alone. The risks/benefits of biopsy for prognostic analysis should be carefully considered and discussed.

Observation for Uncertain Diagnosis in Patients with Low Risk

Findings from the clinical workup should be used to determine initial management. Observation may be appropriate for patients with uncertain diagnosis and/or fewer than three risk factors for lesion growth (Table 1). Studies have found that for patients with small choroidal lesions presumed to be nevi or indeterminate, deferring treatment until evidence of growth or features of malignancy develop (eg, orange pigment, subretinal fluid, symptoms) is associated with a very low risk of metastasis,^{91,95} and even lower risk of death from uveal melanoma.⁸⁴ For patients who meet the criteria for observation (rather than immediate treatment), regular follow-up is recommended to periodically re-evaluate for growth or features of malignancy. Follow-up tests should include the same tests recommended for initial workup and diagnosis that would help clarify if there is progression and determine the natural history of the indeterminate lesion. Initially (ie, upon first discovery of the lesion), these patients should be re-evaluated every 2 to 4 months to determine rate of growth (if any) and to monitor for other changes indicative of malignancy. Close follow-up for 5 years is recommended to firmly establish whether or not there is any growth or progression; some lesions that initially seem stable may suddenly begin to grow and transform. The frequency of re-evaluation should depend on the index of suspicion, patient age, and medical frailty. For example, the presence of one to two risk factors for growth (Table 1), or evidence of changes would increase suspicion. If the size and features of a lesion appear static after 5 years of follow-up, the patient can be followed annually thereafter. Lesions that demonstrate growth or develop



NCCN Guidelines Version 2.2021

Melanoma: Uveal

additional risk factors for growth (>3 total) should be managed as uveal melanoma, even if diagnosis is still uncertain.

Further Workup Prior to Treatment

Further workup prior to treatment may be needed in some cases to aid in treatment selection and planning. For example, for tumors that are large, close to the optic nerve, or have suspected/confirmed extraocular extension, MRI should be performed, if not previously done, to determine whether radiation (particle beam or SRS) is an option, or whether enucleation is needed, and for radiation planning. MRI should be performed with and without contrast unless contrast is contraindicated. MRI is useful for detecting and characterizing extraocular extension and for RT planning (particle beam or SRS).^{45,80,170,194,227-229} Ciliary body involvement or extraocular extension should be assessed and documented, as these features may impact the feasibility, safety, and efficacy of certain treatment options. If not already performed, biopsy of the primary tumor should be considered for prognostic analysis, as risk stratification should inform the frequency of follow-up treatment. There is some evidence to suggest that radiation (all modalities) may alter molecular genetic features of the tumors, reducing the accuracy of prognostication based on samples taken after radiation treatment.²⁸³

Baseline imaging to screen for systemic disease is also recommended prior to treatment. Despite lack of treatment options for patients with metastatic disease, NCCN favors staging before primary treatment. For patients who have small, low-risk tumors, but are planning to receive treatment (ie, those with a definite diagnosis of uveal melanoma, or uncertain diagnosis but three or more risk factors for growth [Table 1]), deferring extraocular baseline imaging until after primary treatment can be considered. The most frequent sites of metastasis are liver, lungs, skin/soft tissue, and bones.²¹ At minimum, all patients receiving baseline imaging should have contrast-enhanced MR or US of the liver, with

modality preference determined by expertise at the treating institution. Additional imaging modalities may include chest/abdominal/pelvic CT with contrast. However, screening should limit radiation exposure whenever possible. Unless there is a specific contraindication to the administration of IV contrast (ie, renal impairment or history of a severe allergy), all cross-sectional imaging studies should be performed with and without IV contrast.

If not already performed, biopsy of the primary tumor for prognostic analysis should be considered prior to treatment.

Treatment of Localized Primary Uveal Melanoma

Most uveal melanomas are localized at first presentation, and only a small percentage of cases present with metastases (<3%).^{6,10-14} Local treatment for primary uveal melanoma is effective in preventing local recurrence in greater than 85% of cases,^{272,284} yet the rate of metastasis within 20 years after treatment is approximately 20% to 70% for patients who present with localized uveal melanoma, depending on tumor stage/size at diagnosis.^{8,13,26,285} Whereas surgical approaches are the mainstay of treatment for localized cutaneous melanoma, and historically most uveal melanomas were treated with surgery, the field has moved away from using surgery in all patients,^{2,286} because different modalities, primarily various forms of RT, have been found to be just as safe and effective for those with limited disease, and can preserve the affected eye. Some surgical approaches are still used in patients with extensive local disease, but most patients with localized primary uveal melanoma are treated with some form of RT.²⁸⁷ There are a number of other ablative techniques that are occasionally used for localized primary melanoma, including laser therapy, cryotherapy, and photodynamic therapy. Each of these primary treatment modalities is described in more detail below. Selection among these techniques is guided by many case-specific factors, including the



NCCN Guidelines Version 2.2021

Melanoma: Uveal

size and location of the tumor, presence of extraocular extension, visual potential, patient age, and preference.

Surgical Options

Prior to the development of effective RT options, surgery was used to treat most uveal melanomas.

Local Resection

There are a variety of methods for local resection of uveal melanoma aimed at conserving the eye and useful vision.^{170,280,281} These include transretinal (endoresection) and transscleral (exoresection) approaches.¹⁷⁰ These methods can be technically challenging,^{41,170} with high rates of immediate postoperative complications such as hemorrhage, retinal detachment, ocular hypertension, and proliferative vitreoretinopathy, which may require repeat surgery.^{170,277,280-282} Endoresection is the less technically challenging approach,^{280,281} and based on retrospective analyses is associated with low local failure rate (<6%).^{272,288-293} Due to lack of prospective data on this technique, it is unclear whether it provides the same protection from recurrence and metastases as treatment options that have been prospectively studied (ie, brachytherapy, enucleation). Exoresection is the more technically challenging form of local resection, particularly with large and posterior tumors, and is usually performed with hypotensive anesthesia and other measures to control intraoperative hemorrhage.^{277,280,281} Most studies (all retrospective) have reported high local failure rates (20%–24%) after trans-scleral resection,²⁷²⁻²⁷⁵ which tend to be higher than with enucleation or brachytherapy.²⁷⁶⁻²⁷⁹

Local resection is not recommended in the NCCN Guidelines for Melanoma: Uveal as a primary treatment option for choroidal or ciliary body melanoma. For patients with primary tumors amenable to eye-conserving approaches, RT-based approaches are preferred. For tumors

too large for brachytherapy, enucleation is preferred over local resection, as the latter is technically difficult for large tumors.

Enucleation

Enucleation is a technically less challenging procedure than local resection of uveal melanoma, and historically is the most widely used treatment for uveal melanoma. Results from the Collaborative Ocular Melanoma Study (COMS) prospective randomized trial suggest that enucleation is associated with a very low risk of local recurrence (~1%),^{294,295} notably lower than the rate of local recurrence reported for retrospective studies in patients treated with primary local resection.^{272-275,288-293} Enucleation procedures have been standardized; they involve complete removal of the eye and in most cases include insertion of an orbital implant.^{170,281,296,297} Both porous and nonporous implants have been shown to result in similar outcomes, although there may be a higher incidence of ptosis with acrylic implants, and a greater need for ophthalmologists' treatment (eg, topical antibiotics, polishing or refitting of prosthesis) with hydroxyapatite implants.²⁹⁸

For enucleation, the complications reported in the COMS trial, during or less than 24 hours following surgery, include pain, hemorrhage, nausea/vomiting, cardiovascular or pulmonary problems, urinary retention, fever, and local surgical problems.²⁹⁴ Complications 1 to 6 weeks after surgery included pain requiring longer hospital stay, pain requiring medication, conjunctival wound dehiscence, infection, decreased facial sensation, eyelid swelling, inflammation, implant displacement, loss of hair, ptosis, conjunctival chemosis, ecchymosis, and orbital or conjunctival hemorrhage.²⁹⁴ Long-term follow-up has shown that other problems after enucleation include poor motility of prosthesis, poor alignment of prosthesis, severe ptosis, and displacement of implant.²⁹⁴ Enucleation can also result in phantom eye syndrome, including visual sensations, seeing, and pain, which can be distressing to some patients.²⁹⁹



NCCN Guidelines Version 2.2021

Melanoma: Uveal

Pre-enucleation RT is generally not used because results from the COMS randomized trial in large tumors (height ≥ 2 mm and diameter ≥ 16 mm; or height ≥ 10 mm and any diameter; or height ≥ 8 , any diameter, if proximal tumor border < 2 mm to optic disc) showed that pre-enucleation RT had no impact on survival (death from melanoma metastasis, all-cause death) compared with enucleation alone,^{294,300,301} confirming results of prior retrospective studies.³⁰² In the COMS trial for large tumors, 5-year tumor-related mortality was 28% for patients treated with enucleation.³⁰⁰

In the COMS randomized trial in medium choroidal melanoma tumors (height 2.5–10 mm, diameter ≤ 16 mm, and no extrascleral extension ≥ 2.0 mm thick), outcomes (ie, cumulative mortality, melanoma-specific mortality) for enucleation were similar to those with iodine-125 brachytherapy.^{303,304} For medium tumors, the 5-year disease-specific survival rate was 11% for patients treated with enucleation (14% and 5% for patients with tumor diameter > 11 mm and ≤ 11 mm, respectively).³⁰⁴

One prospective and several retrospective studies also found that survival was similar after enucleation versus cobalt plaque brachytherapy,³⁰⁵⁻³⁰⁹ or a mix of brachytherapy plaque types,³¹⁰ or versus proton beam RT.³¹¹ Retrospective studies suggest that outcomes (ie, overall survival [OS], metastasis-free survival, melanoma-related mortality) are similar for enucleation versus proton beam RT or versus SRS.³¹²⁻³¹⁵ Despite the negative aspects of enucleation (relative to RT therapy), including worse effects on certain visual functions (eg, peripheral vision, night driving, judging distances), greater decrease in role functioning, and larger reductions in physical and functional well-being, some studies have found that overall quality of life for patients undergoing enucleation appears to be similar to that for those treated with RT.³¹⁶⁻³²¹

Based on results of the prospective studies comparing enucleation with brachytherapy, enucleation is generally only recommended for patients with tumors that are unsuitable for brachytherapy treatment, such as those

that are too large to be effectively treated by commercially available plaques, or that have optic nerve involvement. For such tumors, enucleation is an option, but other types of RT (ie, particle beam, stereotactic RT [SRT]) are also possibilities. Enucleation is sometimes reserved for cases that would be difficult to treat using only RT, such as those with neovascular glaucoma, tumor replacing greater than 50% of the globe, blindness, painful eyes, or extensive extraocular extension. In addition to use as a primary treatment, enucleation is also often used as a secondary therapy for patients who develop local recurrence or complications after eye-sparing primary treatment. Pathologic evaluation should follow the uveal melanoma synoptic report recommendations by the College of American Pathologists (available at:

<http://documents.cap.org/protocols/cp-uveal-melanoma-17protocol-4000.pdf>).³²²

Radiation Therapy

RT is the most commonly used first-line treatment for uveal melanoma,² as several RT approaches have been shown to have similar efficacy as enucleation for reducing the risk of metastasis and death from disease.³⁰³⁻

³¹⁵ Brachytherapy and charged particle RT are the RT modalities considered appropriate for primary therapy for most cases of uveal melanoma, whereas photon RT and SRT are less often used as primary treatment for uveal melanoma. SRS is sometimes used for large primary tumors, and photon RT is generally only used as an adjuvant to surgery.

Plaque Brachytherapy

Plaque brachytherapy is a commonly used form of definitive RT for the primary tumor.^{286,287,323,324} Brachytherapy is often used (for localized primary uveal melanoma) based on results from a large prospective randomized trial (COMS) showing that long-term outcomes were not significantly different with plaque brachytherapy (n = 657) versus enucleation (n = 660) for patients with small- to medium-sized choroidal



NCCN Guidelines Version 2.2021

Melanoma: Uveal

melanomas (2.5–10.0 mm in apical height [2.5–8.0 mm if peripapillary] and ≤ 16 mm in maximum basal diameter, no extrascleral extension ≥ 2.0 mm thick).^{303,304} In this study the 5-year risk of treatment failure after brachytherapy was 10.3%.¹⁸⁷ Treatment failure was defined as tumor expansion ($\geq 15\%$ increase in height or ≥ 250 μm in any tumor boundary) or extrascleral extension (>2 mm). Risk factors for treatment failure were older age, greater tumor thickness, and proximity of the tumor to the foveal avascular zone. Other more recent studies have reported local failure rates ranging from 0% to approximately 20% for patients treated with iodine-125 plaques, and local failure rates were in this range for patients treated with other types of brachytherapy plaques (ie, ruthenium-106, palladium-103, cesium-131).^{272,325–328} It is important to note that late treatment failures (up to 12 years) after brachytherapy have been observed.³²⁷

In the COMS randomized trial in medium choroidal melanoma tumors (height 2.5–10 mm, diameter ≤ 16 mm, no extrascleral extension ≥ 2.0 mm thick), after a minimum of 5 years of follow-up (range, 5–15 years), there were no treatment-dependent differences in all-cause mortality or death with confirmed melanoma metastasis.³⁰⁴ There was no difference across arms in the rate of death with histologically confirmed metastasis (enucleation vs. brachytherapy: 11 vs. 10% at 5 years; 17 vs. 18% at 10 years) or all-cause mortality (19% at 5 years and 35% at 10 years, for each arm).³⁰⁴ The only factors correlated with these outcomes were age and maximum basal diameter, but even after adjustment for these variables, there were no treatment-dependent differences in all-cause mortality or mortality with confirmed melanoma metastasis at time of death.³⁰⁴

In the same trial, intraoperative/immediate postoperative complications observed with similar frequency across brachytherapy and enucleation arms included anesthetic complications, pain requiring medication, other

hemorrhage, cardiovascular or pulmonary problems, urinary problems, and local surgical problems.³⁰³ Immediate complications seen only in the brachytherapy arm included intraocular hemorrhage, scleral perforation, and vortex vein rupture.³⁰³ In the brachytherapy arm, the most common long-term complications were loss of VA and growth of tumor or other indications that lead to enucleation.³⁰³ After 3 years of follow-up, approximately half of the patients (49%) treated with brachytherapy lost six or more lines of VA (compared with before treatment), and of patients with VA better than 20/200 before treatment, 43% had VA of 20/200 or worse.¹⁸⁶ Factors associated with loss of VA included greater baseline tumor apical height, shorter distance between the tumor and the foveal avascular zone, presence of tumor-associated retinal detachment, non-dome-shaped tumor, and patient history of diabetes.¹⁸⁶ During the first 5 years of follow-up, cataracts developed in 68% of eyes treated with brachytherapy, and 12% had undergone cataract surgery.³²⁹ Cataract surgery results in VA improving by 2 or more lines in 66%, and stabilizing VA in 26%.³²⁹ The 5-year cumulative rate of enucleation was approximately 12%,^{187,303} most often due to treatment failure during the first 3 years after brachytherapy, and to eye pain beyond 3 years after treatment.¹⁸⁷

When evaluating patients for brachytherapy, it is important to consider the entry criteria and treatment parameters used in the COMS trial that compared brachytherapy with enucleation. The COMS trial included only patients with tumors that were choroidal;³⁰³ those with tumors contiguous with the optic disc were excluded, as were those with metastases from melanoma or another cancer (except nonmelanoma skin cancers).³⁰⁴ Only 16% of patients had tumors less than 2.0 mm from the optic disc.³⁰³ Most of the tumors included were dome-shaped on B-scan US (77%), and about half had non-rhegmatogenous retinal detachment (54%–55%); a few ($<1\%$) had rhegmatogenous retinal detachment.³⁰³



NCCN Guidelines Version 2.2021

Melanoma: Uveal

Prospective studies in patients with small choroidal tumors also found that iodine-125 brachytherapy resulted in tumor regression in most cases (98%),³³⁰ less than 3% recurred, and 98% achieved globe conservation.³³¹ Melanoma-specific mortality at 5 years was 3.9%.³³¹

Whereas the plaques used in the COMS trial were all iodine-125, one prospective and several retrospective studies also found that survival was similar after enucleation versus cobalt plaque,³⁰⁵⁻³⁰⁹ or a mix of brachytherapy plaque types.³¹⁰ A meta-analysis of studies testing Ru plaques in patients with uveal melanoma reported a 5-year melanoma-related mortality rate of 6% for small and medium tumors (T1/T2), and 26% for large tumors (T3).³³² Palladium-103 brachytherapy plaques also appear to perform similarly to iodine-125 plaques.³³³

Recent analyses, including a few prospective studies, have aimed at identifying factors associated with loss of VA after brachytherapy, with varying results. Factors identified in one or more studies include applicator size, tumor basal diameter, juxtapapillary location, dose (close to foveola, or retinal), increased tumor height, radiation maculopathy, and radiation optic neuropathy.^{184,334,335} Some studies have reported adjustments to technique that may reduce the risk of vision decline.³²⁸ One prospective study of 650 patients with medium-sized choroidal melanoma found that retinal hemorrhage in the macular and peripapillary zone, optical disc hemorrhage, microaneurysms, and foveal RPE atrophy were more prevalent and severe after brachytherapy than before treatment.³³⁶ Macular angiographic leakage tended to worsen after brachytherapy, and optic neuropathy was present in 27% of patients 5 years after treatment.³³⁶

NCCN Recommendations for Brachytherapy

Plaque brachytherapy is appropriate as an upfront therapy after initial diagnosis, or after local recurrence following a prior local therapy. Plaque brachytherapy is appropriate for patients with tumors 19 mm or less in largest base diameter, and 10 mm or less in thickness, based on the size

of the largest commercially available plaques. The plaque margin on the tumor border should be 2 mm or greater when feasible (diameter of plaque ≥ 4 mm larger than largest base diameter of tumor; the plaque should cover the tumor with a ≥ 2 -mm circumferential margin). The exception is for tumors near the optic nerve where it may be impossible to achieve adequate coverage of the margins. The largest commercially available brachytherapy plaque is 23 mm in diameter; thus, plaque brachytherapy is recommended only for tumors with largest basal diameter 19 mm or less. Round or custom plaques are most commonly used. Custom plaques (eg, notched) are commonly used for tumors in specific locations (eg, peripapillary). Preliminary data from a prospective study suggest that slotted plaques provide local control of choroidal melanomas adjacent to the optic nerve, but with a high risk of radiation optic neuropathy.³³⁷ Plaque brachytherapy should be performed by an experienced multidisciplinary team including an ophthalmic oncologist, radiation oncologist, and brachytherapy physicist.¹⁸⁵ Tumor localization for brachytherapy may be performed using indirect ophthalmoscopy, transillumination, light pipe diathermy, and/or US (intraoperative and/or preoperative).³³⁸ MRI or CT may be used for preoperative planning.

Dosing Recommendations for Brachytherapy

In patients receiving plaque brachytherapy for uveal melanoma, the radiation dose at the base of the tumor (the surface of the tumor closest to the plaque) will always be higher than the dose at the apex of the tumor (the point of the tumor furthest from the plaque). Clinical practice varies regarding whether the radiation dose prescribed is the dose at the base of the tumor or the dose at the apex of the tumor.

Using iodine-125 COMS plaques, 85 Gy should be prescribed to the apex of the tumor at low dose-rate (≥ 0.6 Gy/h), as this was the dose used in the COMS study of medium-sized uveal melanomas, showing similar survival with brachytherapy versus enucleation.^{303,304} Dose adjustments may need



NCCN Guidelines Version 2.2021

Melanoma: Uveal

to be made for non-COMS plaques.³³⁹ Other prospective and retrospective studies using iodine-125 brachytherapy dosing similar to COMS have reported similarly high rates of local control,^{327,328,340-343} and a retrospective study found that efficacy outcomes were similar to those in patients treated with SRT.³⁴⁴ As expected, studies using iodine-125 brachytherapy doses higher than in COMS (eg, 100 Gy to tumor apex) also reported recurrence rates that compared favorably with other treatment modalities (eg, transpupillary thermotherapy [TTT], proton beam RT).^{330,345} In contrast, both retrospective and randomized prospective studies using iodine-125 brachytherapy doses of less than or equal to 80 Gy reported recurrence rates higher than with particle beam RT.^{47,346-349} One prospective and several retrospective studies have reported that a lower iodine-125 brachytherapy dose was associated with local tumor recurrence and decreased systemic control,^{338,350-352} whereas other retrospective studies have found no significant correlation between dose and local recurrence, distant metastasis, or survival.^{342,353,354} A meta-analysis found that recurrence rates tended to decrease with increasing iodine-125 brachytherapy dose to the tumor apex, but the effect was small and not statistically significant.³²⁵

Another issue of some debate is the relationship between brachytherapy dose and complications, changes in vision after treatment, and eye preservation. One prospective and multiple retrospective analyses have found correlations between increasing iodine-125 dose and loss of VA, risk of RT-related complications (eg, cataract, optic neuropathy, glaucoma), and/or need for secondary enucleation.^{334,342,351,353-358} Results are mixed, however, and retrospective analyses did not always find significant correlations between dose and these negative outcomes.^{356,359,360} It is important to note that for the few comparative studies that used relatively high doses of iodine-125 brachytherapy (≥85 Gy to the tumor apex), rates of RT-related complications and vision loss

were still similar to or better than with SRT or particle-beam RT.^{344,345} Prospective trials are needed to determine optimal iodine-125 dosing.

Studies using brachytherapy plaques made of other radioisotopes, primarily ruthenium-106, but also palladium-103, strontium-90, and cobalt-60, have tested a wide range of doses (60–150 Gy to tumor apex), but most reported mean/median dose to the apex between 80 and 130 Gy.^{184,332,333,345,361-369} Only a few of these studies were prospective.^{333,366} Although there is evidence to suggest that results differ between isotopes (even when apex dose is similar),^{345,362} the optimal dose has not been determined for any of these isotopes. Results are inconsistent across retrospective studies that attempted to evaluate the impact of dose on local/distant failure rate,^{361,367} or the impact of dose on RT-related complications and VA loss.^{184,365} Results from a few retrospective studies using ruthenium-106 plaques suggest that while a target dose of 100 Gy to the tumor apex may result in poorer local control than proton beam RT, higher doses (mean 137 Gy at apex) may provide similar local control as SRS.^{345,368} Due to lack of data, the NCCN Panel recommendations are fairly broad, suggesting that when using ruthenium-106, palladium-103, strontium-90, cobalt-60, and cesium-131 plaques, 60 to 100 Gy may be prescribed at low dose rate to the tumor apex; alternatively, a minimum dose may be prescribed to the base of the tumor. The plaque margin on the tumor border may vary for other (non-iodine-125) radioisotopes.

Particle Beam Radiation Therapy

Particle beam RT includes radiation with protons, carbon ions, or helium ions, and is a common form of definitive RT for the primary tumor.³²³ Prospective studies and a systematic review found that disease-specific survival in patients with uveal melanoma treated with particle beam RT was similar or better than for plaque brachytherapy.^{47,347,349} Compared with brachytherapy, particle beam RT was associated with higher rates of local control and similar or lower rates of enucleation during follow-up.^{47,347,349}



NCCN Guidelines Version 2.2021

Melanoma: Uveal

Across studies, local recurrence rates with charged particle therapy ranged from 3% to 10%.^{272,370} However, multivariate analysis of a real-world database found that treatment with protons was associated with poorer OS compared with brachytherapy treatment.³⁷¹

Decrease in VA and loss of vision can occur with particle beam RT.^{370,372} Toxicities include vitreous hemorrhage, subretinal exudation in macula, posterior subcapsular opacity, radiation keratopathy, rubeosis/neovascular glaucoma, radiation maculopathy, and papillopathy.^{370,373}

NCCN Recommendations for Particle Beam Radiation Therapy

Particle beam RT should be performed by an experienced multidisciplinary team including an ophthalmic oncologist, radiation oncologist, and particle beam physicist.³⁷⁴ In settings where the appropriate expertise is available, particle beam therapy (proton, carbon ion, or helium ion) is appropriate as upfront therapy after initial diagnosis, after margin-positive enucleation, or for intraocular or orbital recurrence. It is important that the team have experience treating uveal melanoma with the specific type of particle beam used (proton, carbon ion, or helium ion). Particle beam RT is an option regardless of the size of the primary lesion, and is the preferred method of RT for tumors that are too large or too near the optic nerve to be effectively treated with brachytherapy. Tumor localization for particle beam RT may be performed using indirect ophthalmoscopy, transillumination, and/or US (intraoperative and/or preoperative), MRI, and/or CT.

Dosing Recommendations for Particle Beam Radiation Therapy

Particle beam dosing for intraocular tumors is as follows: using protons, 50–70 cobalt Gray equivalent (CGyE) in 4 to 5 fractions should be prescribed to encompass the planning target volume (PTV) surrounding the tumor;^{370,374,375} using carbon ions, 60 to 85 CGyE in 5 fractions should be prescribed to encompass the PTV surrounding the tumor.³⁷³ Fiducial markers (tantalum clips) are encouraged to permit eye and tumor position

verification for image-guided radiotherapy delivery. Volumetric planning in three dimensions (with or without CT and/or MRI) is encouraged to maximize radiation delivery to tumor and minimize radiation delivery to organs and tissues at risk of injury from radiation.

Stereotactic Radiation

SRT includes both single-fraction and hypofractionated stereotactic techniques, referred to collectively as SRS in these NCCN Guidelines. Compared with brachytherapy and particle beam RT, there are fewer prospective comparative study data on SRS for treatment of primary uveal melanoma. Available data suggest that SRS may be as effective as other RT modalities, but may also be associated with a higher risk of complications. One series that compared SRS with iodine-125 brachytherapy found that rates of tumor recurrence, distant metastasis, and secondary enucleation were similar across treatments.³⁴⁴ Risk of cataract appeared similar across treatments, but SRS appeared to be associated with higher rates of certain complications, including neovascular glaucoma, radiation retinopathy, and radiation papillopathy.^{344,376} Another study also reported similar rates of local control with brachytherapy versus SRS.³⁶⁸ A retrospective study comparing ruthenium-106 brachytherapy versus SRS found a nonsignificant trend toward increased secondary glaucoma after SRS.³⁶⁴ A retrospective study comparing SRS versus proton beam RT reported similar rates of local control and eye retention across treatments, but higher rates of VA decline with SRS.³⁷⁷

Studies using SRS as primary treatment for uveal melanomas have reported local failure rates ranging between 2% to 16%.^{183,272,344,368,377-391} Rates of 5-year metastasis-free survival after SRS ranged from 69% to 84%.^{344,379,381,392} OS 5 years after SRS has been reported to be 55% to 98%.^{380,381,385,392,393} These large ranges likely reflect differences in the populations studied; thus, in the absence of randomized trial data it is



NCCN Guidelines Version 2.2021

Melanoma: Uveal

difficult to know whether these outcomes are better or worse than those reported for other treatment modalities.

In studies testing SRS as primary treatment for uveal melanoma, eye retention rates ranged from 73% to 98%.^{377,380,383-387,390,392-395} In addition to causing a decrease in VA, complications associated with SRS include cataracts, neovascular glaucoma, radiation retinopathy, radiation papillopathy, radiation maculopathy, hemorrhage, macular edema, optic neuropathy, and keratitis sicca (dry eye).^{344,376,379,380,382,383,387-389,395-399} Some studies have linked the rate and/or severity of complications to the radiation dose, tumor location, tumor size, and VA before treatment.^{382,384,387,397,400,401}

NCCN Recommendations for Stereotactic Radiation

Due to the lack of randomized prospective data (compared with other RT techniques described above), SRS is the least often used form of definitive RT for the treatment of primary or recurrent intraocular tumors. Like particle beam RT, SRS can be used to treat large choroidal melanomas. The choice between these two options generally depends on the radiation oncology facilities available. In rare cases when both particle beam RT and SRS facilities are available, some NCCN Panel members prefer particle beam RT because there are more supporting data for this approach. Tumor localization, fiducial marker use, and planning for SRS are generally consistent with particle beam RT approaches. Using fractionated SRS, 45 to 70 Gy in 2 to 5 fractions should be prescribed. Using single-fraction SRS, 18 to 45 Gy in 1 fraction should be prescribed.

RT Toxicity (Ocular)

In order to avoid secondary enucleation, a variety of methods for preventing or managing RT-associated complications have been tested in prospective studies. Toxicity management methods tested include panretinal photocoagulation for ocular ischemia,⁴⁰² transscleral local resection for exudative retinal detachment,⁴⁰³ and intravitreal anti-vascular

endothelial growth factor (VEGF) (eg, bevacizumab, ranibizumab, aflibercept) or intravitreal corticosteroids (eg, triamcinolone, dexamethasone) for treating optic neuropathy, macular radiation vasculopathy, or papillopathy or macular edema.⁴⁰⁴⁻⁴¹¹ These intravitreal therapies have also been tested for prophylaxis.⁴¹²⁻⁴¹⁴ The NCCN Guidelines for Melanoma: Uveal do not currently have recommendations for management of RT side effects.

Other Ablative Techniques

Laser Therapy

Laser Photocoagulation

Laser photocoagulation has also been used for treatment of primary or recurrent uveal melanomas, sometimes as monotherapy but more often as an adjunct to RT or surgery.^{45,46,171,277,281,415-430} The sparse data available suggest that laser photocoagulation is associated with high rates of recurrence if used as the sole primary therapy,^{415,421} but that when used as a supplement to brachytherapy can increase rate of tumor regression.⁴²⁶

Transpupillary Thermotherapy

TTT, also called diode laser hyperthermia, is a technique that uses a modified infrared diode laser to slowly heat up a specified area to approximately 45 to 60°C. TTT can be used to treat a large spot and has deep tissue penetration. TTT has been tested in prospective studies as the sole primary treatment for uveal melanoma tumors, but local recurrence rates varied widely across studies, with some studies reporting high rates of recurrence (>50%), even for small tumors.^{272,330,431-436} TTT has also been tested as an adjunct therapy to radiation (brachytherapy, proton beam RT, SRS or fractionated SRT) to reduce the risk of local recurrence.^{350,366,437-443} One prospective randomized trial found that TTT administered at 1, 6, and 12 months after proton RT reduced the likelihood of retinal detachment and lowered the secondary enucleation rate.⁴³⁸ A



NCCN Guidelines Version 2.2021

Melanoma: Uveal

retrospective study (n = 133) on matched groups found that addition of TTT to brachytherapy improved rate of tumor regression, 5-year tumor recurrence rate, eye-globe preservation, and recurrence-free survival.⁴⁴⁴ There was no impact on metastasis-free survival, OS, rate of complications, or visual outcomes.⁴⁴⁴ However, two other studies showed that adding TTT to brachytherapy did not improve the rate of globe conservation, and was associated with greater loss of VA.^{366,445} The larger of these studies (n = 449) also showed that rate of local failure, distant metastasis, and cause-specific death were not improved by TTT.³⁶⁶

Complications associated with TTT include retinal hemorrhage, vitreous hemorrhage, retinal vascular occlusions, optic disc atrophy, macular edema, retinal detachment, retinal traction, exudative serous neurosensory detachment, vitritis, and postoperative pain.^{433,446}

Cryotherapy

Use of cryotherapy for treatment of primary or recurrent uveal melanomas, either alone or in conjunction with other therapies, has been described in case reports and case series in the literature,^{435,447-453} and retrospective reports and review articles suggest that this method is occasionally being used in clinical practice.^{26,310,454}

Treatment for Extraocular/Extrascleral Extension

Extraocular/extrascleral extension has been reported to be present in approximately 3% of patients at diagnosis of uveal melanoma,^{166,173,200,455} is more common among tumors with higher T stage (12% of T4 tumors),²⁸⁵ and is associated with poor prognosis.^{18,26,284,456-458} Extrascleral/extraocular extension can be detected by preoperative imaging, or found or confirmed at the time of enucleation.^{294,459} Sometimes the evidence of extraocular extension is microscopically positive or close margins after enucleation, without clinical, intraoperative, or radiographic evidence of gross residual disease to the orbit. In other cases, extraocular tumor is visible

intraoperatively or intraoperative findings suggest that there may be gross disease to the orbit. In the COMS trial of patients with large uveal melanomas that tested enucleation with versus without pre-enucleation RT, unexpected extrascleral extension was found in 2% of patients who underwent enucleation, despite extensive clinical and imaging workup.^{294,301}

Orbital Exenteration

Orbital exenteration is surgical removal of the globe and adjacent orbital contents, for cases with extraocular extension and/or orbital invasion.^{41,185,196,422,425,460} Retrospective studies of large databases suggest that exenteration is used in less than 1% of patients,²⁶ and among patients undergoing enucleation, 2.5% need orbital exteneration.⁴⁶¹ The value of orbital exenteration is disputed in the literature, largely based on low-quality data such as case reports and retrospective studies. Some studies support orbital exenteration because it provided superior outcomes compared with other (nonsurgical) approaches,⁴⁶² whereas others report poor outcomes after orbital exenteration, arguing that it may not be justified.^{463,464}

Radiation Therapy for Extraocular/Extrascleral Extension

A retrospective study (n = 202) found that in patients treated with enucleation, postoperative RT improved survival, particularly in young patients (age <30 years) and those with choroidal tumor height greater than 3 mm.⁴⁶¹ Another retrospective study (n = 17) reported a local recurrence rate of 6% in patients with extrascleral extension who were treated with enucleation followed by adjuvant external beam RT to the orbit.⁴⁶⁵ For patients with limited extraocular extension less than 3 mm thick, brachytherapy may also be an option, as a retrospective study (n = 17) showed no intraocular or extraocular tumor relapse after a median follow-up of 63 months (range, 23–164 months).⁴⁶⁶



NCCN Guidelines Version 2.2021

Melanoma: Uveal

Treatment of Localized Uveal Melanoma

Following workup and staging, patients with localized uveal melanoma should be treated. Treatment options depend on the tumor size (diameter and thickness) and proximity to the optic nerve.

Tumor Size: Largest Diameter 5–19 mm and Thickness <2.5 mm

For thin tumors (<2.5 mm) with largest diameter ranging from 5 to 19 mm, the recommended primary treatment options are plaque brachytherapy or particle beam RT. For highly select patients who are not good candidates for brachytherapy or particle beam RT, other options to consider include laser therapy or enucleation.

Tumor Size: Largest Diameter ≤19 mm and Thickness 2.5–10 mm

Brachytherapy and particle beam RT are also options for treating tumors with largest diameter 19 mm or smaller and thickness 2.5 mm to 10 mm. If there is concern that adequate response was not achieved from initial RT, then further treatment should be considered. Recommended options for further treatment include laser therapy or cryotherapy. In highly select cases, resection is sometimes considered. Tumors in this size range may also be treated with enucleation. Although there is a trend toward avoiding enucleation, it is recommended for patients with neovascular glaucoma, tumor replacing greater than 50% of globe, or blind, painful eyes.

Enucleation should also be considered in cases of extensive extraocular extension.

Tumors Not Appropriate for Brachytherapy

Given the limitations in the size and RT penetrance of commercially available brachytherapy plaques (diameter ≤23 mm), this method is not appropriate (and not recommended) for tumors that are too large in diameter (>19 mm; any thickness), too thick (>10 mm; any diameter), or have optic nerve involvement and thickness (>8 mm; any diameter). RT options for such tumors include particle beam RT and SRS. The choice

between these two RT modalities usually depends on which modality is available at the treating institution. In the rare scenario that the institution has both SRS and particle beam facilities, some practitioners would opt for particle beam because there are more data supporting its efficacy. Enucleation is also a recommended option, especially in cases with extensive extraocular extension, neovascular glaucoma, tumor replacing greater than 50% of globe, or blind, painful eyes.

Additional Treatment Considerations

An essential feature of high-quality care is that clinical decisions are informed by a variety of case-specific factors (patient preferences and characteristics such as age, status of the other eye, disease characteristics, and medical history), such that for some patients the best clinical approach may not be one of the listed options. The recommended treatment options are largely based on data from choroidal melanomas. For small ciliary body and iris tumors (<3 clock hours), surgical excision may be considered.

Additional Primary Treatment for Extraocular Extension

For patients with limited extraocular extension, brachytherapy with scleral patch graft should be considered. For patients treated with enucleation for their primary tumor, additional treatment may be needed if extraocular extension is present. For patients with microscopically positive or close margins after enucleation, but no clinical, intraoperative, or radiographic evidence of gross residual disease to the orbit, recommended options include observation (no further treatment), mapping biopsy, and/or consideration of RT to the orbit (using particle beam or photon beam therapy). For patients with visible extraocular tumor or suspicion of gross disease in the orbit at the time of enucleation, biopsy of the extraocular tissue is recommended, if possible. Additional treatment options to consider include one or more of the following: intraoperative cryotherapy, orbital exenteration, and/or RT to orbit using particle beam or photon



NCCN Guidelines Version 2.2021

Melanoma: Uveal

beam RT. For photon or proton beam RT to the orbit (after enucleation), a dose of 20 to 30 Gy in 5 fractions should be prescribed to the clinical target volume at risk for recurrence^{294,467} using intensity-modulated or conformal techniques with image guidance.

Treatment of the Primary Tumor in Patients with Metastatic Disease

Palliative local therapy to the primary tumor may be considered in the setting of metastatic disease. In general, if the metastatic disease is being treated, the primary tumor should also be treated. Patients who present with advanced metastatic disease and limited life expectancy may elect to have no treatment to their primary tumor.

Follow-up

In order to make educated choices about monitoring and follow-up after treatment of the primary lesion, it is important for patients and treating clinicians to be aware of what is known about the typical trajectory of the disease, including the typical characteristics and time frame until presentation of treatment complications, recurrence, and metastasis. Monitoring should also be informed by consideration of a patient's risk for each of these outcomes.

For patients whose primary uveal melanoma was treated with RT or surgery, the subsequent disease-free interval is highly variable, ranging from a few months to many years.^{327,347,372,388,440,441,468} Uveal melanoma is characterized by early micrometastasis (often before treatment) followed by variable latency period before emergence of overt metastasis.⁴⁶⁹ Local recurrence is rare, occurring in less than 10% of patients after the primary lesion is treated using one of the modalities recommended in these guidelines.^{47,187,272,294,295,326,327,330,331,333,337,338,347,366,439,441,468,470,471}

Development of detectable distant metastatic disease is much more common than local recurrence, and develops in up to 70% of patients, depending on the stage and other risk factors at the time of

diagnosis.^{8,13,26,285} For example, large retrospective studies (n > 7000) found that after long-term follow-up the percent of patients who had developed metastasis was 20% for those with stage I at diagnosis, but ~70% for those with stage III at diagnosis.^{13,285}

Patterns of Local Recurrence

Due to the rarity of local recurrence, data characterizing local recurrences are somewhat limited. The likelihood, typical time frame for development, location, and risk factors for local recurrence may depend on whether the patient received primary treatment with enucleation or some form of radiation (ie, brachytherapy, particle beam, SRT).

Local Recurrence After Enucleation

Local recurrence after enucleation for localized primary melanoma is extremely rare, occurring in only ~1% of patients, and presents as tumor growth in the orbit.^{294,295,471} In the COMS randomized controlled trials (for medium and large tumors), the few patients who developed local recurrences after enucleation all had distant metastases before the local recurrence developed.²⁹⁴ Retrospective studies reported similar findings, suggesting that development of distant metastasis is due to micrometastasis that developed prior to enucleation.⁴⁷¹ The rarity of the event precludes meaningful evaluation of risk factors for local recurrence after enucleation.

Local Recurrence After Radiation (Brachytherapy, Particle Beam RT, or Stereotactic RT)

In prospective trials reporting on patients who received brachytherapy as primary treatment for localized uveal melanoma, tumor regression was observed in most cases (97%–98%),^{330,367} and occurred over the first 2 years after treatment.³⁶⁷ Prospective studies have reported local failure rates ranging from 0% to ~20% for patients with localized primary uveal melanoma treated with brachytherapy with iodine-125 or other types of plaques (ruthenium-106, palladium-103, cesium-



NCCN Guidelines Version 2.2021

Melanoma: Uveal

131).^{47,187,326,327,330,331,333,337,338,347,366,439,441,468,470} Most of these studies reported local failure rates less than 10%, and a systematic review that included more than 3000 patients from 22 studies, including retrospective studies, found that the weighted mean rate of local failure after brachytherapy was 9.45%.²⁷² Prospective studies have reported that local recurrence after brachytherapy, although rare, occurs over a wide time range.^{47,187,327,366,440,441,468} Whereas some studies report median time to local recurrence between 2 and 4 years,^{327,440,441,468} most also show curves that never really plateau, due to late recurrences developing throughout long-term follow-up, as late as 12 years or more after treatment.^{47,187,327,366,440,441,468}

A variety of risk factors for local recurrence have been identified. Although results vary across studies, multiple analyses have found that tumor size and location are associated with risk of local recurrence after brachytherapy.^{47,187,347,366,441,468} Regarding primary tumor location as a risk factor, prospective studies have found higher risk of local recurrence associated with ciliary body involvement, epicenter location in the macula, proximity to the foveal avascular zone, proximity to the optic nerve, and extension under the foveola.^{47,187,347,441,468} One large prospective study reported that presence of visual symptoms at the time of uveal melanoma diagnosis was correlated with higher risk of local recurrence after brachytherapy.³²⁷ Several studies have shown that local recurrence is at least mildly associated with a higher risk of melanoma-related death.^{187,327}

For patients with primary uveal melanoma treated with particle beam RT, local recurrence rates ranged from 3% to 10% across studies.^{272,370} Tumor regression following particle beam RT can begin within 6 months of treatment, and tumor shrinkage may continue to occur throughout 5 years of follow-up.^{370,472} As with brachytherapy, local recurrence after particle beam RT as treatment for primary localized uveal melanoma occurs over a long time range, as early as 2 months after treatment and as late as 12

years.^{372,416,473} Prospective studies have found that most local recurrences occurred in the first 4 to 5 years, with median time to recurrence of less than 2 years.^{47,372,416,473} Primary tumor size and ciliary body involvement were shown to be independent risk factors for local recurrence in a multivariate analysis of results from a large prospective observational study of patients who received particle beam RT as primary treatment for uveal melanoma.⁴⁷³ Local recurrence after particle beam RT has been shown to be associated with an increased risk of metastasis and increased risk of death from metastatic uveal melanoma.^{372,473}

Studies using SRT as primary treatment for uveal melanoma have reported local failure rates ranging between 2% to 16%.^{183,272,344,368,377-390} This large range likely reflects differences in the populations studied. Following SRT of the primary tumor, prospective studies found that many uveal melanomas showed a transient increase in tumor height, volume, or both.³⁸³ Responses to SRT first began to appear 6 months after treatment, with progressive decreases in tumor height and volume continuing for at least 3 years.^{183,379,384,388,389} Prospective follow-up showed that the fraction of patients with response or stable disease increased during the first year after treatment.^{183,389} Prospective studies have found that following SRT there is a small percentage of patients with persistent tumor growth, which can occur soon after treatment (failure to achieve local control) or after a period of local control, and some studies reported recurrences many years after treatment.^{381,383,387-390,396} The few prospective studies that have attempted to identify risk factors for tumor growth after SRT have not found any correlation between RT dose or tumor diameter before treatment.^{379,388} There are some prospective data that suggest that local recurrence after SRT may be correlated with poorer survival.³⁸⁰

For all of the above RT modalities (brachytherapy, proton beam RT, and SRT), prospective studies have reported that tumor growth after treatment occurred at the margins of the treated area for some patients, but for other



NCCN Guidelines Version 2.2021

Melanoma: Uveal

patients appeared as tumor growth in all dimensions, including growth within the treated volume.^{347,370,373,383,389,416,468,473}

Patterns of Treatment Complications

Complications After Enucleation

For patients treated with enucleation for primary uveal melanoma, complications between 1 to 6 weeks after surgery included pain requiring longer hospital stay, pain requiring medication, conjunctival wound dehiscence, infection, decreased facial sensation, eyelid swelling, inflammation, implant displacement, hair loss, ptosis, conjunctival chemosis, ecchymosis, and orbital or conjunctival hemorrhage.²⁹⁴ Long-term follow-up showed that other problems include poor motility of prosthesis, poor alignment of prosthesis, severe ptosis, and displacement of implant.²⁹⁴ Enucleation is also associated with loss of certain visual functions, such as peripheral vision, night driving, and judging distances.^{316,317,319}

Complications After Brachytherapy

Effects on Visual Acuity

Prospective studies of patients treated with brachytherapy for uveal melanoma have shown that VA in the treated eye tends to steadily decrease during at least the first 5 years of follow-up, both in terms of severity and the percent of patients with poor vision.^{186,331,334,335,347,366,468} Studies with long-term follow-up (>10 years) showed that the percent of patients with poor VA increases more slowly between 10 and 15 years after brachytherapy, and one study reported a median time to VA score (VAS) less than or equal to 50 of 39 months.^{334,468} Factors associated with loss of VA or poor vision outcomes included greater baseline tumor apical height, shorter distance between the tumor and the foveal avascular zone, ciliary body involvement, presence of tumor-associated retinal detachment, non-dome-shaped tumor, and patient history of diabetes.

Results from multiple prospective studies suggest that risk of poor vision outcomes depends on baseline tumor thickness and location.^{186,331,334,335,347,366,468} Locational elements suggested to be associated with increased risk of poor vision include juxtapapillary location, proximity to foveola, optic nerve or optic disc, ciliary involvement, central tumor location, mid-choroid and macula location, and retinal invasion. Some prospective studies have suggested additional risk factors for poor vision outcomes, including baseline VA, patient age, diabetes, baseline tumor shape, retinal detachment at baseline, and development of radiation maculopathy or radiation optic neuropathy.^{186,335,366,468}

Cataracts

Prospective studies have reported that following treatment with brachytherapy for uveal melanoma, the percent of patients with cataracts in the treated eye steadily increases over the first 5 years of follow-up. Cataracts may affect more than two thirds of patients by 5 years, although a much smaller number of patients underwent cataract surgery.^{329,468} In the COMS trial, median time to development of cataract was 2.5 years, and the median time to cataract surgery was 3.5 years.³²⁹ Cataract surgery resulted in VA improving by two or more lines in 66% of patients, and stabilizing in 26%.³²⁹ Older age, larger baseline tumor size, and higher radiation dose may be risk factors for development of cataract after brachytherapy.³²⁹

Other Serious Complications

Treatment of uveal melanoma with brachytherapy can result in a variety of radiation-related complications in the treated eye, or can worsen conditions initially caused by the uveal tumor.^{336,441,468} Examples of more serious complications include radiation retinopathy, optic neuropathy, papillopathy, maculopathy, neovascular glaucoma, retinal detachment, and various types of hemorrhages and vascular abnormalities.^{331,336,468} Prospective studies have found that the development or worsening of



NCCN Guidelines Version 2.2021

Melanoma: Uveal

complications typically occurs during the first 5 years after treatment, although the time frame for development may differ slightly between specific types of complications.^{336,468} These complications occasionally develop more than 5 years after treatment, especially in patients who had large tumors prior to treatment.⁴⁶⁸

Enucleation

Prospective studies of patients treated with brachytherapy for uveal melanoma have found that up to 40% of patients needed enucleation during follow-up, either due to treatment failure, loss of VA, or complications.^{47,186,187,303,366,468} The rate of enucleation after brachytherapy was lower in some studies that included only patients with smaller tumors at baseline.^{187,366} In these studies the cumulative rate of enucleation increased gradually over a long period of time, at least 15 years after follow-up.^{47,186,187,437,468} The need for enucleation at late time points reflects that local recurrences can occur many years after treatment,^{47,187,327,366,440,441,468} that VA can persistently decline over many years,^{186,331,334,335,347,366,468} and that some complications have a long time to onset and/or gradually worsen over many years.^{329,336,468} Studies with long-term follow-up reported that approximately half of the enucleations were due to local treatment failure, and the other half were due to complications or poor VA.^{47,187,468} Complications that lead to secondary enucleation included neovascular glaucoma, retinal detachment, vitreous hemorrhage, and ocular pain.^{187,468} Results from the COMS study in medium-sized tumors suggest that enucleations at early time points were more often caused by local treatment failure, whereas enucleations at later time points were more often caused by complications or poor VA.¹⁸⁷ Factors that may be associated with increased risk of enucleation include the following baseline features (prior to primary treatment): increased primary tumor thickness, proximity to foveal avascular zone, anterior location, and epithelioid cell type; poorer VA; and younger age.^{187,366,468}

Complications After Particle Beam RT or Stereotactic RT

Effects on Visual Acuity

Prospective studies of patients with uveal melanoma have reported steadily declining VA in the treated eye following proton RT or SRT, both in terms of the percent of patients with poor VA and in terms of the mean VA across the whole patient population.^{183,347,379-381,383,384,387,388,473} This decline was observed throughout the duration of follow-up, which was up to 5 years in these studies. Some of these studies suggest increased risk of declining VA after proton RT or SRT for patients with low baseline VA, increased radiation dose to optic nerve, and posterior tumor location.^{379,380} Time to loss of VA may be longer for patients treated with lower doses.³⁸⁸

Other Complications

Following particle beam RT for primary uveal melanoma, toxicities reported in prospective studies include vitreous hemorrhage, subretinal exudation in macula, posterior subcapsular opacity, radiation keratopathy, rubeosis/neovascular glaucoma, retinal detachment, radiation maculopathy, and papillopathy.^{370,373,438} Eyelash loss and low-grade dermatitis are common short-term toxicities that develop soon after treatment.^{347,474,475} Whereas development of retinal detachment or neovascular glaucoma rarely occurs beyond 2 to 4 years after treatment,^{373,438} development of RT maculopathy and RT papillopathy may occur beyond 5 years of follow-up.⁴⁷³ Results from prospective studies suggest that risk of RT maculopathy may depend on the distance between the tumor and the macula, whereas RT papillopathy and neovascular glaucoma may be related to proximity to the optic disc.^{373,473} Increased tumor size and larger irradiated volumes of critical normal eye structures may also be associated with increased risk of neovascular glaucoma.³⁷³

Prospective studies have reported a wide variety of complications associated with SRT treatment of primary uveal melanoma. Alopecia and eyelash loss typically develop within 1 year of treatment, and have been



NCCN Guidelines Version 2.2021

Melanoma: Uveal

reported to occur in less than 10% of patients, although much higher rates were observed in patients with large primary tumors.^{183,384,387,399} Doses high enough to cause alopecia can also cause dermatitis, another early, transient, mild toxicity associated with SRT.^{387,399} Fatigue, pain, and dry eye may also occur after SRT.^{183,379,380,387} Fatigue and pain typically occur soon after treatment, and then abate.¹⁸³ Dry eye also typically occurs soon after treatment (median time to onset 6 months), but can occur much later (range 3–60 months), and can be severe and/or persistent.^{183,379,387}

Baseline tumor size (base diameter and height) and higher dose to the lacrimal gland may increase risk of dry eye.^{379,387} Uveitis has been reported to develop between 6 to 52 months after SRT, occurring in less than 15% of patients, although larger tumor volume may increase the risk of uveitis.^{379,384,387,399} Diseases of the lacrimal drainage system tend to have late onset, occurring between 1 to 4 years after treatment, and usually occur in less than 10% of patients.^{387,399} Mild iritis has been reported after SRT for tumors with ciliary body involvement.³⁸³ Conjunctival problems (such as hyperemia, irritation, tears, and chemosis) are typically mild, mostly occur within 6 months of treatment, and usually resolve.¹⁸³

Corneal epithelial defect and corneal ulcer have been reported in up to 30% and up to 10% of patients, respectively, and can develop between 6 months and 5 years after SRT treatment for uveal melanoma.^{384,387,389,399} These corneal complications can be serious, and some studies suggest that risk of corneal damage may increase with increasing dose and increasing tumor diameter.^{382,384,399}

SRT can cause or worsen exudative retinal detachment, but some cases of retinal detachment prior to treatment were unchanged or resolved after treatment.^{183,379,383,384,387} One study reported resolution of over half of the cases with retinal detachment at baseline, with a median time to resolution of 15.7 months.³⁸⁷ Increased patient age and tumor size may be

associated with increased risk of retinal detachment.^{379,384} Various types of hemorrhage, including vitreous hemorrhage, subretinal bleeding, retinal hemorrhage, cutaneous bleeding, and subconjunctival hemorrhage, have been reported following SRT.^{183,379,380,384} Most of these bleeding events are mild and resolve.^{380,384} Vitreous hemorrhage has been reported in 10% or less of patients, can be more severe, and may develop between 3 to 48 months of follow-up, with a median time to development of 15 months.^{379,380,384}

SRT can also cause or worsen cataracts, which can be severe and may require surgery.^{183,379,380,382-384,387,389,399} Cataract development after treatment occurs over a wide time range (3–100 months), with one study reporting a mean time to development of 19.6 months, and another reporting a median time to development of 12 months.^{183,379,387,389,399} Prospective studies suggest that risk factors for cataract development after SRT may include advanced age, ciliary body involvement, larger tumor size, larger PTV, larger RT dose, and larger dose to the lens and ciliary body.^{379,382,384,399}

Secondary glaucoma, including neovascular glaucoma, has been observed in multiple prospective studies of patients treated with SRT.^{183,379,380,382,384,387,389,396,399} Neovascular glaucoma may be mild or severe, and may affect more than 25% of patients.^{379,380,384,387,399} Neovascular glaucoma typically has late onset, developing between 5 months and 10 years after treatment, with one study reporting median time to development of 30 months.^{379,380,387,389,396,399} Results from prospective studies agree that greater tumor height (at baseline) is a risk factor for neovascular glaucoma, but differ regarding whether greater RT dose is associated with greater risk.^{379,382,384,387,399}

Retinopathy has been reported to occur in up to two thirds of patients treated with SRT, and may be mild or severe.^{183,379,380,383,384,387,389,399} Retinopathy typically has delayed onset, and has been reported to



NCCN Guidelines Version 2.2021

Melanoma: Uveal

develop between 5 to 110 months, with one prospective study reporting a mean time to development of 15 months, and another reporting a median time to development of 24 months.^{183,379,380,383,387,389} Development of optic neuropathy after SRT has been observed in multiple prospective studies, may occur in up to 40% of patients, and can be severe.^{183,379,380,382,384,387,389,399} Optic neuropathy typically has delayed onset, and has been reported to develop between 4 months and 9 years after treatment, with a mean time to development of 21 months.^{183,380,384,387,389,399} Prospective studies have suggested a variety of risk factors for optic neuropathy, including larger tumor size, tumor stance to the optic disc, higher total RT dose, higher dose to the optic nerve, the ratio of gross tumor volume (GTV) to PTV, or the distance from PTV to the optic nerve.^{379,384,387,399} SRT can also cause optic disc edema, which is often severe, develops between 1 to 2 years after treatment, and has a median time to development of 18 months.³⁷⁹

Enucleation

Prospective studies have found that secondary enucleation was sometimes needed due to local recurrence or complications in patients with primary uveal melanoma treated with proton RT or SRT.^{47,373,379,380,384,387,388,396} Among cases of enucleation due to complications, neovascular glaucoma was the most common cause; others included angle closure glaucoma, tumor necrosis syndrome, corneal ulcer, retinal detachment, and pain, sometimes due to elevated intraocular pressure.^{47,373,380,384,387,388,396} These secondary enucleations occurred over a wide time range, from 2 months to greater than 10 years after treatment.^{47,373,384,389,438,476} Although most enucleations occurred within 5 years of treatment, the risk of enucleation between 5 to 10 years after treatment is non-negligible.^{47,388,389,396,438,476} Larger tumor size, proximity to the optic disc, high intraocular pressure, or retinal detachment before treatment may increase the risk of secondary enucleation after proton RT.⁴⁷⁶

Surveillance Methods for Local Recurrence or Complications

To monitor for local recurrence and possible complications after treatment of the primary tumor in patients with uveal melanoma, prospective studies have followed patients with regular clinical and ophthalmologic exams.

For patients treated with enucleation in the COMS trial, there were follow-up exams at 1 to 2 weeks after surgery to assess healing status, and at 6 months, 12 months, and annually thereafter, in which the eye socket and eyelids were examined for possible recurrence or complications, and the fit of prosthesis checked.^{301,303,477}

For patients treated with RT (brachytherapy, particle beam RT, or SRT) in prospective studies, follow-up exams typically included complete ophthalmologic exam of the treated eye, with indirect ophthalmoscopy, slit-lamp exam, tonometry, color fundus photography, A-scan and B-scan US, and measurement of VA and visual field.^{47,183,186,187,327,330,331,333,335,347,366,367,370,380,383,384,387-389,396,437,439,440,468,472,473,477-479} Many prospective studies also included fluorescein angiography in follow-up exams, either at regular intervals or as needed.^{47,187,330,333,335,336,347,366,384,388,389,439,478} A few prospective studies used gonioscopy,^{187,388} OCT,^{335,366,437} or MRI.^{383,396} For most prospective studies following patients with primary uveal melanoma treated with RT, data taken at regular intervals included VA, intraocular pressure, tumor dimensions and shape, development of new extrascleral growth, orbital or ciliary body mass, and retinal invasion, pathologic changes, changes in tumor appearance, and patient symptoms (ie, ocular pain, vision problems).^{183,186,187,303,331,333,335,367,370,373,380,384,387-389,440,472,479} Some studies monitored for changes in tumor reflectivity or tumor vascularity as signs of regrowth/recurrence.^{366,367,396,472}

The frequency of follow-up exams after RT (brachytherapy, particle beam RT, or SRT) varied across studies. For patients who were treated with



NCCN Guidelines Version 2.2021

Melanoma: Uveal

brachytherapy in the COMS study, follow-up included an exam within 6 weeks of surgery, at 6 months after treatment, then every 6 months for 5 years, and every 12 months thereafter.³⁰³ Patients with suspected tumor growth had more frequent follow-up exams. Whereas some prospective studies in patients treated with brachytherapy had follow-up protocols similar to COMS,^{327,331,367} others used more frequent follow-up, with more than 2 exams per year during the first year or first few years after treatment, and exams every 6 to 12 months during later years.^{47,330,333,334,347,439-441,468,479} Prospective studies following patients after particle beam RT or SRT for primary uveal melanoma sometimes had frequent follow-up during the first 6 months after treatment (eg, 3–5 exams in the first 6 months),^{183,375,379,380,383,384} and most had follow-up exams at least every 3 to 4 months during the first year or two.^{47,183,347,373,379,384,387-389} A few studies switched to the 6-month follow-up interval starting early (<1 year) from treatment.^{370,375,380,396,472,478} Long-term follow-up intervals ranged between 4 to 12 months.^{47,183,347,370,373,375,379,380,383,384,387,388,396}

Because some patients treated with RT may have an increase in tumor size before regression, studies have defined local recurrence in terms of specific thresholds for growth. For example, the COMS trial defined local treatment failure (after brachytherapy) as one or more of the following: increase in height of $\geq 15\%$ by echography or a ≥ 250 -um expansion of any tumor boundary by photographs or clinical examination followed by an additional $\geq 15\%$ increase in elevation or a further ≥ 250 -um expansion of any tumor boundary observed and confirmed on subsequent examination; extrascleral extension based on clinical or echographic findings; or development of orbital mass, ciliary body mass, or retinal invasion.¹⁸⁷ Similarly, prospective studies following patients after SRT have used definitions of tumor recurrence that include tumor growth rate above a specific threshold that is confirmed over two exam intervals, usually based on US measurements.^{183,373,387,388,396}

Follow-up for the Treated Eye

At NCCN Member Institutions, standard follow-up in the affected eye includes imaging with color fundus photography and ultrasonography every 3 to 6 months for 3 to 5 years, then every 6 to 12 months thereafter, if stable. The frequency of follow-up should depend on the size and location (eg, juxtapapillary location, ciliary body involvement) of the tumor at presentation, as these factors impact the risk for recurrence.

Risk in Contralateral (Fellow) Eye

In patients who have received treatment for primary unilateral uveal melanoma, disease can develop in the contralateral eye, but the incidence is very low. In the COMS trials of patients with medium or large primary uveal melanoma tumors, prospective monitoring showed that less than 1% of patients developed disease in the contralateral eye during follow-up after primary treatment.^{295,480,481} Moreover, for the majority of patients who did not develop disease in the contralateral eye, results from regular ophthalmologic exams showed that good VA was retained in their fellow eye throughout the 10 years of follow-up, regardless of the modality used to treat the primary lesion (brachytherapy, enucleation, or RT followed by enucleation).⁴⁸² Analysis of 8165 patients with ocular melanoma in the SEER database found bilateral involvement in 0.1% of patients.¹⁰ One retrospective study of 52 cases of bilateral uveal melanoma suggests prognosis in these cases is similar to that of unilateral cases.⁴⁸³ Additional cases of uveal melanoma metastasizing to the contralateral eye are described in case studies.⁴⁸⁴⁻⁴⁹²

NCCN Recommendations for Follow-up for the Contralateral Eye

All patients should receive follow-up for the affected eye. In patients with uveal melanoma, the contralateral eye is not at increased risk of uveal melanoma,^{10,295,480,481} and can be followed with routine ophthalmologic care.



Patterns of Metastases

Most uveal melanomas are localized at first presentation, and only a small percentage of cases (<3%) have detectable metastatic disease at the time of diagnosis.^{6,10-14,166,493} Development of distant metastatic disease is much more common, occurring in ~20% to 70% of patients within 20 years after treatment for primary uveal melanoma, depending on stage/size and genetic characteristics of the tumor at diagnosis.^{8,13,26,48,67,285} Prospective studies with long-term follow-up (≥5 years) after treatment of primary uveal melanoma have shown that the cumulative rate of development of distant metastatic disease steadily increases over many years of follow-up.^{47,331,347,366,372,379,381,387,388,440,441,468,473,480,481} For example, in the COMS studies in which patients with medium tumors were treated with brachytherapy or enucleation, and patients with large tumors were treated with enucleation with or without RT prior to surgery, the Kaplan-Meier estimates of 2-, 5-, and 10-year metastasis rates were 10%, 25%, and 34%.⁴⁸¹ Although incidence rates declined after the 2-year examination, and most cases of distant metastatic disease developed within 90 months of treatment, new cases of distant metastatic disease were detected at every 6-month interval over the 12-year follow-up period.⁴⁸⁰ Although the proportion of patients who developed distant metastasis differed depending on the primary tumor size prior to treatment, the cumulative incidence curves (proportion of patients with metastasis) for both medium and large tumors did not appear to be plateauing even after 10 years of follow-up.^{480,481} Similar findings have been reported for other prospective studies monitoring for development of distant metastatic disease after primary treatment with brachytherapy,^{331,366,440,441,468} particle beam RT,^{47,347,372} or SRT.^{384,387,388} These studies found that the proportion of patients with metastasis increased between all consecutive time points (eg, Kaplan-Meier estimates at 1, 2, 3, 5, 7, 8, 10, and 15 years).^{47,331,372,384,387,388,440,441,468} In these studies the development of metastatic disease occurred as early as 4 months and as late as 14 years after treatment of primary uveal melanoma,^{347,372,381,468} developing

continuously throughout the follow-up period such that cumulative incidence curves and disease-free survival curves did not appear to be plateauing even after 6 to 20 years of follow-up.^{47,366,388,440,468} Although difficult to calculate due to ongoing development of distant metastatic disease, several studies reported mean and median times to first distant metastasis (for those who developed distant metastasis), which ranged from 39 to 45 months, and from 35 to 37 months, respectively.^{347,372,388,468}

Sites of Metastasis

Uveal melanoma most often metastasizes to the liver.^{19,21,22,166,295,480,481,494-501} Of those with distant metastasis, greater than 90% have liver metastases.^{295,480,481} For patients with only one metastasis at the time that distant metastasis is first detected, most have liver metastasis.^{19,21,22,295,497} Other common sites of metastasis, listed in order of decreasing prevalence, are lung, bone, skin/soft tissue, and lymph nodes.^{11,21,166,295,373,379,480,481} In large prospective studies following patients after treatment for primary uveal melanoma, metastasis to the lung was observed in 20% to 30% of patients who developed distant metastasis, to the bone in 16% to 18%, to skin/soft tissue in 11% to 12%, and to lymph nodes in 10% to 11%.^{295,480} Retrospective studies show similar trends.^{21,501} A few studies reported brain metastases in 4% to 5% of patients who developed distant metastases.^{21,295,480} Most patients who develop metastasis ultimately have multiple sites involved.^{295,480}

Risk Factors for Metastasis

Numerous studies have evaluated factors prognostic for development of distant metastasis or for shorter time to development of distant metastasis. Although the AJCC staging system is based on survival data from large epidemiologic studies,^{12,13,18} characteristics used for AJCC staging have also been shown to be prognostic for development of distant metastasis. In the AJCC staging system for melanomas arising in the choroid or ciliary body, T stage is based on the largest basal diameter and thickness of the



NCCN Guidelines Version 2.2021

Melanoma: Uveal

primary tumor, as well as the presence or absence of ciliary body involvement and presence and size of extraocular extension.³¹ Multiple prospective studies and several large retrospective studies (N > 1000) have shown by multivariable analysis that primary tumor diameter and/or thickness is associated with risk of metastasis after primary treatment.^{91,324,347,372,456,468,502} Several retrospective studies on large patient populations have found that risk of metastasis is correlated with AJCC T stage and with AJCC staging.^{8,13,284,501,503-507}

Primary uveal melanomas can contain spindle cells, which have ovoid nuclei and tend to grow in a compact fashion, and epithelial cells, which are larger, more irregularly contoured, pleomorphic, and contain abundant cytoplasm, larger nuclei, and nucleoli.³¹ The cell types present in the primary lesion have been linked to risk of metastasis. One prospective and several retrospective analyses have found that the histologic cell type(s) in the primary tumor can be prognostic for metastasis, in that patients whose primary tumor contains epithelioid cells (either entirely or mixed with spindle cells) are more likely to develop metastases than those who have only spindle cell type.^{67,257,501,502,506,508-510} The presence of spindle versus epithelioid cells in the primary tumor had been used as a prognostic factor to inform frequency of follow-up after primary treatment, but this prognostic feature is now considered less important than other tumor features and molecular markers. Lack of concordance among pathologists makes implementation of risk stratification by histopathology difficult.

In addition to AJCC T stage and tumor histology, multiple tumor molecular markers have been shown to be associated with increased risk and/or shorter time to development of distant metastases. Chromosomal changes were among the first molecular markers to be found to be associated with risk of distant metastasis in patients with uveal melanoma.⁵⁰⁸ Multiple studies have found that monosomy 3 and gain of chromosome 8q, especially when numerous copies are found, in the primary uveal

melanoma is associated with increased risk of metastasis.^{24,36,48,67,324,509-525} Risk of metastasis is even higher when both of these abnormalities are present.^{24,67,513,516,518,522} Some studies have identified additional chromosomal abnormalities associated with increased risk of metastasis, such as loss of 8p,^{24,513,515,516,518} loss of 1p,⁵¹⁸ loss of 16q,⁵¹³ and loss of 6q.²⁴ Gain of 6q may be protective against metastasis,⁵¹⁸ at least in the context of monosomy 3 and gain of 8q.²⁴

A method of using gene expression profiling (GEP) has been developed as a prognostic tool for uveal melanoma.⁵²⁶⁻⁵²⁸ These methods have been used to sort tumors into two classes, showing that class 2 was associated with higher risk of metastasis than class 1.^{48,252,502,503,512,521,529-535} Multivariate analyses have found that class 2 is associated with a 5-fold to 20-fold higher risk of metastasis than class 1.^{48,502,531,534,535}

Mutation and expression of certain specific genes have also been associated with risk of metastasis in patients with uveal melanoma. Multiple studies have found that *BAP1* mutation/deletion (observed in approximately half of uveal melanomas) and loss of *BAP* expression in the primary tumor is associated with increased risk of metastasis.^{36,72,504,506,521,523,532,536,537} One study showed that risk of metastasis is highest with *BAP1* somatic mutation, although also somewhat elevated in patients with *BAP1* germline mutation (compared with wild-type).⁵¹⁹ Other studies found that *BAP1* mutation was associated with early metastasis (after treatment of primary uveal melanoma).^{538,539} Mutation in *EIF1AX*, found in up to 20% of uveal melanomas,^{36,510,532,540} has been associated with lower risk of distant metastasis in patients with uveal melanoma.^{506,538,539} Some studies have found that *SF3B1* mutation, which is present in approximately 20% of uveal melanomas, was associated with lower risk of metastasis,^{36,73} while others found that patients with this mutation developed late metastases.^{506,538,539} PRAME



NCCN Guidelines Version 2.2021

Melanoma: Uveal

expression, present in about a third of uveal melanomas,^{503,541} has also been associated with increased risk of metastasis.^{503,533}

Surveillance Methods for Distant Metastatic Disease

There are very little data to inform the frequency and modality of follow-up screening for development of metastatic disease. Prospective studies following patients after treatment for localized primary melanoma have typically monitored for development of distant metastasis using regular follow-up visits including complete cancer-oriented physical exams and one or more of the following: chest x-ray, liver US, and serum liver function tests (LFTs).^{47,301,327,330,347,366,367,380,384,388,478,480} Liver US and LFTs were often included as part of routine follow-up because the liver is the most likely site of distant metastasis.^{19,21,22,166,295,480,481,497} Most of these prospective studies followed patients with physical exams, imaging, and blood tests every 6 months for at least the first 5 years.^{47,327,330,347,366,367,380,384,388,478,480} In real-world clinical practice, there are regional differences in the preferred methods and frequency of follow-up screening for metastatic disease in patients with uveal melanoma.⁵⁴²

For most of the prospective studies that monitored for development of distant metastatic disease after treatment of primary uveal melanoma, the total number of patients who developed distant metastases was too small to produce meaningful results regarding the sensitivity and specificity of different surveillance modalities. The COMS trials for patients with medium and large tumors were the largest of these prospective studies, and included cancer-oriented physical exams, chest x-ray, and LFTs as part of routine follow-up.⁴⁸⁰ Elevated LFTs (aspartate aminotransferase [AST] >2x the upper limit of normal [ULN]; alanine transaminase [ALT] >2x ULN; alkaline phosphatase [APH] >1.5 xULN, bilirubin [BIL] ≥2.0 mg/100 mL) were confirmed by repeat LFT testing, and further diagnostic testing, such as biopsy and CT/MRI/US of the liver were used to confirm or rule out distant recurrence.^{480,481} These trials measured LFTs at 6, 12, and 18

months after treatment, and then annually thereafter.⁴⁷⁷ Using this approach, the likelihood of an abnormal LFT was low (<1%).⁴⁸⁰ Based on all patients with reported metastasis, the sensitivity, specificity, positive predictive value, and negative predictive value associated with at least one abnormal LFT before first diagnosis of metastasis at any site was 14.7%, 92.3%, 45.7%, and 71.0%, respectively. Of the LFTs, APH had the highest diagnostic attributes. Other diagnostic tests appeared to have higher sensitivity and specificity because they were often triggered by abnormal LFTs. The results suggest that use of LFT results followed by other diagnostic tests has high specificity and predictive values, but low sensitivity.⁴⁸⁰ Whereas 739 patients had distant metastases detected during follow-up, 13 did not have their metastasis discovered until time of death.⁴⁸¹ The utility of LFTs for early detection of liver metastases is an issue of ongoing debate, with sensitivity, specificity, and positive and negative predictive values varying across specific LFT test types and differing between studies.^{496,497,499,543-547} Whereas some analyses have concluded that LFTs are among the most useful methods for screening,^{496,543-545,548,549} others argue that the specificity and sensitivity of these tests is too low to warrant routine use.^{499,500,547}

The optimal strategy for imaging surveillance is also an issue of debate, because for each of the methods commonly used (ie, chest x-ray, CT, US, MRI, PET/CT) results vary, and for all of these options there is at least one study that reported poor performance on at least one metric.^{496-500,544,546,550-560} Due to the low probability of metastasis at any specific time point, the yield of all these tests is low, and there is concern regarding cumulative radiation exposure due to the long-term follow-up needed.⁵⁶¹ Therefore, imaging is usually focused on the liver, as it is the most likely site of distant metastasis, and liver US and MRI are favored over CT or PET/CT. Some studies have found MRI to be moderately better than CT or PET/CT for detection of liver metastases from uveal melanoma,^{550,554,555} and



NCCN Guidelines Version 2.2021

Melanoma: Uveal

prospective studies in high-risk patients showed promising results for using liver MRI for early detection of liver metastases.^{500,556}

The value of surveillance imaging and tests is debated because it is unclear whether early detection of distant metastases improves outcomes, especially given that most treatments for distant metastatic disease are relatively ineffective. Some retrospective studies found that survival was better for patients whose distant metastases were asymptomatic at the time of detection,^{495,562} whereas other studies observed no such correlation,^{21,563} or reported that the difference was transient.⁵⁶⁴

Risk of Developing Secondary Cancers During Follow-up

Due to the long-term surveillance needed for detection of distant metastatic disease in patients with uveal melanoma, it is not uncommon for screens to identify other primary cancers.^{11,159,160,162,559,565-568} The two COMS randomized trials in patients with medium to large primary uveal melanomas showed that the proportion of patients with secondary cancers increased steadily over the entire duration of follow-up (median 10 years, range 5–16 years).⁵⁶⁶ Various types of secondary malignancies were observed.^{159,566} Uveal melanoma may increase the risk of developing other cancers,¹⁶⁰ especially in patients with familial uveal melanoma or other familial cancers.^{113,114}

Follow-up for Distant Metastasis

Given the lack of high-quality data to inform the frequency or modality of follow-up screening for distant metastatic disease, the NCCN recommendations are based on clinical practice at NCCN Member Institutions. Patients with no evidence of disease (NED) after treatment for uveal melanoma should be followed for signs of metastatic disease. The most frequent sites of metastasis are liver, lungs, skin/soft tissue, and bones. Recommended follow-up for distant metastatic disease includes imaging to evaluate signs or symptoms of distant metastasis, and may

include regular surveillance imaging. LFTs may be considered as a component of follow-up visits, although some studies showed poor sensitivity for early detection of liver metastases.

Recognizing that there are limited options for systemic recurrence and that regular imaging may cause patient anxiety, patients should discuss with their treating physician the potential benefits and risks of surveillance imaging, and some patients may elect to forgo surveillance imaging. Providers may also want to discuss mental health resources with patients. See the NCCN Guidelines for Survivorship (www.NCCN.org). Participation in a clinical trial is strongly encouraged.

For patients who elect to have surveillance imaging to screen for distant metastatic disease, options include contrast-enhanced MR or US of the liver, with modality preference determined by expertise at the treating institution. Additional imaging modalities may include chest/abdominal/pelvic CT with contrast, or dual-energy subtraction chest x-ray. However, screening should limit radiation exposure whenever possible. Scans should be performed with IV contrast unless contraindicated. Recommendations for imaging modality are based on clinical practice at NCCN Member Institutions, as there are very few data to inform selection of modality.

For those choosing to have regular surveillance (imaging with or without blood tests), the recommended frequency is based on the risk of distant metastasis. The NCCN Guidelines recommend risk stratifying patients into low, medium, and high risk of distant metastasis based on the highest risk factor present. For patients with high risk of distant metastasis who opt to have surveillance imaging, the recommended frequency is every 3 to 6 months for 5 years, then every 6 to 12 months for years 6 through 10, then as clinically indicated. For patients with medium risk of distant metastasis who opt to have surveillance imaging, the recommended frequency is every 6 to 12 months for 10 years, then as clinically indicated. For patients



NCCN Guidelines Version 2.2021

Melanoma: Uveal

with low risk of metastasis who opt to have surveillance imaging, consider imaging every 12 months. Adjusting follow-up frequency based on risk of metastasis is based on clinical practice at NCCN Member Institutions, and this approach has not been prospectively tested to determine whether it results in better yield from imaging or better outcomes. There are very little data to inform the recommended frequency of imaging follow-up.

Risk factors for metastasis include a variety of genetic markers as well as tumor size at presentation. The NCCN Guidelines list specific risk factors to be used for risk stratification to determine the frequency of surveillance imaging during follow-up. The NCCN Guidelines recommend using AJCC T stage for risk stratifying according to primary tumor size. T1 is considered low risk, T2 and T3 medium risk, and T4 high risk. For patients who had a biopsy of their primary tumor, both cell histology and certain molecular features have been shown to be prognostic for risk of distant spread, and should be used for risk stratification. GEP as described by Onken et al⁴⁸ is recommended to determine whether the tumor is Class 1A (low risk), Class 1B (medium risk), or Class 2 (high risk) to inform frequency of follow-up. The following chromosomal abnormalities are also considered risk factors that should inform frequency of follow-up: disomy 3 (low risk), gain of chromosome 6p (low risk), monosomy 3 (high risk), and gain of chromosome 8q (high risk). Mutations in several genes have also been shown to be prognostic for distant metastasis, and should be used for risk stratification: *EIF1AX* (low risk), *SF3B1* (medium risk), and *BAP1* (high risk). PRAME expression is also an indicator of high risk to be used to inform frequency of follow-up. If biopsy not performed, then follow medium- or high-risk pathways, depending on whether any high-risk features are present.

Management of Recurrence

Workup for Recurrence

If a recurrence is detected, workup should include history and physical to identify any signs or symptoms associated with recurrence or metastasis. Biopsy may also be appropriate. Whereas intraocular recurrence can often be diagnosed and managed without a biopsy, additional prognostic FNA biopsy may be valuable to determine whether the tumor has developed any high-risk features that warrant more frequent surveillance. Extraocular recurrence or metastasis should be confirmed histologically whenever possible or if clinically indicated. Appropriate biopsy techniques in this setting may include FNA or core biopsy. For patients with metastasis who are considering treatment with targeted therapy, tissue should be obtained for genetic analysis (screening for mutations that may be potential targets for treatment or to determine eligibility for a clinical trial) from either biopsy of the metastasis (preferred) or archival material. Broader genomic profiling may be considered if the results could inform future treatment decisions or eligibility for clinical trials.

Patients with local recurrence should have ocular orbital imaging (if not recently previously done) to evaluate the extent of local recurrence. Patients who develop distant metastatic disease after treatment of primary uveal melanoma should have ocular orbital imaging as part of workup to check for local recurrence, since asymptomatic local recurrences may be present at the time distant metastasis is discovered. Workup for patients with recurrence should include broader imaging to investigate specific signs or symptoms, and/or for baseline staging. Because the most frequent sites of metastasis are liver, lungs, skin/soft tissue, and bones, imaging options for baseline staging in patients with recurrence or metastasis include contrast-enhanced MR or US of the liver, with modality preference determined by expertise at the treating institution. Additional imaging may include chest/abdominal/pelvic CT with contrast and/or whole-body FDG PET/CT. Brain MRI with IV contrast may be performed if



NCCN Guidelines Version 2.2021

Melanoma: Uveal

neurologic symptoms are present, but routine CNS imaging is not recommended. All scans should be performed with IV contrast unless contraindicated. As described below, for patients with distant metastasis, a thorough evaluation of the size and location of all metastases can help in assessment of prognosis and evaluation of treatment options.

For patients with distant metastases, consider measuring LFTs, including LDH, as part of workup. However, their role in risk stratification of metastatic uveal melanoma is unknown. As described below, elevation of LFTs has been associated with poorer OS in patients with metastatic uveal melanoma.^{19,20,22,497,569-574}

Treatment for Local Recurrence

Given the rarity of local recurrence after treatment of primary uveal melanoma, data on treatment of local recurrences are scant, and it is unclear which approaches result in the best outcomes. Most studies had fewer than 10 patients with local recurrence, and many studies either managed all local recurrences with enucleation or did not report on retreatment approaches. In the few studies that reported outcomes after treatment of local recurrence (n ≥ 10),^{348,388,416,423,443,575-579} reasonably high rates of local control were achieved with the following globe-conserving modalities: laser photocoagulation,^{348,416} TTT,^{443,578} proton-beam RT,^{416,423,576-578} and plaque brachytherapy RT.^{388,443,578,579} Similar to the primary treatment setting, some patients treated with globe-conserving therapy for local recurrence subsequently underwent enucleation due to (suspected or confirmed) tumor regrowth or complications such as pain and neovascular glaucoma.^{348,416,423,575,576,578,579} There is very little evidence to inform selection of treatment for recurrence. Results from one retrospective study of 73 patients with local recurrence suggest that treating recurrence with proton-beam RT (n = 31) versus enucleation (n = 42) may result in similar metastasis-free survival and OS.⁵⁷⁷ Another retrospective analysis of 51 patients with local recurrence found that local

control after treatment of recurrence was more likely in those with longer times between primary treatment and development of recurrence, and risk of metastasis was higher in patients whose local recurrence was characterized by vertical/diffuse growth versus horizontal/marginal growth.³⁴⁸

NCCN Recommendations for Treatment of Local Recurrence

The recommended treatment options for local recurrence depend on the extent of disease. For intraocular recurrence (limited to the eye, without orbital involvement), the recommended options include radiation, either by plaque brachytherapy or particle beam, enucleation, or laser ablation. For small recurrences in patients who cannot undergo RT or surgery, trans TTT is recommended. TTT is usually reserved for small recurrences, particularly when recurrence is likely due to incomplete plaque coverage during primary brachytherapy; it is generally not appropriate for recurrences occurring within the RT field or recurrences that may be too thick (>3 mm) for laser treatment to reach the base. It is important to have an in-depth discussion with patients about their treatment options for local recurrence. If there is extraocular involvement, surgical resection is needed, but can be coupled with RT to the orbit (particle beam or photon beam) and/or cryotherapy to the orbital tumor. If there is orbital involvement and the patient has had prior enucleation, options include surgical resection or cryotherapy to the orbital tumor, and/or RT to the orbit (particle beam or photon beam). Recommendations for administration of different RT modalities are in the section entitled *Radiation Therapy* (above).

Treatment for Metastatic Disease

Survival after detection of distant metastatic disease varies widely across studies, with median OS ranging from 3 to 30 months.^{569,580} Survival outcomes vary widely even between studies testing the same or similar treatments,^{569,580,581} and even when only considering studies with large



NCCN Guidelines Version 2.2021

Melanoma: Uveal

patient sample sizes ($n > 100$; median OS 3–20 months).^{21-23,481,495,570,580} Part of the variation could be due to differences in patient selection, as there are many factors that have been shown to be associated with survival. Some meta-analyses suggest that survival after metastasis is shorter for studies of unselected patients compared with studies of selected patients, but those with selected patients were also more likely to be testing an active treatment and those of unselected patients were more likely to include cases managed with best supportive care or palliative approaches.⁵⁶⁹ Several studies have found that a small percentage of patients with uveal melanoma metastasis experience long-term survival (≥ 5 years) after development of distant metastatic disease.^{19,21,481} Several long-term studies have shown a bimodal distribution suggesting a population with short-term survival (median OS < 1 year) and a separate population with long-term survival (median OS > 2 years).^{19,21}

Studies have reported a wide range of factors associated with OS after detection of metastasis, and results vary across studies. Patient characteristics reported by multiple studies, including multivariable analyses, to be associated with poorer OS after metastasis include older age, male sex, and poorer performance status, although there are opposing data for each of these factors.^{19-22,481,497,501,563,569-572,574} Multiple studies have also found that poor OS after metastasis is associated with symptoms at the time of metastasis (compared with asymptomatic metastasis detected by surveillance), shorter disease-free interval before metastasis, higher number of anatomic sites involved, involvement of liver, and greater disease volume (based on various metrics, such as percent of liver involvement, volume of liver metastases, total number of metastases, number of liver metastases, size of largest metastasis or largest liver metastasis, M-stage).^{19-22,497,501,546,562-564,569-574,582-585} In addition, elevated liver enzymes at the time of diagnosis of metastasis, particularly LDH and APH, have been associated with shorter OS.^{19,20,22,497,569-574}

Whereas in recent years the options for treating metastatic cutaneous melanoma have dramatically improved, treatment of distant metastases from uveal melanoma still presents a major clinical challenge. Several retrospective studies suggest that treatment for distant metastases (from uveal melanoma) improves survival, although it is unclear whether these results are influenced by selection bias.^{21,23,501,574,584} Other studies did not find that treatment improved survival,^{481,572} reporting that patients treated with supportive care only had median OS ranging from 1.7 to 4.9 months, although those opting for supportive care are more likely to have risk factors for poor survival.^{23,501,584} For treatment of distant metastasis from uveal melanoma, a wide variety of approaches have been tested, including surgery, RT, ablative approaches, vaccines, various systemic therapies (chemotherapies, immunotherapies, targeted therapies, and various combinations), and localized chemotherapy/immunotherapy.^{22,569,580,581,585-587} Systematic reviews, meta-analyses, and retrospective studies that included patients treated with a variety of therapies suggest that the best outcomes are seen in patients who received liver-directed treatments, particularly those treated with surgery, especially if complete resection was achieved.^{19,22,500,562,563,569,571,574,580,582,585,588,589} It is unclear whether these effects are due to other factors, such as the lower volume of metastatic disease, which would make a patient eligible for surgery and/or liver-directed treatments, and more likely to have complete resection. One phase III randomized trial (EORTC 10821) found no difference in OS in 171 patients with liver metastasis from uveal melanoma treated with IV fotemustine versus hepatic arterial infusion (HAI) with fotemustine, despite the HAI approach showing higher response rates and progression-free survival (PFS).⁵⁹⁰ A few studies suggest that better survival was seen in those who had a response to therapy for metastatic disease,^{21,569} but some did not find an association.¹⁹



NCCN Guidelines Version 2.2021

Melanoma: Uveal

Resection of Metastases

As mentioned above, multiple prospective and retrospective studies and meta-analyses have found that among patients with metastatic uveal melanoma, those who can be treated with surgery have the best outcomes, especially if complete resection is achieved.^{21,562,563,569,580-582,585,589,591-595}

Multiple studies have reported median OS greater than 20 months after resection of uveal melanoma

metastases.^{21,562,563,581,585,589,591,592,594-599} For liver metastases, rates of complete resection ranged from 27% to 88%.^{21,563,582,585,591,592,595,597}

Multiple studies reported on combination therapy with resection and hepatic arterial infusion, radiofrequency ablation (RFA), transarterial chemoembolization (TACE), or adjuvant systemic therapy.^{562,563,581,585,591,596,600-602}

Liver-Directed Therapy

Due to the tendency of uveal melanoma to metastasize to the liver, a wide range of liver-directed therapies have been tested in patients with liver metastases from uveal melanoma. These include regional isolation perfusion of the liver, various methods of embolization (eg, chemotherapy, radiation, immunotherapy), ablative procedures (eg, RFA), and resection.^{22,569,580,581,589,603-605}

Whereas there are a large number of prospective pilot, phase I, and phase II studies that reported outcomes for liver-directed approaches, it is unclear which liver-directed approaches are the best because of the lack of randomized comparative studies in patients with liver metastases from uveal melanoma.

Regional Isolation Perfusion

Several techniques have been developed for localized delivery of pharmaceutical therapy to the liver for treatment of hepatic metastases. The idea behind these techniques is that higher doses can be administered locally than would be feasible systemically due to toxicity. Methods include isolated hepatic infusion (IHP), percutaneous hepatic

perfusion (PHP), HAI, and embolization techniques, which are described in the next section.

Liver metastases derive most of their blood supply from the hepatic artery, whereas the blood source for benign hepatocytes is primarily the portal vein.⁶⁰⁶ IHP and HAI both deliver therapy via the hepatic artery to maximize drug delivery to liver metastases while limiting exposure to healthy parenchyma.⁶⁰⁷ For IHP, higher temperatures are often used to further increase the effective concentration of therapeutic agent while limiting systemic exposure.⁶⁰⁷ Whereas IHP is done during surgery, has risk of morbidity, and usually can only be done once, HAI and PHP are less invasive techniques, with lower risk of morbidity, and have the potential to be performed multiple times to increase depth of response.^{581,589,605,607}

IHP is an open surgical procedure involving vascular isolation of the liver, allowing high doses of heated chemotherapy to be directly delivered to the organ through an arterial catheter.^{581,589,603,605,607} Alkylating agents are generally preferred because they can be effective even with short exposure time, and the dose-response curve is steep.⁵⁸⁹ Several small prospective studies (n < 40)⁶⁰⁸⁻⁶¹² and a few retrospective studies (n = 19 to 68)⁶¹³⁻⁶¹⁶ have tested hyperthermic IHP in patients with liver metastasis from uveal melanoma. The agent most commonly used in these studies was melphalan, with or without tumor necrosis factor alpha (TNF-alpha) or cisplatin.⁶⁰⁸⁻⁶¹² Good response rates to IHP have been reported in some of these prospective studies (overall response rate [ORR], 50%–68%),⁶⁰⁸⁻⁶¹¹ and retrospective studies (ORR, 67%–83%).⁶¹³⁻⁶¹⁵ However, the IHP procedure is often lengthy (>8 hours),^{581,589,603,608,609} involves significant blood loss (median 2–3.5 L),^{581,608,609} involves long hospital stays (7–10 days),^{589,603,608,609,615,616} can result in significant complications/morbidities (eg, portal vein thrombosis, transient grade 3/4 hepatic toxicity),^{589,603,608-}



NCCN Guidelines Version 2.2021

Melanoma: Uveal

^{610,613-616} and mortalities from the procedure were also observed.^{603,608,613,616} For these reasons IHP is not widely used.

HAI is a technique using catheters in the hepatic artery to deliver chemotherapy directly to the liver.⁵⁸⁹ The number of times HAI can be repeated depends on the type of catheter used.⁵⁸⁹ Efficacy of HAI for liver metastases from uveal melanoma has been reported in several small prospective studies (n = 8–31)⁶¹⁷⁻⁶²¹ and several retrospective studies (n = 10–100).⁶²²⁻⁶²⁶ Most of these studies used fotemustine,^{618,619,622,623,625} but other agents tested include carboplatin,^{617,625} nab-paclitaxel,⁶²⁰ decitabine,⁶²¹ a combination of cisplatin, vinblastine and dacarbazine,⁶²⁴ and melphalan.⁶²⁶ Response rates to HAI were lower and more variable (than for IHP) in both prospective (ORR, 0%–44%)⁶¹⁷⁻⁶²¹ and retrospective studies (16%–36%).^{622,625} One phase III randomized trial (EORTC 10821) in patients with liver metastasis from uveal melanoma found no difference in OS for IV fotemustine versus HAI fotemustine (median OS, 13.8 vs. 14.6 months), despite the HAI approach showing higher response rates (2.4 vs. 10.5%) and PFS (median 3.5 vs. 4.5 months; HR, 0.62; 95% CI, 0.45–0.84, *P* = .002).⁵⁹⁰ Complication rates varied widely across studies, but in general appear to be lower than those reported in studies testing IHP, and are manageable.^{590,617-619,622,623,625,626} Grade 3/4 adverse events (AEs) were mostly hematologic (eg, anemia, leukopenia, thrombocytopenia, neutropenia).^{590,617,621-623} Grade 3–4 catheter-related complications occurred in a minority of patients (≤12%), as did liver toxicity (<10%).^{590,622} Deaths from toxicity were reported in one study,⁵⁹⁰ but not in others.

PHP is a simpler, less invasive alternative to IHP that can be repeated.^{589,605} It uses a double-balloon catheter inserted into the inferior vena cava to isolate hepatic venous blood that is then filtered extracorporeally.^{589,605} Several prospective studies tested PHP in patients with liver metastases from uveal melanoma, but efficacy results are

lacking.⁶²⁷⁻⁶²⁹ Retrospective studies suggest good response rates (>40%), especially if multiple rounds are used.⁶³⁰⁻⁶³² In all these studies melphalan was the agent used.⁶²⁷⁻⁶³² PHP appears to be somewhat better tolerated than IHP, with no treatment-related fatalities, but many patients still experienced hematologic grade 3–4 events, some had non-hematologic grade 3–4 AEs (eg, bleeds, thromboembolism), and some had extended hospital stays (4–5 days) or had to be readmitted.⁶²⁹⁻⁶³¹

Hepatic Embolization

Hepatic arterial embolization is a method for delivering to the liver chemotherapy, immunotherapy, or radioactive agents, while increasing dwell time and providing selective ischemia.^{589,603}

Hepatic Chemoembolization

There are no standard protocols for hepatic chemoembolization, also called hepatic TACE or hepatic arterial chemoembolization (HACE). In general, two approaches have been used for treatment of uveal melanoma metastases to the liver. One involves HAI with the active agent, followed by addition of either a transient or permanent embolic agent.^{589,603} The active agent is usually mixed with ethiodized oil (to increase dwell time), and embolization agents include absorbable gelatin sponge or polyvinyl alcohol particles.^{589,603} The other approach uses drug-eluting beads produced from a polyvinyl alcohol hydrogel that has been modified with sulfonate groups for the controlled loading and delivery of chemotherapy agents.⁶⁰³ These beads serve for localized drug delivery and as an embolic agent to render tumors ischemic.⁶⁰³

Multiple retrospective⁶³³⁻⁶⁴⁰ as well as a few prospective studies⁶⁴¹⁻⁶⁴⁴ have evaluated chemoembolization for treatment of hepatic metastasis in patients with uveal melanoma. Using traditional methods (active agent infusion + addition of embolic agent), response rates varied widely, but could be as high as 57%.^{633,634,636,637,639-645} Chemotherapies used included



BCNU, mitomycin C, fotemustine, cisplatin, carboplatin, doxorubicin, and 1,3-bis (2-chloroethyl)-1-nitrosourea; embolic agents used included gelatin sponge, polyvinyl sponge, resorbable microspheres, and polyvinyl alcohol particles.^{633,635,636,638-645}

Only a few studies reported outcomes for patients with liver metastases from uveal melanoma that were treated with trans-arterial chemotherapy-eluting beads.⁶⁴⁶⁻⁶⁴⁸ One phase II study reported 100% ORR in the 10 patients treated with irinotecan-loaded polyvinyl alcohol microspheres.⁶⁴⁶ In contrast, a retrospective study of irinotecan-loaded beads in 28 patients with uveal melanoma liver metastases reported much lower response rates.⁶⁴⁸ A retrospective study including 58 patients treated with TACE using irinotecan-charged microbeads reported an ORR of 27.5% (all partial responses).⁶⁴⁹ Another prospective noncontrolled study testing beads loaded with doxorubicin in patients with unresectable liver metastases from ocular melanomas only reported toxicity and quality of life.⁶⁴⁷

Comparisons of hepatic chemoembolization with other treatments for uveal melanoma liver metastasis are limited. One retrospective study compared cisplatin-based chemoembolization (TACE) versus HAI and versus systemic therapy, and found that chemoembolization was associated with the best response rate, although OS did not differ between the groups.⁶³⁴ However, those who responded to TACE had better OS than those who did not respond and better than those treated with HAI or systemic therapy.⁶³⁴ For patients with uveal melanoma liver metastases treated with chemoembolization, several studies found that OS was better in responders versus non-responders,^{634,637,638,640,641,643} whereas others did not find a significant association.^{642,649}

Chemoembolization is well tolerated in patients with liver metastases from uveal melanoma, with few or no treatment-related deaths.^{636,642,644,645,647-650} AEs reported in more than one study include abdominal pain, fever,

nausea, vomiting, liver dysfunction, and thrombocytopenia.^{633,636,639,640,644,646,648,649} Some studies recommend supportive treatment with antibiotic and antiemetic prophylaxis, IV hydration, and major analgesic before and after the procedure.^{644,646}

Hepatic Immunoembolization

Hepatic immunoembolization involves infusion of an immunologic stimulant into the hepatic artery, followed by addition of an embolizing agent.⁶⁰³ The rationale is that the ischemia will start the destruction of the tumor, releasing antigens so that local stimulation of the immune system may result in systemic immune response to prevent tumor growth.⁶⁰³ Several studies in patients with liver metastases from uveal melanoma have tested immunoembolization using granulocyte-macrophage colony-stimulating factor (GM-CSF) ethiodized oil plus a gelatin sponge.^{651,652} GM-CSF is a glycoprotein secreted by immune cells such as activated T cells that increases myeloid cell production, stimulates macrophages, increases cytotoxicity of monocytes toward tumor cell lines, and promotes maturation of dendritic cells.⁶⁰³ A phase I trial with 34 uveal melanoma patients and unresectable liver metastases occupying less than 50% of total liver volume reported an ORR in the liver of 32%, and response correlated with better OS.⁶⁵¹ A phase II randomized trial with 52 patients with uveal melanoma and hepatic metastases only (also <50% liver volume) reported an ORR of 21.2% for the 25 patients treated with immunoembolization versus 16.7% for the 27 who received bland embolization (GM-CSF replaced with saline).⁶⁵² In this study hepatic response was not correlated with OS, but was associated with better PFS. AEs associated with immunoembolization in these studies included abdominal pain, fever, nausea, and transient increases in hepatic enzymes.^{651,652} One patient had acute respiratory failure but recovered; there were no treatment-related deaths.



NCCN Guidelines Version 2.2021

Melanoma: Uveal

Hepatic Radioembolization

Hepatic radioembolization, also called hepatic transarterial radioembolization (TARE) or selective internal RT (SIRT), is a procedure in which glass or resin yttrium-90 microspheres are introduced to the hepatic artery, both as a mechanism for radiation delivery and for embolization.⁶⁰³ The microspheres must be of sufficient size to have embolic effect.⁶⁰³ Response rates from retrospective studies varied widely (6%–100%), but disease control rate was consistently greater than 50%.⁶⁵³⁻⁶⁵⁸ A phase II study reported ORR of 39% in the 23 patients who received radioembolization as first-line treatment for liver metastasis, and ORR of 33% in the 24 patients who received radioembolization after progression on immunoembolization, with disease control rate of 87% and 58%, respectively.⁶⁵⁹ Across studies, radioembolization was well tolerated, with most toxicities being grade 1–2 and self-limiting, and no treatment-related deaths.⁶⁵³⁻⁶⁵⁷ AEs included abdominal pain/discomfort, nausea and vomiting, LFT elevation (sometimes due to progression), transient lymphopenia, and gastric ulcer.^{654-657,659}

Ablative Procedures for Liver Metastases

Although ablative procedures such as cryotherapy and thermal ablation have been used with some success for liver metastases from other kinds of cancer, there are very little reported clinical data on the efficacy of these techniques for liver metastases from uveal melanoma. The supposed advantage of ablative techniques is that compared to surgery these techniques are tissue-sparing, less invasive, cost-saving, and have lower rates of complications, while still being potentially curative.⁶⁶⁰ Ablation may be feasible for tumors that are difficult to resect (due to location), although for some tumors ablative options may be limited due to tumor visibility and correct interpretation of tumor extent and stage.⁶⁶⁰ The most commonly used methods of thermal ablation for liver tumors include RFA and microwave ablation (MWA).⁶⁶⁰⁻⁶⁶² Both methods use heat induction and destroy tissue through thermally induced coagulative necrosis. The

difference is that RFA uses alternating electric current at frequencies from 375 to 500 kHz, and MWA uses an electromagnetic field at frequencies greater than 900 kHz.^{660,662,663} RFA uses an electrode to deliver alternating current that heats tissue to 50 to 100°C near the electrode, causing almost instant coagulation necrosis.^{660,662,663} For RFA, ablation volume is limited by tissue boiling and charring that then insulate the effect through increased impedance, and limited by the heat-sink effect caused by blood flow dispersing the thermal energy.⁶⁶¹⁻⁶⁶³ The resulting ablation area may have unpredictable size and shape, and multiple sessions or multiple electrodes may be needed to fully ablate the target area.^{661,663} MWA uses an antenna probe to generate an electromagnetic field that rapidly heats surrounding tissue to greater than 150°C, causing necrosis.⁶⁶⁰⁻⁶⁶³ The heat-sink effect is more limited than in RFA, and the resulting ablation zone is larger and more homogeneous than with RFA.⁶⁶⁰⁻⁶⁶⁴ However, the ability to rapidly ablate a larger area can result in larger areas of healthy tissue damage.^{663,665} Based on data from other (non-uveal) types of liver tumors, safety of MFA and RFA appears similar.^{662,663,665-667} Both methods rarely lead to major complications (<3%), such as hemorrhage, infection, organ injury, liver failure, pneumothorax, pleural effusions, ascites, fever, and portal vein thrombosis.^{662,663,667} Due to the need for grounding pads to complete the circuit, RFA can also cause skin burns.⁶⁶³

Cryoablation uses rapid gas expansion at a probe tip to quickly cool surrounding tissues to as low as -140°C.^{660,661,668} This creates an ice ball that dehydrates tissues, and causes irreversible cell damage and cell death.^{660,661,668,669} Vascular injury also causes cell death by ischemic hypoxia.^{668,669} Repeated freeze-thaw cycles are often used to maximize tissue cell death throughout the target area.^{660,661,668,670} Cryotherapy can be performed percutaneously, laparoscopically, or during open surgery.⁶⁷⁰ The result of the procedure is a zone of central necrosis surrounded by tissue in which cells are not fully damaged.⁶⁷⁰ Damage to the microvasculature can cause edema, inflammation, and thrombosis.⁶⁷⁰



Complications may include pain, infection (eg, wound infection, pneumonia), hemorrhage, biliary injury, thrombocytopenia, pleural effusion, renal impairment, and in older literature, occasionally a fatal complication called “cryoshock.”^{661,668,670,671} Whereas some studies found that cryoablation was more likely to cause complications compared with RFA, other analyses suggest that complication rates are similar to RFA, especially in more recent studies.^{660,661,668,669,671-673}

There are very few studies reporting outcomes for patients with liver metastases from uveal melanoma treated with ablative therapy.^{596,601,674-677} Methods tested include RFA^{596,601,675,677} and laser-induced interstitial thermotherapy (LITT).⁶⁷⁴ The efficacy and safety of ablative techniques is difficult to ascertain, because most of these studies contained fewer than 20 patients with uveal melanoma,^{601,674-677} included both patients with uveal melanoma and other types of melanoma (and did not report results separately),^{675,676} or combined the ablative therapy with other therapies (ie, surgery, TACE, systemic therapy).^{596,601,674,677} Nonetheless, it is notable that several retrospective studies reported that relatively long median OS was greater than 20 months in cohorts of uveal melanoma patients with liver metastases treated with LITT (±TACE),⁶⁷⁴ RFA,⁶⁷⁵ or percutaneous thermal ablation (± systemic therapy).⁶⁷⁶ In a retrospective study of uveal melanoma patients with liver metastases treated with surgery alone (n = 57) or a combined approach in which some metastases were resected and others treated with RFA (n = 13), those treated with the combination approach had similar disease-free survival as those treated with surgery alone (median 7 vs. 10 months) and OS (median 28 vs. 27 months).⁵⁹⁶ Moreover, there were no recurrences at the 22 sites treated with RFA after a median follow-up of 63 months (range 7–83 months).⁵⁹⁶ These results suggest that RFA may be as effective as surgery, and could be used in lieu of surgery for metastases that are difficult to resect.

External Beam Radiation for Uveal Melanoma Metastases

Published data on external beam RT for uveal melanoma metastases are extremely scant with no study reporting outcomes or palliative effects.

Systemic Therapy for Distant Metastatic Disease

Many systemic therapies have been tested in prospective trials as treatment for metastatic uveal melanoma, including chemotherapies^{590,678-688} targeted therapies,^{685-687,689-699} and immunotherapies.⁷⁰⁰⁻⁷¹³ Many systemic therapy combinations have also been tested in prospective trials, including chemotherapy combinations,^{681,714-723} biochemotherapy (chemotherapy + immunotherapy),⁷²⁴⁻⁷²⁷ and a variety of other systemic therapy combinations.^{684,728-732} For treatment of metastatic uveal melanoma, systemic therapies have largely been tested in small phase II studies, and most have shown little activity (response rate <10%),^{587,589,733-735} especially compared with the efficacy of checkpoint immunotherapies and BRAF/MEK inhibitor combinations in metastatic cutaneous melanoma.⁷³⁶⁻⁷⁴⁴ The few larger randomized phase II/III trials comparing systemic therapies for metastatic uveal melanoma have failed to identify any systemic therapies that are consistently more effective than chemotherapy,^{681,684-687,693,695,728} although there are some recent promising results from noncomparative studies that warrant further investigation. As noted above, meta-analyses suggest that for metastatic uveal melanoma, systemic therapy appears to result in worse outcomes than localized treatment (surgery or liver-directed therapies), although differing patient selection criteria across studies may be a confounding factor in these analyses.^{22,580,581,589} One randomized trial showed that (IV) systemic chemotherapy results in lower response rate and shorter PFS than HAI chemotherapy in patients with liver metastases, although OS was similar across arms.⁵⁹⁰ For patients who are not appropriate for localized therapy, selection of systemic therapy is very challenging, necessitating further study into better options.



NCCN Guidelines Version 2.2021

Melanoma: Uveal

Cytotoxic Regimens

A wide variety of chemotherapies have been tested in prospective trials (ie, pilot, phase I, phase II) in patients with metastatic uveal melanoma, and outcomes have been reported for the following single-agent chemotherapies: dacarbazine,⁶⁸⁴⁻⁶⁸⁷ paclitaxel,⁶⁸⁰ DHA-paclitaxel,⁶⁷⁹ temozolomide,^{678,685,687} fotemustine,⁵⁹⁰ bendamustine,^{682,683} treosulfan,⁶⁸¹ liposomal vincristine,⁶⁸³ arsenic trioxide,⁶⁸⁸ and lenalidomide.⁷⁴⁵ Most studies evaluated patients for response to treatment, but responses to these therapies were rarely observed.^{590,678-688,745} In these prospective trials the few responses observed were in patients treated with fotemustine (2/83),⁵⁹⁰ liposomal vincristine (1/4),⁶⁸³ dacarbazine (3/36),⁶⁸⁶ and DHA-paclitaxel (1/22).⁶⁷⁹ For the studies that measured PFS and OS with these single-agent chemotherapy regimens, median PFS was always less than 4 months,^{590,678,679,681,684-687} and median OS was nearly always greater than 10 months.^{590,678,679,685-687} EORTC 10821, a phase III randomized trial, reported median OS of 13.8 months for patients treated with IV fotemustine, but this longer OS is likely due to the trial including only patients with liver metastases (no extrahepatic metastases).⁵⁹⁰ It remains unclear whether any single-agent chemotherapy improves survival relative to best supportive care.

Combination chemotherapies that have been tested in prospective trials for metastatic uveal melanoma include gemcitabine/treosulfan,^{681,714-718} dacarbazine/treosulfan,⁷²⁰ cisplatin/gemcitabine/treosulfan,^{719,746} cisplatin/dacarbazine/vinblastine,⁷²¹ docetaxel/carboplatin,⁷²² and tirapazamine/cisplatin.⁷²³ All of these were tested in pilot, phase I, or phase II studies, most of which reported response rates of less than 5%. Due to an early pilot study that reported a response rate of nearly 29% for patients with metastatic uveal melanoma (n = 14),⁷¹⁸ gemcitabine/treosulfan was tested in multiple studies, but in the five subsequent studies the response rate was much lower, ranging from 0% to 4.2%.^{681,714-717} Four of these studies (including the pilot) reported PFS

and OS data, with median PFS ranging from 2.5 to 6.7 months, and median OS ranging from 7.5 to 14.2 months.^{681,714,715,717,718} Results from one phase II study suggested that higher treosulfan doses (≥ 3500 mg/m²) provided better outcomes with this combination. Nonetheless the response rate at these higher doses was only 5.2%.⁷¹⁴ A randomized phase II study found that gemcitabine/treosulfan combination, using the higher treosulfan dose, did provide better PFS and a trend for better response compared with treosulfan alone, but the overall response was still relatively low (4.2% in the combination arm), and the PFS relatively short (mean 3 months in the combination arm).⁶⁸¹ Addition of cisplatin to gemcitabine/treosulfan did not improve results—there were no responses in both of the studies that tested this triplet.^{719,746} There were also no responses seen in the phase II trials that tested dacarbazine/treosulfan,⁷²⁰ docetaxel/carboplatin,⁷²² and tirapazamine/cisplatin.⁷²³ The one phase II study testing cisplatin/dacarbazine/vinblastine reported a surprisingly high ORR of 20%, with median PFS of 5.5 months and median OS of 13.0 months.⁷²¹ This result needs to be repeated, and may be a product of patient selection.

Meta-analyses combining results across studies that tested chemotherapy in patients with metastatic uveal melanoma report ORRs ~4%,⁵⁸⁷ median PFS of 2.6 months,²² and median OS ranging from 9 to 11 months.^{22,580}

Targeted Therapy

Targeted therapies that have been tested in prospective studies as single-agent therapy for patients with metastatic uveal melanoma include the tyrosine kinase inhibitors (TKIs) imatinib^{689,690,747} and sunitinib,^{686,692} the mitogen-activated protein kinase (MEK) inhibitors trametinib^{693,694} and selumetinib,⁶⁸⁵ the multi-kinase inhibitor sorafenib,⁶⁹¹ the receptor TKI cabozantinib,^{687,695} the VEGF inhibitor aflibercept,⁶⁹⁸ the HSP90 inhibitor ganetespib,⁶⁹⁶ and the topoisomerase inhibitor 9-nitro-camptothecin.⁶⁹⁹ Targeted therapy combinations that have been tested in prospective trials



NCCN Guidelines Version 2.2021

Melanoma: Uveal

include trametinib plus uprosertib, an inhibitor of protein kinase B (AKT),⁶⁹³ binimetinib (MEK inhibitor) plus sotrastaurin (PKC inhibitor),⁷³⁵ and everolimus (mTOR inhibitor) plus pasireotide (IG1FR inhibitor).⁶⁹⁷ Prospective studies in patients with metastatic uveal melanoma have also tested combinations of chemotherapy plus targeted therapy, including carboplatin/paclitaxel/sorafenib,⁷³¹ fotemustine/sorafenib,⁷⁴⁸ dacarbazine/selumetinib,⁶⁸⁴ temozolomide/bevacizumab,⁷³² and carboplatin/paclitaxel/bevacizumab ± everolimus.⁷²⁸ These prospective studies were pilot studies, phase I trials, and phase II trials, and in most of them the overall response was less than 10%.^{685,689-691,693-699,747}

Although uveal melanomas often express KIT, they rarely harbor the c-KIT mutations associated with response to imatinib in other cancers.^{59,689,747,749} It is thus perhaps not surprising that response rates to imatinib were low in patients with metastatic uveal melanoma.^{689,690,747} Two studies reported no responses,^{689,690} and 8% response was observed in a third study that selected patients with high KIT expression.⁷⁴⁷ These responses were seen in patients who did not have activating mutations of c-KIT in exons 11, 13, or 17.⁷⁴⁷ Given the unimpressive median PFS (2.8 months) and OS (6.9 months) for the 25 patients in this study, imatinib is not considered a good option for patients with metastatic uveal melanoma.⁷⁴⁷ Results were similar for the other TKI, sunitinib. A pilot study in 20 patients with metastatic uveal melanoma expressing KIT reported an ORR of 5% for patients treated with sunitinib,⁶⁹² but a subsequent larger phase II randomized study reported no responses in the 38 patients treated with sunitinib (vs. ORR of 8% with dacarbazine), and PFS and OS with sunitinib were no better than the comparator dacarbazine.⁶⁸⁶

Although *BRAF* mutations are rare in uveal melanoma,^{34,51,53,54,60,62,63} most uveal melanomas carry mutations in *GNAQ* or *GNA11* that result in constitutive activation of the RAS/RAF/MEK/ERK pathway.^{34,35,51,64,66,69,70,750} Prospective studies of MEK inhibitors have

yielded mixed results in patients with metastatic uveal melanoma.^{685,693,694} A large phase II randomized trial in 101 patients with metastatic uveal melanoma reported responses in 14% of the 50 patients treated with selumetinib, and no responses in the 51 patients in the comparator arm (chemotherapy with temozolomide or dacarbazine).⁶⁸⁵ Selumetinib modestly improved PFS compared with chemotherapy (median 3.7 vs. 1.6 months; $P < .001$), although the effect on OS was not significant (median 11.8 vs. 9.1 months; $P = .09$).⁶⁸⁵ However, in a phase III randomized trial in 129 patients with metastatic uveal melanoma that compared selumetinib plus dacarbazine versus placebo plus dacarbazine, selumetinib did not improve response (3% vs. 0%) or PFS (median 2.8 vs. 1.8 months).⁶⁸⁴ Results from other MEK inhibitors were not impressive. No responses to trametinib were observed in the 16 patients with metastatic uveal melanoma in a phase I trial, and the median PFS was unremarkable (1.8 months).⁶⁹⁴ In a subsequent phase II study, 1 of 18 (5.6%) patients with metastatic uveal melanoma responded to single-agent trametinib, and PFS was slightly better (median 3.6 months).⁶⁹³ Addition of uprosertib, an AKT inhibitor, yielded very similar results (ORR 4.8%, PFS median 3.6 months).⁶⁹³ A phase Ib/II trial of combination binimetinib (MEK inhibitor) and sotrastaurin (PKC inhibitor) yielded no responses in patients with metastatic uveal melanoma.⁷³⁵ Across studies it appeared that *GNAQ* and *GNA11* mutation status did not impact response rate or outcomes in patients treated with MEK inhibitors.^{684,685,694} Taken together, these data show that some patients with uveal melanoma may respond to the MEK inhibitor selumetinib, and there are limited data suggesting that trametinib may also be marginally effective. Although the data are strongest for selumetinib, it was not FDA approved for use in humans at the time of the most recent Guidelines update, so it could not be included as a recommended option. Trametinib is included as a recommended option based on the positive data for selumetinib and the general lack of systemic therapy options for patients with uveal melanoma. Further study of trametinib for uveal melanoma is needed. Low-grade AEs are common in



NCCN Guidelines Version 2.2021

Melanoma: Uveal

patients treated with MEK inhibitors, with the most common being rash or dermatitis acneiform, diarrhea, nausea, fatigue, hypertension, peripheral edema, elevated AST/ALT, creatinine kinase elevation, and blurred vision or other visual changes.^{684,685,693,694,751} Grade 3–4 events were observed in 20% to 40% of patients, and dose reductions were often needed to manage toxicities.^{684,685,693,694,751}

The multikinase inhibitor sorafenib did not result in any responses in the 32 patients with metastatic uveal melanoma in a phase II trial.⁶⁹¹ A phase II trial combining sorafenib with carboplatin/paclitaxel also showed no responses in 24 patients with metastatic uveal melanoma.⁷³¹

Of the other single-agent targeted therapies tested in prospective trials in patients with metastatic uveal melanoma (aflibercept,⁶⁹⁸ cabozantinib,^{687,695} ganetespib,⁶⁹⁶ and 9-nitro-camptothecin⁶⁹⁹), responses were reported only for the HSP90 inhibitor ganetespib, with one response in the 17 patients tested in the phase II study (ORR of 5.9%).⁶⁹⁶ Across these studies median PFS was less than 6 months for all these agents.^{687,695-699}

The combination of everolimus and pasireotide resulted in no responses in the 13 patients in a phase II trial with metastatic uveal melanoma.⁶⁹³ Combining bevacizumab with chemotherapy resulted in response rates between 0% and 6%, with median PFS less than 6 months, and adding everolimus did not help.^{728,732} Combining bevacizumab and interferon (IFN) alpha yielded similar results.⁷²⁹ Taken together, most meta-analyses concluded that targeted therapy did not improve outcomes relative to conventional chemotherapy.^{22,580,587,735}

Immunotherapy

Given that immunotherapies have dramatically improved treatment landscapes for other difficult-to-treat cancers, there is some hope that the same will be true for uveal melanoma, and a wide variety of

immunotherapies have been tested for treatment of metastatic disease, including checkpoint immunotherapies, IFN, interleukin-2 (IL-2), vaccines, and tumor-infiltrating lymphocytes (TILs).

Biochemotherapy

Interferon alpha-2b (IFN alpha-2b) and IL-2 were among the first immunotherapies tested in prospective trials in metastatic uveal melanoma, mostly in combination with chemotherapy as part of biochemotherapy regimens. Two prospective trials of bleomycin/vincristine/lomustine/dacarbazine (BOLD) chemotherapy in combination with IFN-alpha-2b yielded different results, with one reporting no response in 24 patients with uveal melanoma metastasis,⁷²⁴ and another reporting four responses among 23 patients (ORR 20%).⁷²⁷ A third prospective trial tested BOLD in combination with human leukocyte IFN-alpha, and reported three responses in the 20 evaluable patients with metastatic uveal melanoma (ORR 15%).⁷²⁵ A fourth prospective trial tested BOLD + INF alpha-2b + IL-2, and reported two responses among 25 patients with metastatic ocular melanoma (ORR 8%), including one complete response.⁷²⁶ Results from these studies suggest that biochemotherapy may provide slightly better response rates than conventional chemotherapy for patients with metastatic uveal melanoma, but it is not clear that these regimens improve PFS or OS.^{580,587}

Checkpoint Immunotherapy

Checkpoint immunotherapies tested in prospective studies for metastatic uveal melanoma include anti-CTLA-4 agents ipilimumab and tremelimumab,^{704,705,712} anti-PD-1 agents nivolumab and pembrolizumab,⁷⁰⁷⁻⁷¹⁰ and ipilimumab/nivolumab combination therapy.^{711,713}

In prospective trials,^{704,705,712} expanded access programs (EAPs),⁷⁵²⁻⁷⁵⁷ and a named patient program,⁷⁵⁸ anti-CTLA-4 agents resulted in response



NCCN Guidelines Version 2.2021

Melanoma: Uveal

rates ranging between 0% to 6.5%, median PFS between 2 to 4 months, and median OS of less than 13 months. Meta-analyses have concluded that anti-CTLA-4 systemic therapy results in outcomes that are similar or worse than conventional systemic chemotherapy.^{580,587,734}

Results for other immune checkpoint inhibitor regimens in patients with metastatic uveal melanoma look somewhat more promising. Although one prospective study reported no responses in 17 patients treated with anti-PD-1 systemic therapy,⁷⁰⁸ three other prospective trials and one EAP reported ORRs between 6% to 38%, with eight responses among a total of 81 patients treated (8%).^{707,709,710,759} Median PFS ranged from 2.3 to 11 months.^{707-709,759} Two ongoing phase II trials (NCT02626962 and NCT01585194) testing ipilimumab/nivolumab in patients with metastatic uveal melanoma have reported ORRs of 15.8% and 17.0%, median PFS of 5.0 and 6.1 months, and median OS of 19.4 months in one study and not reached in the other due to insufficient follow-up.^{711,713} Comparative studies are needed to determine whether combination anti-CTLA-4/anti-PD-1 consistently improves outcomes in patients with metastatic uveal melanoma.

Other Immunotherapy

Other immunotherapies for which there are efficacy data from prospective studies in metastatic uveal melanoma include tebentafusp (formerly IMCgp100),^{700,760} dendritic cell vaccination,⁷⁰² and adoptive transfer of TILs.⁷⁰¹ Of these, responses were only seen with TILs adoptive transfer, with responses in 7 of 20 evaluable patients (ORR 35%).⁷⁰¹ These results need further investigation.

NCCN Recommendations for Treatment of Distant Metastatic Disease

Given that there are no treatments for metastatic uveal melanoma that have clearly and consistently been shown to improve outcomes, it is

important to consider all clinical trial options carefully, and when available and clinically appropriate, enrollment in a clinical trial is recommended.

For those who are not appropriate for treatment in the context of a clinical trial, the recommended options are largely based on clinical practice at NCCN Member Institutions. It is important to be aware that even among therapies often used at NCCN Member Institutions, efficacy is limited, and it is not clear which approaches are most effective. Therefore, the guidelines indicate that a combination of approaches may be needed, and it is important to consider each patient's prognosis and treatment goals to determine whether palliative care is the most appropriate option.

Selection of treatment should depend on the location and extent of disease. For patients with metastasis to the liver, regionally hepatic-directed therapies should be considered. Options include: hepatic isolation perfusion, embolization (ie, chemoembolization, radioembolization, immunoembolization), and ablation procedures (ie, thermal ablation, cryotherapy). For patients with extrahepatic disease or hepatic disease that is not amenable to liver-directed therapy, systemic therapy can be considered, although there are no systemic therapies that have reliably improved OS in patients with metastatic uveal melanoma. See below for recommended systemic therapy options.

For both hepatic and extrahepatic metastases, patients with limited or symptomatic disease should consider resection and/or RT by photon beam or SRS. Recommendations for treating uveal melanoma metastases with RT can be found in the section (above) describing *Radiation Therapy* recommended for uveal melanoma, and in the *Principles of Radiation for Metastatic Disease* in the NCCN Guidelines for Melanoma: Cutaneous (available at www.NCCN.org). Photon beam radiotherapy can be used for treatment of distant metastases at risk for causing symptoms or for palliation of symptomatic distant metastases. Dosing for distant metastases: Doses of 8 to 30 Gy in 1 to 10 fractions should be prescribed



NCCN Guidelines Version 2.2021

Melanoma: Uveal

to the appropriate target volume⁷⁶¹ using appropriate 3-D or intensity-modulated RT (IMRT) techniques with or without image guidance.

NCCN Recommendations for Systemic Therapy for Metastatic Disease

Given the lack of positive phase III studies, when available and clinically appropriate, enrollment in a clinical trial is recommended as the preferred option for systemic therapy. The literature is not directive regarding the specific systemic agent(s) offering superior outcomes, but does provide evidence that uveal melanoma is sensitive to some of the same systemic therapies used to treat cutaneous melanoma. In general, uveal melanomas have lower response rates than cutaneous melanoma and no systemic therapies have reliably improved the OS of metastatic uveal melanoma patients. However, individual patients may derive benefit on occasion.

Options to consider (other recommended regimens) include select checkpoint immunotherapies, cytotoxic regimens, and targeted therapy. Recommended checkpoint immunotherapy options for uveal melanoma include anti-PD-1 monotherapy with pembrolizumab or nivolumab, ipilimumab (monotherapy), and combination therapy with nivolumab and ipilimumab. Treatment-related AEs occur in a high percentage of patients treated with anti-CTLA-4 or anti-PD-1 agents, and grade 3–4 related AEs occur in as many as 20% of patients receiving single-agent therapy and in ~50% receiving ipilimumab monotherapy or nivolumab/ipilimumab combination therapy. Careful selection of patients and AE monitoring and management are therefore critical to the safe administration of these agents. See the NCCN Guidelines for Management of Immunotherapy-Related Toxicities (available at www.NCCN.org). Recommended cytotoxic

regimens include dacarbazine, paclitaxel, albumin-bound paclitaxel, or carboplatin/paclitaxel. The only recommended targeted therapy is trametinib. For patients being treated with trametinib, see *Management of Toxicities Associated with Targeted Therapy* in the NCCN Guidelines for Melanoma: Cutaneous (available at www.NCCN.org).

NCCN Recommendations for Follow-up and Subsequent Therapy

Following treatment for metastatic disease, patients should receive imaging to assess response or progression. The recommended cross-sectional imaging modalities are the same as those recommended for workup. At minimum, all patients should have contrast-enhanced MR or US of the liver, with modality preference determined by expertise at the treating institution. Additional imaging may include chest/abdominal/pelvic CT with contrast and/or whole-body FDG PET/CT; however, screening should limit radiation exposure whenever possible. Brain MRI with IV contrast may be performed if neurologic symptoms are present, but routine CNS imaging is not recommended. Scans should be performed with IV contrast unless contraindicated. Those with NED after treatment for metastases may be eligible for clinical trials testing adjuvant therapies. If they opt to forgo adjuvant treatment, then the recommended follow-up surveillance is similar to the follow-up for patients with NED after treatment of localized disease. See recommendations in the *Follow-up* section. If post-treatment imaging shows residual or progressive disease, the NCCN Panel recommends trying other options for treatment of distant metastatic disease.



NCCN Guidelines Version 2.2021

Melanoma: Uveal

Table 1. Risk Factors for Growth in Small Intraocular Melanocytic Lesions

Risk Factor	Studies Demonstrating Correlation with Tumor Growth	Detection Method(s)
Symptoms	Augsburger, 1989 ⁹⁰ ; Butler, 1994 ⁹⁵ ; Shields, 1995 ⁹¹ ; Shields, 2000 ⁹² ; Singh, 2006 ⁹³ ; Shields, 2009 ⁹⁴ ; Lane, 2010 ⁸⁴	History and physical
Lesion thickness (>2 mm)	Augsburger, 1989 ⁹⁰ ; Butler, 1994 ⁹⁵ ; Shields, 1995 ⁹¹ ; COMS 1997 ⁸³ ; Shields, 2000 ⁹² ; Singh, 2006 ⁹³ ; Lane, 2010 ⁸⁴ ; Shields, 2009 ⁹⁴ ; Dalvin, 2019 ⁹⁶	Ultrasound
Lesion diameter (>5 mm)	COMS 1997 ⁸³ ; Dalvin, 2019 ⁹⁶	Comprehensive eye exam, color fundus photography, ultrasound
Subretinal fluid	Shields, 1995 ⁹¹ ; Shields, 2000 ⁹² ; Shields, 2009 ⁹⁴	Color fundus photography, comprehensive eye exam Ancillary option: OCT
Orange pigment (lipofuscin)	Augsburger, 1989 ⁹⁰ ; Butler, 1994 ⁹⁵ ; Shields, 1995 ⁹¹ ; COMS 1997 ⁸³ ; Shields, 2000 ⁹² ; Singh, 2006 ⁹³ ; Shields, 2009 ⁹⁴ ; Dalvin, 2019 ⁹⁶	Color fundus photography, comprehensive eye exam Ancillary options: ocular fundus autofluorescence, OCT
Proximity to optic disc (tumor margin <3 mm)	Augsburger, 1989 ⁹⁰ ; Shields, 1995 ⁹¹ ; Shields, 2000 ⁹² ; Shields, 2009 ⁹⁴	Comprehensive eye exam, color fundus photography
Ultrasound hollowness	Shields, 2009 ⁹⁴ ; Dalvin, 2019 ⁹⁶	Ultrasound (A- and B-scan)
Absence of halo	Shields, 2009 ⁹⁴	Comprehensive eye exam, color fundus photography

OCT, optical coherence tomography



NCCN Guidelines Version 2.2021

Melanoma: Uveal

Table 2. Biopsy Options for Choroidal or Ciliary Body Tumors^{a,231,248}

Biopsy Type ^a	Surgical Approach ^b	Tumor Location ^c	Sample Analysis ^d	Studies Describing Technique, Reporting Yield or Safety ^e (number of patients biopsied)	
Fine-needle aspiration biopsy (FNAB)	Transscleral	Anterior	Cytopathology	Glasgow, 1988 ²⁶¹ (n=6) Eide, 1999 ²⁵¹ (n=50) Shields, 2007 ²⁵⁹ (n=73) Shields, 2007 ²⁵⁸ (n=24; ≤3 mm thick) McCannel, 2012 ²⁴⁶ (n=170) Chang, 2014 ²⁵⁶ (n=38)	Grixti, 2014 ²³⁴ (n=291) Sellam, 2016 ²³⁵ (n=185) Singh, 2016 ²³³ (n=71) Kim, 2018 ²³² (n=11) Matet, 2019 ²⁴⁹ (n=24)
	Transvitreal	Posterior	Cytopathology	Glasgow, 1988 ²⁶¹ (n=15) Eide, 1999 ²⁵¹ (n=14) Cohen, 2001 ²⁵⁰ (n=83) Augsburger, 2002 ⁸⁸ (n=34; diameter ≤10 mm; thickness, ≥1.5 mm but ≤3 mm) Shields, 2007 ²⁵⁹ (n=67) Shields, 2007 ²⁵⁸ (n=32; ≤3 mm thick) Correa, 2014 ²⁵² (n=159)	Chang, 2014 ²⁵⁶ (n=38) ^f Augsburger, 2015 ²³⁶ (n=80) Singh, 2016 ²³³ (n=64) Sellam, 2016 ²³⁵ (n=32) Kim 2017 ²⁵⁵ (n=10) Kim, 2018 ²³² (n=33) Reddy 2017 ²⁵⁴ (n=57) ^f Singh, 2017 ²⁵³ (n=20)
Vitrectomy system (vitreal-cutter)-assisted biopsy ^g	Transvitreal/transretinal	Posterior or equatorial	Cytopathology or Histopathology (depends on exact technique used)	Jensen, 1997 ²⁴⁰ (n=92) Bechrakis, 2002 ²⁶⁸ (n=23) Sen, 2006 ²⁶⁷ (n=14) Bagger, 2013 ²³⁹ (n=123) Grixti, 2014 ²³⁴ (n=448)	Bagger, 2015 ²⁶⁶ (n=39) Nagiel 2017 ²³⁷ (n=17; ≤2.0 mm thick) Grewal, 2017 ²³⁸ (n=18)
Incisional biopsy ^h with Essen forceps	Transvitreal	Anterior	Histopathology	Akgul, 2011 ²⁴² (n=20)	
Incisional biopsy ^h (standard forceps)	Transvitreal	Posterior	Histopathology	Kvanta, 2005 ²⁴³ (n=10) Seregard, 2013 ²⁴¹ (n=46)	

^a Although review articles on techniques for biopsying intraocular lesions include excisional biopsy,^{231,248} and historical literature includes reports of transscleral resection or endoresection being used for uveal melanoma biopsy, these methods are not included in this table because they are no longer commonly used for uveal melanoma due to technical challenges, risk of complications, and concerns about tumor seeding.^{170,272-282}



- ^b Surgical Approach: Table lists typical surgical approach used for each biopsy method. In procedures using a transscleral (direct) approach, where the tumor is approached from the outside, with the needle first puncturing the sclera over the tumor, then the tumor itself, leaving the retina intact.²³¹ Procedures using a transvitreal (indirect) approach involve anterior entry through the pars plana opposite the tumor, going through the vitreous body and retina to reach the tumor.²³¹
- ^c Tumor Location: Although each biopsy method may be used successfully in a range of locations, the feasibility and success rate for each method varies based on tumor location. The table lists the tumor location(s) for which the biopsy method was developed and/or is most often used.
- ^d Sample Analysis: Some methods provide cellular aspirate that can be used for cytopathology; others provide tissue samples that can be sectioned for histopathology. The table reflects the type of sample usually obtained by each of the biopsy methods listed. Both types of samples can be used for molecular analyses for prognostication.
- ^e For each biopsy method, the table lists representative studies including at least 10 cases that reported at least one of the following: detailed description of biopsy technique used, analysis of yield (percent of biopsies providing sufficient material for diagnostic or prognostic analyses), analysis of safety (rates of intraoperative or postoperative procedure-related complication), or analysis to assess risk of seeding (histologic analyses to detect tracts of tumor cells or follow-up for local recurrence). Note that inclusion criteria varied across studies listed in the table. Whereas some studies included only patients with suspected or confirmed uveal melanoma, others included patients with other intraocular conditions.
- ^f In these studies, biopsy procedure removal of vitreous body (vitrectomy) to reduce the risk of vitreous hemorrhage from transvitreal FNAB.
- ^g Vitrectomy system (vitreous-cutter)-assisted biopsy: Includes a variety of methods that use vitrectomy tools both to access tumor via a transvitreal/transretinal approach and to extract tumor tissue using the vitreous cutter and aspiration through the canula. These procedures do not necessarily include a vitrectomy.
- ^h Incisional biopsy techniques described in the literature sometimes included use of a vitreous cutter, vitrectomy, and other procedures to access the biopsy site, wherein the tumor tissue was incised with a diamond knife and removed with forceps.



References

1. McLaughlin CC, Wu XC, Jemal A, et al. Incidence of noncutaneous melanomas in the U.S. Cancer 2005;103:1000-1007. Available at: <https://www.ncbi.nlm.nih.gov/pubmed/15651058>.
2. Singh AD, Turell ME, Topham AK. Uveal melanoma: trends in incidence, treatment, and survival. Ophthalmology 2011;118:1881-1885. Available at: <https://www.ncbi.nlm.nih.gov/pubmed/21704381>.
3. Vajdic CM, Kricker A, Gibling M, et al. Incidence of ocular melanoma in Australia from 1990 to 1998. Int J Cancer 2003;105:117-122. Available at: <https://www.ncbi.nlm.nih.gov/pubmed/12672041>.
4. Swanson MW, Cloud G. A retrospective analysis of primary eye cancer at the University of Alabama at Birmingham 1958-1988. Part I: Eye and orbital cancer. J Am Optom Assoc 1991;62:815-819. Available at: <https://www.ncbi.nlm.nih.gov/pubmed/1813507>.
5. Aronow ME, Topham AK, Singh AD. Uveal Melanoma: 5-Year Update on Incidence, Treatment, and Survival (SEER 1973-2013). Ocul Oncol Pathol 2018;4:145-151. Available at: <https://www.ncbi.nlm.nih.gov/pubmed/29765944>.
6. Mahendraraj K, Lau CS, Lee I, Chamberlain RS. Trends in incidence, survival, and management of uveal melanoma: a population-based study of 7,516 patients from the Surveillance, Epidemiology, and End Results database (1973-2012). Clin Ophthalmol 2016;10:2113-2119. Available at: <https://www.ncbi.nlm.nih.gov/pubmed/27822007>.
7. Virgili G, Gatta G, Ciccolallo L, et al. Incidence of uveal melanoma in Europe. Ophthalmology 2007;114:2309-2315. Available at: <https://www.ncbi.nlm.nih.gov/pubmed/17498805>.
8. Force AOOT. International Validation of the American Joint Committee on Cancer's 7th Edition Classification of Uveal Melanoma. JAMA Ophthalmol 2015;133:376-383. Available at: <https://www.ncbi.nlm.nih.gov/pubmed/25555246>.
9. Damato EM, Damato BE. Detection and time to treatment of uveal melanoma in the United Kingdom: an evaluation of 2,384 patients. Ophthalmology 2012;119:1582-1589. Available at: <https://www.ncbi.nlm.nih.gov/pubmed/22503229>.
10. Mahendraraj K, Shrestha S, Lau CS, Chamberlain RS. Ocular melanoma-when you have seen one, you have not seen them all: a clinical outcome study from the Surveillance, Epidemiology and End Results (SEER) database (1973-2012). Clin Ophthalmol 2017;11:153-160. Available at: <https://www.ncbi.nlm.nih.gov/pubmed/28115829>.
11. Freton A, Chin KJ, Raut R, et al. Initial PET/CT staging for choroidal melanoma: AJCC correlation and second nonocular primaries in 333 patients. Eur J Ophthalmol 2012;22:236-243. Available at: <https://www.ncbi.nlm.nih.gov/pubmed/21959680>.
12. Bagger M, Andersen MT, Andersen KK, et al. The prognostic effect of American Joint Committee on Cancer staging and genetic status in patients with choroidal and ciliary body melanoma. Invest Ophthalmol Vis Sci 2014;56:438-444. Available at: <https://www.ncbi.nlm.nih.gov/pubmed/25537201>.
13. Shields CL, Kaliki S, Furuta M, et al. American Joint Committee on Cancer Classification of Uveal Melanoma (Anatomic Stage) Predicts Prognosis in 7,731 Patients: The 2013 Zimmerman Lecture. Ophthalmology 2015;122:1180-1186. Available at: <https://www.ncbi.nlm.nih.gov/pubmed/25813452>.
14. The Collaborative Ocular Melanoma Study (COMS) randomized trial of pre-enucleation radiation of large choroidal melanoma I: characteristics of patients enrolled and not enrolled. COMS report no. 9. Am J Ophthalmol 1998;125:767-778. Available at: <https://www.ncbi.nlm.nih.gov/pubmed/9645715>.



NCCN Guidelines Version 2.2021

Melanoma: Uveal

15. Chang AE, Karnell LH, Menck HR. The National Cancer Data Base report on cutaneous and noncutaneous melanoma: a summary of 84,836 cases from the past decade. The American College of Surgeons Commission on Cancer and the American Cancer Society. Cancer 1998;83:1664-1678. Available at: <https://www.ncbi.nlm.nih.gov/pubmed/9781962>.

16. Polednak AP, Flannery JT. Brain, other central nervous system, and eye cancer. Cancer 1995;75:330-337. Available at: <https://www.ncbi.nlm.nih.gov/pubmed/8001004>.

17. Bishop KD, Olszewski AJ. Epidemiology and survival outcomes of ocular and mucosal melanomas: a population-based analysis. Int J Cancer 2014;134:2961-2971. Available at: <https://www.ncbi.nlm.nih.gov/pubmed/24272143>.

18. Kujala E, Damato B, Coupland SE, et al. Staging of ciliary body and choroidal melanomas based on anatomic extent. J Clin Oncol 2013;31:2825-2831. Available at: <https://www.ncbi.nlm.nih.gov/pubmed/23816968>.

19. Lorenzo D, Ochoa M, Piulats JM, et al. Prognostic Factors and Decision Tree for Long-Term Survival in Metastatic Uveal Melanoma. Cancer Res Treat 2018;50:1130-1139. Available at: <https://www.ncbi.nlm.nih.gov/pubmed/29198096>.

20. Kollandjian NA, Wei C, Patel SP, et al. Delayed systemic recurrence of uveal melanoma. Am J Clin Oncol 2013;36:443-449. Available at: <https://www.ncbi.nlm.nih.gov/pubmed/22706174>.

21. Rietschel P, Panageas KS, Hanlon C, et al. Variates of survival in metastatic uveal melanoma. J Clin Oncol 2005;23:8076-8080. Available at: <https://www.ncbi.nlm.nih.gov/pubmed/16258106>.

22. Khoja L, Atenafu EG, Suci S, et al. Meta-analysis in metastatic uveal melanoma to determine progression free and overall survival benchmarks: an international rare cancers initiative (IRCI) ocular melanoma study. Ann Oncol 2019;30:1370-1380. Available at: <https://www.ncbi.nlm.nih.gov/pubmed/31150059>.

23. Lane AM, Kim IK, Gragoudas ES. Survival Rates in Patients After Treatment for Metastasis From Uveal Melanoma. JAMA Ophthalmol 2018;136:981-986. Available at: <https://www.ncbi.nlm.nih.gov/pubmed/29955797>.

24. Shields CL, Say EAT, Hasanreisoglu M, et al. Personalized Prognosis of Uveal Melanoma Based on Cytogenetic Profile in 1059 Patients over an 8-Year Period: The 2017 Harry S. Gradle Lecture. Ophthalmology 2017;124:1523-1531. Available at: <https://www.ncbi.nlm.nih.gov/pubmed/28495150>.

25. Isager P, Engholm G, Overgaard J, Storm H. Uveal and conjunctival malignant melanoma in denmark 1943-97: observed and relative survival of patients followed through 2002. Ophthalmic Epidemiol 2006;13:85-96. Available at: <https://www.ncbi.nlm.nih.gov/pubmed/16581612>.

26. Shields CL, Furuta M, Thangappan A, et al. Metastasis of uveal melanoma millimeter-by-millimeter in 8033 consecutive eyes. Arch Ophthalmol 2009;127:989-998. Available at: <https://www.ncbi.nlm.nih.gov/pubmed/19667335>.

27. Shields CL, Shields JA, Materin M, et al. Iris melanoma: risk factors for metastasis in 169 consecutive patients. Ophthalmology 2001;108:172-178. Available at: <https://www.ncbi.nlm.nih.gov/pubmed/11150284>.

28. Geisse LJ, Robertson DM. Iris melanomas. Am J Ophthalmol 1985;99:638-648. Available at: <https://www.ncbi.nlm.nih.gov/pubmed/4014387>.

29. Khan S, Finger PT, Yu GP, et al. Clinical and pathologic characteristics of biopsy-proven iris melanoma: a multicenter international study. Arch Ophthalmol 2012;130:57-64. Available at: <https://www.ncbi.nlm.nih.gov/pubmed/21911649>.



30. Shields CL, Di Nicola M, Bekerman VP, et al. Iris Melanoma Outcomes Based on the American Joint Committee on Cancer Classification (Eighth Edition) in 432 Patients. *Ophthalmology* 2018;125:913-923. Available at:

<https://www.ncbi.nlm.nih.gov/pubmed/29342436>.

31. Amin MB, Edge S, Greene F, et al., eds. *AJCC Cancer Staging Manual* (ed 8th). New York: Springer International Publishing; 2017.

32. Henriquez F, Janssen C, Kemp EG, Roberts F. The T1799A BRAF mutation is present in iris melanoma. *Invest Ophthalmol Vis Sci* 2007;48:4897-4900. Available at:

<https://www.ncbi.nlm.nih.gov/pubmed/17962436>.

33. van Poppel NM, Vaarwater J, Mudhar HS, et al. Genetic Background of Iris Melanomas and Iris Melanocytic Tumors of Uncertain Malignant Potential. *Ophthalmology* 2018;125:904-912. Available at:

<https://www.ncbi.nlm.nih.gov/pubmed/29371009>.

34. de Lange MJ, Razzaq L, Versluis M, et al. Distribution of GNAQ and GNA11 Mutation Signatures in Uveal Melanoma Points to a Light Dependent Mutation Mechanism. *PLoS One* 2015;10:e0138002.

Available at: <https://www.ncbi.nlm.nih.gov/pubmed/26368812>.

35. Onken MD, Worley LA, Long MD, et al. Oncogenic mutations in GNAQ occur early in uveal melanoma. *Invest Ophthalmol Vis Sci* 2008;49:5230-5234. Available at:

<https://www.ncbi.nlm.nih.gov/pubmed/18719078>.

36. Ewens KG, Kanetsky PA, Richards-Yutz J, et al. Chromosome 3 status combined with BAP1 and EIF1AX mutation profiles are associated with metastasis in uveal melanoma. *Invest Ophthalmol Vis Sci* 2014;55:5160-5167. Available at:

<https://www.ncbi.nlm.nih.gov/pubmed/24970262>.

37. Singh AD. Small incision guarded hydroaspiration of iris lesions. *Br J Ophthalmol* 2017;101:1570-1575. Available at:

<https://www.ncbi.nlm.nih.gov/pubmed/28292778>.

38. Harbour JW, Augsburger JJ, Eagle RC, Jr. Initial management and follow-up of melanocytic iris tumors. *Ophthalmology* 1995;102:1987-1993. Available at: <https://www.ncbi.nlm.nih.gov/pubmed/9098306>.

39. Conway RM, Chua WC, Qureshi C, Billson FA. Primary iris melanoma: diagnostic features and outcome of conservative surgical treatment. *Br J Ophthalmol* 2001;85:848-854. Available at:

<https://www.ncbi.nlm.nih.gov/pubmed/11423461>.

40. Klauber S, Jensen PK, Prause JU, Kessing SV. Surgical treatment of iris and ciliary body melanoma: follow-up of a 25-year series of patients. *Acta Ophthalmol* 2012;90:122-126. Available at:

<https://www.ncbi.nlm.nih.gov/pubmed/20456258>.

41. Kaliki S, Shields CL. Uveal melanoma: relatively rare but deadly cancer. *Eye (Lond)* 2017;31:241-257. Available at:

<https://www.ncbi.nlm.nih.gov/pubmed/27911450>.

42. Riechardt AI, Karle B, Cordini D, et al. Proton therapy of iris melanoma with 50 CGE : Influence of target volume on clinical outcome. *Strahlenther Onkol* 2017;193:943-950. Available at:

<https://www.ncbi.nlm.nih.gov/pubmed/28631017>.

43. Boyd SR, Gittos A, Richter M, et al. Proton beam therapy and iris neovascularisation in uveal melanoma. *Eye (Lond)* 2006;20:832-836.

Available at: <https://www.ncbi.nlm.nih.gov/pubmed/16167079>.

44. Detorakis ET, Engstrom RE, Jr., Wallace R, Straatsma BR. Iris and anterior chamber angle neovascularization after iodine 125 brachytherapy for uveal melanoma. *Ophthalmology* 2005;112:505-510.

Available at: <https://www.ncbi.nlm.nih.gov/pubmed/15745782>.

45. Tarlan B, Kiratli H. Uveal Melanoma: Current Trends in Diagnosis and Management. *Turk J Ophthalmol* 2016;46:123-137. Available at:

<https://www.ncbi.nlm.nih.gov/pubmed/27800275>.



46. Jovanovic P, Mihajlovic M, Djordjevic-Jocic J, et al. Ocular melanoma: an overview of the current status. *Int J Clin Exp Pathol* 2013;6:1230-1244. Available at: <https://www.ncbi.nlm.nih.gov/pubmed/23826405>.

47. Mishra KK, Quivey JM, Daftari IK, et al. Long-term Results of the UCSF-LBNL Randomized Trial: Charged Particle With Helium Ion Versus Iodine-125 Plaque Therapy for Choroidal and Ciliary Body Melanoma. *Int J Radiat Oncol Biol Phys* 2015;92:376-383. Available at: <https://www.ncbi.nlm.nih.gov/pubmed/25841624>.

48. Onken MD, Worley LA, Char DH, et al. Collaborative Ocular Oncology Group report number 1: prospective validation of a multi-gene prognostic assay in uveal melanoma. *Ophthalmology* 2012;119:1596-1603. Available at: <https://www.ncbi.nlm.nih.gov/pubmed/22521086>.

49. Yousef YA, Finger PT. Predictive value of the seventh edition American Joint Committee on Cancer staging system for conjunctival melanoma. *Arch Ophthalmol* 2012;130:599-606. Available at: <https://www.ncbi.nlm.nih.gov/pubmed/22652846>.

50. Shields CL, Kaliki S, Al-Dahmash SA, et al. American Joint Committee on Cancer (AJCC) clinical classification predicts conjunctival melanoma outcomes. *Ophthalmic Plast Reconstr Surg* 2012;28:313-323. Available at: <https://www.ncbi.nlm.nih.gov/pubmed/22965011>.

51. Van Raamsdonk CD, Bezrookove V, Green G, et al. Frequent somatic mutations of GNAQ in uveal melanoma and blue naevi. *Nature* 2009;457:599-602. Available at: <https://www.ncbi.nlm.nih.gov/pubmed/19078957>.

52. Soparker CN, O'Brien JM, Albert DM. Investigation of the role of the ras protooncogene point mutation in human uveal melanomas. *Invest Ophthalmol Vis Sci* 1993;34:2203-2209. Available at: <https://www.ncbi.nlm.nih.gov/pubmed/8505202>.

53. Zuidervaart W, van Nieuwpoort F, Stark M, et al. Activation of the MAPK pathway is a common event in uveal melanomas although it rarely occurs through mutation of BRAF or RAS. *Br J Cancer* 2005;92:2032-2038. Available at: <https://www.ncbi.nlm.nih.gov/pubmed/15928660>.

54. Rimoldi D, Salvi S, Lienard D, et al. Lack of BRAF mutations in uveal melanoma. *Cancer Res* 2003;63:5712-5715. Available at: <https://www.ncbi.nlm.nih.gov/pubmed/14522889>.

55. Gear H, Williams H, Kemp EG, Roberts F. BRAF mutations in conjunctival melanoma. *Invest Ophthalmol Vis Sci* 2004;45:2484-2488. Available at: <https://www.ncbi.nlm.nih.gov/pubmed/15277467>.

56. Lake SL, Jmor F, Dopierala J, et al. Multiplex ligation-dependent probe amplification of conjunctival melanoma reveals common BRAF V600E gene mutation and gene copy number changes. *Invest Ophthalmol Vis Sci* 2011;52:5598-5604. Available at: <https://www.ncbi.nlm.nih.gov/pubmed/21693616>.

57. Griewank KG, Westekemper H, Murali R, et al. Conjunctival melanomas harbor BRAF and NRAS mutations and copy number changes similar to cutaneous and mucosal melanomas. *Clin Cancer Res* 2013;19:3143-3152. Available at: <https://www.ncbi.nlm.nih.gov/pubmed/23633454>.

58. Larsen AC, Dahmcke CM, Dahl C, et al. A Retrospective Review of Conjunctival Melanoma Presentation, Treatment, and Outcome and an Investigation of Features Associated With BRAF Mutations. *JAMA Ophthalmol* 2015;133:1295-1303. Available at: <https://www.ncbi.nlm.nih.gov/pubmed/26425792>.

59. Beadling C, Jacobson-Dunlop E, Hodi FS, et al. KIT gene mutations and copy number in melanoma subtypes. *Clin Cancer Res* 2008;14:6821-6828. Available at: <https://www.ncbi.nlm.nih.gov/pubmed/18980976>.



60. Spendlove HE, Damato BE, Humphreys J, et al. BRAF mutations are detectable in conjunctival but not uveal melanomas. *Melanoma Res* 2004;14:449-452. Available at: <https://www.ncbi.nlm.nih.gov/pubmed/15577314>.

61. Goldenberg-Cohen N, Cohen Y, Rosenbaum E, et al. T1799A BRAF mutations in conjunctival melanocytic lesions. *Invest Ophthalmol Vis Sci* 2005;46:3027-3030. Available at: <https://www.ncbi.nlm.nih.gov/pubmed/16123397>.

62. Edmunds SC, Cree IA, Di Nicolantonio F, et al. Absence of BRAF gene mutations in uveal melanomas in contrast to cutaneous melanomas. *Br J Cancer* 2003;88:1403-1405. Available at: <https://www.ncbi.nlm.nih.gov/pubmed/12778069>.

63. Horkovicova K, Markus J, Krcova I, et al. [the Braf Mutation and the Possibilities of Uveal Melanoma Metastasizing Prognostic Markers Identification]. *Cesk Slov Oftalmol*;72:149-156. Available at: <https://www.ncbi.nlm.nih.gov/pubmed/27860480>.

64. Bauer J, Kilic E, Vaarwater J, et al. Oncogenic GNAQ mutations are not correlated with disease-free survival in uveal melanoma. *Br J Cancer* 2009;101:813-815. Available at: <https://www.ncbi.nlm.nih.gov/pubmed/19654573>.

65. Damato B, Dopierala JA, Coupland SE. Genotypic profiling of 452 choroidal melanomas with multiplex ligation-dependent probe amplification. *Clin Cancer Res* 2010;16:6083-6092. Available at: <https://www.ncbi.nlm.nih.gov/pubmed/20975103>.

66. Koopmans AE, Vaarwater J, Paridaens D, et al. Patient survival in uveal melanoma is not affected by oncogenic mutations in GNAQ and GNA11. *Br J Cancer* 2013;109:493-496. Available at: <https://www.ncbi.nlm.nih.gov/pubmed/23778528>.

67. Cassoux N, Rodrigues MJ, Plancher C, et al. Genome-wide profiling is a clinically relevant and affordable prognostic test in posterior uveal melanoma. *Br J Ophthalmol* 2014;98:769-774. Available at: <https://www.ncbi.nlm.nih.gov/pubmed/24169649>.

68. Caines R, Eleuteri A, Kalirai H, et al. Cluster analysis of multiplex ligation-dependent probe amplification data in choroidal melanoma. *Mol Vis* 2015;21:1-11. Available at: <https://www.ncbi.nlm.nih.gov/pubmed/25684974>.

69. Van Raamsdonk CD, Griewank KG, Crosby MB, et al. Mutations in GNA11 in uveal melanoma. *N Engl J Med* 2010;363:2191-2199. Available at: <https://www.ncbi.nlm.nih.gov/pubmed/21083380>.

70. Daniels AB, Lee JE, MacConaill LE, et al. High throughput mass spectrometry-based mutation profiling of primary uveal melanoma. *Invest Ophthalmol Vis Sci* 2012;53:6991-6996. Available at: <https://www.ncbi.nlm.nih.gov/pubmed/22977135>.

71. Harbour JW, Onken MD, Roberson ED, et al. Frequent mutation of BAP1 in metastasizing uveal melanomas. *Science* 2010;330:1410-1413. Available at: <https://www.ncbi.nlm.nih.gov/pubmed/21051595>.

72. Gupta MP, Lane AM, DeAngelis MM, et al. Clinical Characteristics of Uveal Melanoma in Patients With Germline BAP1 Mutations. *JAMA Ophthalmol* 2015;133:881-887. Available at: <https://www.ncbi.nlm.nih.gov/pubmed/25974357>.

73. Harbour JW, Roberson ED, Anbunathan H, et al. Recurrent mutations at codon 625 of the splicing factor SF3B1 in uveal melanoma. *Nat Genet* 2013;45:133-135. Available at: <https://www.ncbi.nlm.nih.gov/pubmed/23313955>.

74. Martin M, Masshofer L, Temming P, et al. Exome sequencing identifies recurrent somatic mutations in EIF1AX and SF3B1 in uveal melanoma with disomy 3. *Nat Genet* 2013;45:933-936. Available at: <https://www.ncbi.nlm.nih.gov/pubmed/23793026>.

75. Qiu M, Shields CL. Choroidal Nevus in the United States Adult Population: Racial Disparities and Associated Factors in the National Health and Nutrition Examination Survey. *Ophthalmology* 2015;122:2071-2083. Available at: <https://www.ncbi.nlm.nih.gov/pubmed/26255109>.



NCCN Guidelines Version 2.2021

Melanoma: Uveal

76. Sumich P, Mitchell P, Wang JJ. Choroidal nevi in a white population: the Blue Mountains Eye Study. *Arch Ophthalmol* 1998;116:645-650. Available at: <https://www.ncbi.nlm.nih.gov/pubmed/9596501>.

77. Smith RE, Ganley JP. Ophthalmic survey of a community. 1. Abnormalities of the ocular fundus. *Am J Ophthalmol* 1972;74:1126-1130. Available at: <https://www.ncbi.nlm.nih.gov/pubmed/4646717>.

78. Eskelin S, Kivela T. Mode of presentation and time to treatment of uveal melanoma in Finland. *Br J Ophthalmol* 2002;86:333-338. Available at: <https://www.ncbi.nlm.nih.gov/pubmed/11864894>.

79. Shields CL, Pefkianaki M, Mashayekhi A, et al. Cytogenetic results of choroidal nevus growth into melanoma in 55 consecutive cases. *Saudi J Ophthalmol* 2018;32:28-32. Available at: <https://www.ncbi.nlm.nih.gov/pubmed/29755268>.

80. Kivela T. Diagnosis of uveal melanoma. *Dev Ophthalmol* 2012;49:1-15. Available at: <https://www.ncbi.nlm.nih.gov/pubmed/22042009>.

81. Singh AD, Kalyani P, Topham A. Estimating the risk of malignant transformation of a choroidal nevus. *Ophthalmology* 2005;112:1784-1789. Available at: <https://www.ncbi.nlm.nih.gov/pubmed/16154197>.

82. Ganley JP, Comstock GW. Benign nevi and malignant melanomas of the choroid. *Am J Ophthalmol* 1973;76:19-25. Available at: <https://www.ncbi.nlm.nih.gov/pubmed/4717339>.

83. Factors predictive of growth and treatment of small choroidal melanoma: COMS Report No. 5. The Collaborative Ocular Melanoma Study Group. *Arch Ophthalmol* 1997;115:1537-1544. Available at: <https://www.ncbi.nlm.nih.gov/pubmed/9400787>.

84. Lane AM, Egan KM, Kim IK, Gragoudas ES. Mortality after diagnosis of small melanocytic lesions of the choroid. *Arch Ophthalmol* 2010;128:996-1000. Available at: <https://www.ncbi.nlm.nih.gov/pubmed/20696999>.

85. Li HK, Shields CL, Mashayekhi A, et al. Giant choroidal nevus clinical features and natural course in 322 cases. *Ophthalmology* 2010;117:324-333. Available at: <https://www.ncbi.nlm.nih.gov/pubmed/19969359>.

86. Shields CL, Dalvin LA, Yu MD, et al. Choroidal nevus transformation into melanoma per millimeter increment in thickness using multimodal imaging in 2355 cases: The 2019 Wendell L. Hughes Lecture. *Retina* 2019;39:1852-1860. Available at: <https://www.ncbi.nlm.nih.gov/pubmed/30883534>.

87. Shields CL, Dalvin LA, Ancona-Lezama D, et al. Choroidal nevus imaging features in 3,806 cases and risk factors for transformation in melanoma in 2,355 cases: The 2020 Taylor R. Smith and Victor T. Curtin Lecture. *Retina* 2019;39:1840-1851. Available at: <https://www.ncbi.nlm.nih.gov/pubmed/30608349>.

88. Augsburger JJ, Correa ZM, Schneider S, et al. Diagnostic transvitreal fine-needle aspiration biopsy of small melanocytic choroidal tumors in nevus versus melanoma category. *Trans Am Ophthalmol Soc* 2002;100:225-232; discussion 232-224. Available at: <https://www.ncbi.nlm.nih.gov/pubmed/12545696>.

89. Augsburger JJ, Correa ZM, Trichopoulos N, Shaikh A. Size overlap between benign melanocytic choroidal nevi and choroidal malignant melanomas. *Invest Ophthalmol Vis Sci* 2008;49:2823-2828. Available at: <https://www.ncbi.nlm.nih.gov/pubmed/18408179>.

90. Augsburger JJ, Schroeder RP, Territo C, et al. Clinical parameters predictive of enlargement of melanocytic choroidal lesions. *Br J Ophthalmol* 1989;73:911-917. Available at: <https://www.ncbi.nlm.nih.gov/pubmed/2605146>.

91. Shields CL, Shields JA, Kiratli H, et al. Risk factors for growth and metastasis of small choroidal melanocytic lesions. *Ophthalmology* 1995;102:1351-1361. Available at: <https://www.ncbi.nlm.nih.gov/pubmed/9097773>.



92. Shields CL, Cater J, Shields JA, et al. Combination of clinical factors predictive of growth of small choroidal melanocytic tumors. Arch Ophthalmol 2000;118:360-364. Available at: <https://www.ncbi.nlm.nih.gov/pubmed/10721958>.

93. Singh AD, Mokashi AA, Bena JF, et al. Small choroidal melanocytic lesions: features predictive of growth. Ophthalmology 2006;113:1032-1039. Available at: <https://www.ncbi.nlm.nih.gov/pubmed/16650475>.

94. Shields CL, Furuta M, Berman EL, et al. Choroidal nevus transformation into melanoma: analysis of 2514 consecutive cases. Arch Ophthalmol 2009;127:981-987. Available at: <https://www.ncbi.nlm.nih.gov/pubmed/19667334>.

95. Butler P, Char DH, Zarbin M, Kroll S. Natural history of indeterminate pigmented choroidal tumors. Ophthalmology 1994;101:710-716; discussion 717. Available at: <https://www.ncbi.nlm.nih.gov/pubmed/8152767>.

96. Dalvin LA, Shields CL, Ancona-Lezama DA, et al. Combination of multimodal imaging features predictive of choroidal nevus transformation into melanoma. Br J Ophthalmol 2019;103:1441-1447. Available at: <https://www.ncbi.nlm.nih.gov/pubmed/30523045>.

97. Mims JL, 3rd, Shields JA. Follow-up studies of suspicious choroidal nevi. Ophthalmology 1978;85:929-943. Available at: <https://www.ncbi.nlm.nih.gov/pubmed/733186>.

98. MacIwaine WAt, Anderson B, Jr., Klintworth GK. Enlargement of a histologically documented choroidal nevus. Am J Ophthalmol 1979;87:480-486. Available at: <https://www.ncbi.nlm.nih.gov/pubmed/443311>.

99. Mashayekhi A, Siu S, Shields CL, Shields JA. Slow enlargement of choroidal nevi: a long-term follow-up study. Ophthalmology 2011;118:382-388. Available at: <https://www.ncbi.nlm.nih.gov/pubmed/20801518>.

100. Dalvin LA, Shields CL, Pulido JS, et al. Uveal Melanoma Associated With Myotonic Dystrophy: A Report of 6 Cases. JAMA Ophthalmol 2018;136:543-547. Available at: <https://www.ncbi.nlm.nih.gov/pubmed/29596556>.

101. Velazquez-Martin JP, Pavlin CJ, Simpson ER. Association between uveal melanoma and myotonic dystrophy: a series of 3 cases. JAMA Ophthalmol 2013;131:246-249. Available at: <https://www.ncbi.nlm.nih.gov/pubmed/23411896>.

102. Win AK, Perattur PG, Pulido JS, et al. Increased cancer risks in myotonic dystrophy. Mayo Clin Proc 2012;87:130-135. Available at: <https://www.ncbi.nlm.nih.gov/pubmed/22237010>.

103. Fontcuberta IC, Salomao DR, Quiram PA, Pulido JS. Choroidal melanoma and lid fibrofolliculomas in Birt-Hogg-Dube syndrome. Ophthalmic Genet 2011;32:143-146. Available at: <https://www.ncbi.nlm.nih.gov/pubmed/21401403>.

104. Marous CL, Marous MR, Welch RJ, et al. Choroidal Melanoma, Sector Melanocytosis, and Retinal Pigment Epithelial Microdetachments in Birt-Hogg-Dube Syndrome. Retin Cases Brief Rep 2019;13:202-206. Available at: <https://www.ncbi.nlm.nih.gov/pubmed/28541267>.

105. Spees EK, Jr., Kramer KK, Light JA, et al. Reactivation of ocular malignant melanoma after renal transplantation. Transplantation 1980;29:421-424. Available at: <https://www.ncbi.nlm.nih.gov/pubmed/6990569>.

106. Shields JA, Narsipur SS, Shields CL, Sperber DE. Choroidal melanoma in an immunosuppressed child with minimal change nephrotic syndrome. Retina 2004;24:454-455. Available at: <https://www.ncbi.nlm.nih.gov/pubmed/15187671>.

107. Singh AD, De Potter P, Fijal BA, et al. Lifetime prevalence of uveal melanoma in white patients with oculo(dermal) melanocytosis. Ophthalmology 1998;105:195-198. Available at: <https://www.ncbi.nlm.nih.gov/pubmed/9442799>.



NCCN Guidelines Version 2.2021

Melanoma: Uveal

108. Gonder JR, Shields JA, Albert DM, et al. Uveal malignant melanoma associated with ocular and oculodermal melanocytosis. *Ophthalmology* 1982;89:953-960. Available at: <https://www.ncbi.nlm.nih.gov/pubmed/7133641>.
109. Singh AD, Shields CL, Shields JA, Sato T. Uveal melanoma in young patients. *Arch Ophthalmol* 2000;118:918-923. Available at: <https://www.ncbi.nlm.nih.gov/pubmed/10900104>.
110. Velazquez N, Jones IS. Ocular and oculodermal melanocytosis associated with uveal melanoma. *Ophthalmology* 1983;90:1472-1476. Available at: <https://www.ncbi.nlm.nih.gov/pubmed/6677847>.
111. Gonder JR, Ezell PC, Shields JA, Augsburger JJ. Ocular melanocytosis. A study to determine the prevalence rate of ocular melanocytosis. *Ophthalmology* 1982;89:950-952. Available at: <https://www.ncbi.nlm.nih.gov/pubmed/7133640>.
112. Shields CL, Kaliki S, Livesey M, et al. Association of ocular and oculodermal melanocytosis with the rate of uveal melanoma metastasis: analysis of 7872 consecutive eyes. *JAMA Ophthalmol* 2013;131:993-1003. Available at: <https://www.ncbi.nlm.nih.gov/pubmed/23681424>.
113. Singh AD, Shields CL, De Potter P, et al. Familial uveal melanoma. Clinical observations on 56 patients. *Arch Ophthalmol* 1996;114:392-399. Available at: <https://www.ncbi.nlm.nih.gov/pubmed/8602775>.
114. Abdel-Rahman MH, Pilarski R, Ezzat S, et al. Cancer family history characterization in an unselected cohort of 121 patients with uveal melanoma. *Fam Cancer* 2010;9:431-438. Available at: <https://www.ncbi.nlm.nih.gov/pubmed/20157784>.
115. Singh AD, Wang MX, Donoso LA, et al. Familial uveal melanoma, III. Is the occurrence of familial uveal melanoma coincidental? *Arch Ophthalmol* 1996;114:1101-1104. Available at: <https://www.ncbi.nlm.nih.gov/pubmed/8790096>.
116. Masoomian B, Shields JA, Shields CL. Overview of BAP1 cancer predisposition syndrome and the relationship to uveal melanoma. *J Curr Ophthalmol* 2018;30:102-109. Available at: <https://www.ncbi.nlm.nih.gov/pubmed/29988936>.
117. Helgadottir H, Hoim V. The genetics of uveal melanoma: current insights. *Appl Clin Genet* 2016;9:147-155. Available at: <https://www.ncbi.nlm.nih.gov/pubmed/27660484>.
118. Wang A, Papneja A, Hyrcza M, et al. Gene of the month: BAP1. *J Clin Pathol* 2016;69:750-753. Available at: <https://www.ncbi.nlm.nih.gov/pubmed/27235536>.
119. Harbour JW. The genetics of uveal melanoma: an emerging framework for targeted therapy. *Pigment Cell Melanoma Res* 2012;25:171-181. Available at: <https://www.ncbi.nlm.nih.gov/pubmed/22268848>.
120. Carbone M, Ferris LK, Baumann F, et al. BAP1 cancer syndrome: malignant mesothelioma, uveal and cutaneous melanoma, and MBLTs. *J Transl Med* 2012;10:179. Available at: <https://www.ncbi.nlm.nih.gov/pubmed/22935333>.
121. Foretova L, Navratilova M, Svoboda M, et al. BAP1 Syndrome - Predisposition to Malignant Mesothelioma, Skin and Uveal Melanoma, Renal and Other Cancers. *Klin Onkol* 2019;32:118-122. Available at: <https://www.ncbi.nlm.nih.gov/pubmed/31409087>.
122. Boru G, Grosel TW, Pilarski R, et al. Germline large deletion of BAP1 and decreased expression in non-tumor choroid in uveal melanoma patients with high risk for inherited cancer. *Genes Chromosomes Cancer* 2019;58:650-656. Available at: <https://www.ncbi.nlm.nih.gov/pubmed/30883995>.
123. Haugh AM, Njauw CN, Bublej JA, et al. Genotypic and Phenotypic Features of BAP1 Cancer Syndrome: A Report of 8 New Families and Review of Cases in the Literature. *JAMA Dermatol* 2017;153:999-1006. Available at: <https://www.ncbi.nlm.nih.gov/pubmed/28793149>.



NCCN Guidelines Version 2.2021

Melanoma: Uveal

124. Pilarski R, Cebulla CM, Massengill JB, et al. Expanding the clinical phenotype of hereditary BAP1 cancer predisposition syndrome, reporting three new cases. *Genes Chromosomes Cancer* 2014;53:177-182. Available at: <https://www.ncbi.nlm.nih.gov/pubmed/24243779>.

125. Walpole S, Pritchard AL, Cebulla CM, et al. Comprehensive Study of the Clinical Phenotype of Germline BAP1 Variant-Carrying Families Worldwide. *J Natl Cancer Inst* 2018;110:1328-1341. Available at: <https://www.ncbi.nlm.nih.gov/pubmed/30517737>.

126. Pilarski R, Carlo M, Cebulla C, Abdel-Rahman M. BAP1 Tumor Predisposition Syndrome. In: Adam MP, Ardinger HH, Pagon RA, et al., eds. *GeneReviews*((R)). Seattle (WA); 1993.

127. Wiesner T, Obenaus AC, Murali R, et al. Germline mutations in BAP1 predispose to melanocytic tumors. *Nat Genet* 2011;43:1018-1021. Available at: <https://www.ncbi.nlm.nih.gov/pubmed/21874003>.

128. O'Shea SJ, Robles-Espinoza CD, McLellan L, et al. A population-based analysis of germline BAP1 mutations in melanoma. *Hum Mol Genet* 2017;26:717-728. Available at: <https://www.ncbi.nlm.nih.gov/pubmed/28062663>.

129. Rai K, Pilarski R, Cebulla CM, Abdel-Rahman MH. Comprehensive review of BAP1 tumor predisposition syndrome with report of two new cases. *Clin Genet* 2016;89:285-294. Available at: <https://www.ncbi.nlm.nih.gov/pubmed/26096145>.

130. Carbone M, Flores EG, Emi M, et al. Combined Genetic and Genealogic Studies Uncover a Large BAP1 Cancer Syndrome Kindred Tracing Back Nine Generations to a Common Ancestor from the 1700s. *PLoS Genet* 2015;11:e1005633. Available at: <https://www.ncbi.nlm.nih.gov/pubmed/26683624>.

131. Njauw CN, Kim I, Piris A, et al. Germline BAP1 inactivation is preferentially associated with metastatic ocular melanoma and cutaneous-ocular melanoma families. *PLoS One* 2012;7:e35295. Available at: <https://www.ncbi.nlm.nih.gov/pubmed/22545102>.

132. Testa JR, Cheung M, Pei J, et al. Germline BAP1 mutations predispose to malignant mesothelioma. *Nat Genet* 2011;43:1022-1025. Available at: <https://www.ncbi.nlm.nih.gov/pubmed/21874000>.

133. Abdel-Rahman MH, Sample KM, Pilarski R, et al. Whole Exome Sequencing Identifies Candidate Genes Associated with Hereditary Predisposition to Uveal Melanoma. *Ophthalmology* 2020;127:668-678. Available at: <https://www.ncbi.nlm.nih.gov/pubmed/32081490>.

134. Derrien AC, Rodrigues M, Eeckhoutte A, et al. Germline MBD4 Mutations and Predisposition to Uveal Melanoma. *J Natl Cancer Inst* 2021;113:80-87. Available at: <https://www.ncbi.nlm.nih.gov/pubmed/32239153>.

135. Rodrigues M, Mobuchon L, Houy A, et al. Evolutionary Routes in Metastatic Uveal Melanomas Depend on MBD4 Alterations. *Clin Cancer Res* 2019;25:5513-5524. Available at: <https://www.ncbi.nlm.nih.gov/pubmed/31227496>.

136. Repo P, Jantti JE, Jarvinen RS, et al. Germline loss-of-function variants in MBD4 are rare in Finnish patients with uveal melanoma. *Pigment Cell Melanoma Res* 2020;33:756-762. Available at: <https://www.ncbi.nlm.nih.gov/pubmed/32421892>.

137. Rodrigues M, Mobuchon L, Houy A, et al. Outlier response to anti-PD1 in uveal melanoma reveals germline MBD4 mutations in hypermutated tumors. *Nat Commun* 2018;9:1866. Available at: <https://www.ncbi.nlm.nih.gov/pubmed/29760383>.

138. Mataftsi A, Zografos L, Chamot L, Schalenbourg A. [Choroidal melanoma in neurofibromatosis type 2: description of a case]. *J Fr Ophtalmol* 2003;26:477-480. Available at: <https://www.ncbi.nlm.nih.gov/pubmed/12819605>.

139. Friedman SM, Margo CE. Choroidal melanoma and neurofibromatosis type 1. *Arch Ophthalmol* 1998;116:694-695. Available at: <https://www.ncbi.nlm.nih.gov/pubmed/9596516>.



140. Antle CM, Damji KF, White VA, Rootman J. Uveal malignant melanoma and optic nerve glioma in von Recklinghausen's neurofibromatosis. *Br J Ophthalmol* 1990;74:502-504. Available at: <https://www.ncbi.nlm.nih.gov/pubmed/2117971>.

141. Specht CS, Smith TW. Uveal malignant melanoma and von Recklinghausen's neurofibromatosis. *Cancer* 1988;62:812-817. Available at: <https://www.ncbi.nlm.nih.gov/pubmed/3135111>.

142. Croxatto JO, Charles DE, Malbran ES. Neurofibromatosis associated with nevus of Ota and choroidal melanoma. *Am J Ophthalmol* 1981;92:578-580. Available at: <https://www.ncbi.nlm.nih.gov/pubmed/6794373>.

143. Wiznia RA, Freedman JK, Mancini AD, Shields JA. Malignant melanoma of the choroid in neurofibromatosis. *Am J Ophthalmol* 1978;86:684-687. Available at: <https://www.ncbi.nlm.nih.gov/pubmed/102202>.

144. Nordmann J, Brini A. Von Recklinghausen's disease and melanoma of the uvea. *Br J Ophthalmol* 1970;54:641-648. Available at: <https://www.ncbi.nlm.nih.gov/pubmed/4990591>.

145. Yanoff M, Zimmerman LE. Histogenesis of malignant melanomas of the uvea. 3. The relationship of congenital ocular melanocytosis and neurofibromatosis in uveal melanomas. *Arch Ophthalmol* 1967;77:331-336. Available at: <https://www.ncbi.nlm.nih.gov/pubmed/6019552>.

146. Honavar SG, Singh AD, Shields CL, et al. Iris melanoma in a patient with neurofibromatosis. *Surv Ophthalmol* 2000;45:231-236. Available at: <https://www.ncbi.nlm.nih.gov/pubmed/11094247>.

147. Nayman T, Bostan C, Logan P, Burnier MN, Jr. Uveal Melanoma Risk Factors: A Systematic Review of Meta-Analyses. *Curr Eye Res* 2017;42:1085-1093. Available at: <https://www.ncbi.nlm.nih.gov/pubmed/28494168>.

148. Weis E, Shah CP, Lajous M, et al. The association of cutaneous and iris nevi with uveal melanoma: a meta-analysis. *Ophthalmology* 2009;116:536-543 e532. Available at: <https://www.ncbi.nlm.nih.gov/pubmed/19167086>.

149. Smith JH, Padnick-Silver L, Newlin A, et al. Genetic study of familial uveal melanoma: association of uveal and cutaneous melanoma with cutaneous and ocular nevi. *Ophthalmology* 2007;114:774-779. Available at: <https://www.ncbi.nlm.nih.gov/pubmed/17207529>.

150. van Hees CL, de Boer A, Jager MJ, et al. Are atypical nevi a risk factor for uveal melanoma? A case-control study. *J Invest Dermatol* 1994;103:202-205. Available at: <https://www.ncbi.nlm.nih.gov/pubmed/8040610>.

151. Richtig E, Langmann G, Mullner K, Smolle J. Ocular melanoma: epidemiology, clinical presentation and relationship with dysplastic nevi. *Ophthalmologica* 2004;218:111-114. Available at: <https://www.ncbi.nlm.nih.gov/pubmed/15004500>.

152. Seddon JM, Gragoudas ES, Glynn RJ, et al. Host factors, UV radiation, and risk of uveal melanoma. A case-control study. *Arch Ophthalmol* 1990;108:1274-1280. Available at: <https://www.ncbi.nlm.nih.gov/pubmed/2400347>.

153. Bataille V, Pinney E, Hungerford JL, et al. Five cases of coexistent primary ocular and cutaneous melanoma. *Arch Dermatol* 1993;129:198-201. Available at: <https://www.ncbi.nlm.nih.gov/pubmed/8434978>.

154. Bataille V, Sasieni P, Cuzick J, et al. Risk of ocular melanoma in relation to cutaneous and iris naevi. *Int J Cancer* 1995;60:622-626. Available at: <https://www.ncbi.nlm.nih.gov/pubmed/7860135>.

155. van Hees CL, Jager MJ, Bleeker JC, et al. Occurrence of cutaneous and uveal melanoma in patients with uveal melanoma and their first degree relatives. *Melanoma Res* 1998;8:175-180. Available at: <https://www.ncbi.nlm.nih.gov/pubmed/9610873>.



NCCN Guidelines Version 2.2021

Melanoma: Uveal

156. Lischko AM, Seddon JM, Gragoudas ES, et al. Evaluation of prior primary malignancy as a determinant of uveal melanoma. A case-control study. *Ophthalmology* 1989;96:1716-1721. Available at: <https://www.ncbi.nlm.nih.gov/pubmed/2622616>.

157. Shors AR, Iwamoto S, Doody DR, Weiss NS. Relationship of uveal and cutaneous malignant melanoma in persons with multiple primary tumors. *Int J Cancer* 2002;102:266-268. Available at: <https://www.ncbi.nlm.nih.gov/pubmed/12397648>.

158. Hemminki K, Zhang H, Czene K. Association of first ocular melanoma with subsequent cutaneous melanoma: results from the Swedish Family-Cancer Database. *Int J Cancer* 2003;104:257-258. Available at: <https://www.ncbi.nlm.nih.gov/pubmed/12569585>.

159. Scelo G, Boffetta P, Autier P, et al. Associations between ocular melanoma and other primary cancers: an international population-based study. *Int J Cancer* 2007;120:152-159. Available at: <https://www.ncbi.nlm.nih.gov/pubmed/17036322>.

160. Bergman L, Nilsson B, Ragnarsson-Olding B, Seregard S. Uveal melanoma: a study on incidence of additional cancers in the Swedish population. *Invest Ophthalmol Vis Sci* 2006;47:72-77. Available at: <https://www.ncbi.nlm.nih.gov/pubmed/16384946>.

161. Spanogle JP, Clarke CA, Aroner S, Swetter SM. Risk of second primary malignancies following cutaneous melanoma diagnosis: a population-based study. *J Am Acad Dermatol* 2010;62:757-767. Available at: <https://www.ncbi.nlm.nih.gov/pubmed/20223559>.

162. Lains I, Bartosch C, Mondim V, et al. Second Primary Neoplasms in Patients With Uveal Melanoma: A SEER Database Analysis. *Am J Ophthalmol* 2016;165:54-64. Available at: <https://www.ncbi.nlm.nih.gov/pubmed/26940164>.

163. Swerdlow AJ, Storm HH, Sasieni PD. Risks of second primary malignancy in patients with cutaneous and ocular melanoma in Denmark, 1943-1989. *Int J Cancer* 1995;61:773-779. Available at: <https://www.ncbi.nlm.nih.gov/pubmed/7790110>.

164. Damato B. Detection of uveal melanoma by optometrists in the United Kingdom. *Ophthalmic Physiol Opt* 2001;21:268-271. Available at: <https://www.ncbi.nlm.nih.gov/pubmed/11430620>.

165. Ah-Fat FG, Damato BE. Delays in the diagnosis of uveal melanoma and effect on treatment. *Eye (Lond)* 1998;12 (Pt 5):781-782. Available at: <https://www.ncbi.nlm.nih.gov/pubmed/10070508>.

166. Vidal JL, Bacin F, Albuissou E, et al. ["Melanoma 92". epidemiological study of uveal melanoma in France]. *J Fr Ophtalmol* 1995;18:520-528. Available at: <https://www.ncbi.nlm.nih.gov/pubmed/7560797>.

167. Accuracy of diagnosis of choroidal melanomas in the Collaborative Ocular Melanoma Study. COMS report no. 1. *Arch Ophthalmol* 1990;108:1268-1273. Available at: <https://www.ncbi.nlm.nih.gov/pubmed/2205183>.

168. Collaborative Ocular Melanoma Study G, Boldt HC, Byrne SF, et al. Baseline echographic characteristics of tumors in eyes of patients enrolled in the Collaborative Ocular Melanoma Study: COMS report no. 29. *Ophthalmology* 2008;115:1390-1397, 1397 e1391-1392. Available at: <https://www.ncbi.nlm.nih.gov/pubmed/18267342>.

169. Bove R, Char DH. Nondiagnosed uveal melanomas. *Ophthalmology* 2004;111:554-557. Available at: <https://www.ncbi.nlm.nih.gov/pubmed/15019335>.

170. Grisanti S, Tura A. Uveal Melanoma. In: Scott JF, Gerstenblith MR, eds. *Noncutaneous Melanoma*. Brisbane (AU): Codon Publications; 2018.

171. Damato B. Progress in the management of patients with uveal melanoma. The 2012 Ashton Lecture. *Eye (Lond)* 2012;26:1157-1172. Available at: <https://www.ncbi.nlm.nih.gov/pubmed/22744385>.



NCCN Guidelines Version 2.2021

Melanoma: Uveal

172. Demirci H, Shields CL, Shields JA, et al. Ring melanoma of the ciliary body: report on twenty-three patients. *Retina* 2002;22:698-706; quiz 852-693. Available at: <https://www.ncbi.nlm.nih.gov/pubmed/12476094>.

173. Shields CL, Kaliki S, Furuta M, et al. Clinical spectrum and prognosis of uveal melanoma based on age at presentation in 8,033 cases. *Retina* 2012;32:1363-1372. Available at: <https://www.ncbi.nlm.nih.gov/pubmed/22466491>.

174. Shields JA, Augsburger JJ, Brown GC, Stephens RF. The differential diagnosis of posterior uveal melanoma. *Ophthalmology* 1980;87:518-522. Available at: <https://www.ncbi.nlm.nih.gov/pubmed/7413140>.

175. Shields JA, Mashayekhi A, Ra S, Shields CL. Pseudomelanomas of the posterior uveal tract: the 2006 Taylor R. Smith Lecture. *Retina* 2005;25:767-771. Available at: <https://www.ncbi.nlm.nih.gov/pubmed/16141866>.

176. Ghassemi F, Bazvand F, Hosseini SS. Pseudomelanoma at a referral center in iran. *J Ophthalmic Vis Res* 2014;9:50-53. Available at: <https://www.ncbi.nlm.nih.gov/pubmed/24982732>.

177. Saari JM, Kivela T, Summanen P, et al. Digital imaging in differential diagnosis of small choroidal melanoma. *Graefes Arch Clin Exp Ophthalmol* 2006;244:1581-1590. Available at: <https://www.ncbi.nlm.nih.gov/pubmed/16636839>.

178. Freedman MI, Folk JC. Metastatic tumors to the eye and orbit. Patient survival and clinical characteristics. *Arch Ophthalmol* 1987;105:1215-1219. Available at: <https://www.ncbi.nlm.nih.gov/pubmed/3307718>.

179. Shields CL, Shields JA, Gross NE, et al. Survey of 520 eyes with uveal metastases. *Ophthalmology* 1997;104:1265-1276. Available at: <https://www.ncbi.nlm.nih.gov/pubmed/9261313>.

180. Shields CL, Welch RJ, Malik K, et al. Uveal Metastasis: Clinical Features and Survival Outcome of 2214 Tumors in 1111 Patients Based on Primary Tumor Origin. *Middle East Afr J Ophthalmol* 2018;25:81-90. Available at: <https://www.ncbi.nlm.nih.gov/pubmed/30122853>.

181. Nathan P, Cohen V, Coupland S, et al. Uveal Melanoma UK National Guidelines. *Eur J Cancer* 2015;51:2404-2412. Available at: <https://www.ncbi.nlm.nih.gov/pubmed/26278648>.

182. Golebiewska J, Kecik D, Turczynska M, et al. Optical coherence tomography in diagnosing, differentiating and monitoring of choroidal nevi - 1 year observational study. *Neuro Endocrinol Lett* 2013;34:539-542. Available at: <https://www.ncbi.nlm.nih.gov/pubmed/24378457>.

183. Muller K, Nowak PJ, de Pan C, et al. Effectiveness of fractionated stereotactic radiotherapy for uveal melanoma. *Int J Radiat Oncol Biol Phys* 2005;63:116-122. Available at: <https://www.ncbi.nlm.nih.gov/pubmed/16111579>.

184. Heilemann G, Fetty L, Blaickner M, et al. Retina dose as a predictor for visual acuity loss in (106)Ru eye plaque brachytherapy of uveal melanomas. *Radiother Oncol* 2018;127:379-384. Available at: <https://www.ncbi.nlm.nih.gov/pubmed/29452902>.

185. American Brachytherapy Society - Ophthalmic Oncology Task Force. Electronic address pec, Committee AO. The American Brachytherapy Society consensus guidelines for plaque brachytherapy of uveal melanoma and retinoblastoma. *Brachytherapy* 2014;13:1-14. Available at: <https://www.ncbi.nlm.nih.gov/pubmed/24373763>.

186. Melia BM, Abramson DH, Albert DM, et al. Collaborative ocular melanoma study (COMS) randomized trial of I-125 brachytherapy for medium choroidal melanoma. I. Visual acuity after 3 years COMS report no. 16. *Ophthalmology* 2001;108:348-366. Available at: <https://www.ncbi.nlm.nih.gov/pubmed/11158813>.



NCCN Guidelines Version 2.2021

Melanoma: Uveal

187. Jampol LM, Moy CS, Murray TG, et al. The COMS randomized trial of iodine 125 brachytherapy for choroidal melanoma: IV. Local treatment failure and enucleation in the first 5 years after brachytherapy. COMS report no. 19. *Ophthalmology* 2002;109:2197-2206. Available at: <https://www.ncbi.nlm.nih.gov/pubmed/12466159>.

188. Dieckmann K, Georg D, Zehetmayer M, et al. Stereotactic photon beam irradiation of uveal melanoma: indications and experience at the University of Vienna since 1997. *Strahlenther Onkol* 2007;183 Spec No 2:11-13. Available at: <https://www.ncbi.nlm.nih.gov/pubmed/18166998>.

189. Muscat S, Parks S, Kemp E, Keating D. Secondary retinal changes associated with choroidal naevi and melanomas documented by optical coherence tomography. *Br J Ophthalmol* 2004;88:120-124. Available at: <https://www.ncbi.nlm.nih.gov/pubmed/14693788>.

190. Muftuoglu IK, Gaber R, Bartsch DU, et al. Comparison of conventional color fundus photography and multicolor imaging in choroidal or retinal lesions. *Graefes Arch Clin Exp Ophthalmol* 2018;256:643-649. Available at: <https://www.ncbi.nlm.nih.gov/pubmed/29492687>.

191. Albertus DL, Schachar IH, Zahid S, et al. Autofluorescence quantification of benign and malignant choroidal nevi and melanocytic tumors. *JAMA Ophthalmol* 2013;131:1004-1008. Available at: <https://www.ncbi.nlm.nih.gov/pubmed/23787920>.

192. Garcia MD, Salomao DR, Marmorstein AD, Pulido JS. Histopathologic Findings in the Areas of Orange Pigment Overlying Choroidal Melanomas. *Transl Vis Sci Technol* 2016;5:4. Available at: <https://www.ncbi.nlm.nih.gov/pubmed/27190699>.

193. Meyer K, Augsburger JJ. Independent diagnostic value of fluorescein angiography in the evaluation of intraocular tumors. *Graefes Arch Clin Exp Ophthalmol* 1999;237:489-494. Available at: <https://www.ncbi.nlm.nih.gov/pubmed/10379610>.

194. Skalkicky SE, Holt PE, Giblin M, et al. Australian Cancer Network clinical practice guidelines for the management of ocular and periocular melanoma: an evidence-based literature analysis. *Clin Exp Ophthalmol* 2008;36:646-658. Available at: <https://www.ncbi.nlm.nih.gov/pubmed/18983550>.

195. Yonekawa Y, Kim IK. Epidemiology and management of uveal melanoma. *Hematol Oncol Clin North Am* 2012;26:1169-1184. Available at: <https://www.ncbi.nlm.nih.gov/pubmed/23116575>.

196. Chattopadhyay C, Kim DW, Gombos DS, et al. Uveal melanoma: From diagnosis to treatment and the science in between. *Cancer* 2016;122:2299-2312. Available at: <https://www.ncbi.nlm.nih.gov/pubmed/26991400>.

197. Fuller DG, Snyder WB, Hutton WL, Vaiser A. Ultrasonographic features of choroidal malignant melanomas. *Arch Ophthalmol* 1979;97:1465-1472. Available at: <https://www.ncbi.nlm.nih.gov/pubmed/464871>.

198. Bedi DG, Gombos DS, Ng CS, Singh S. Sonography of the eye. *AJR Am J Roentgenol* 2006;187:1061-1072. Available at: <https://www.ncbi.nlm.nih.gov/pubmed/16985158>.

199. Delgado S, Rodriguez Reyes A, Mora Rios L, et al. Ultrasound, histopathological, and genetic features of uveal melanoma in a Mexican-Mestizo population. *Arch Soc Esp Oftalmol (Engl Ed)* 2018;93:15-21. Available at: <https://www.ncbi.nlm.nih.gov/pubmed/28728954>.

200. Collaborative Ocular Melanoma Study G. Comparison of clinical, echographic, and histopathological measurements from eyes with medium-sized choroidal melanoma in the collaborative ocular melanoma study: COMS report no. 21. *Arch Ophthalmol* 2003;121:1163-1171. Available at: <https://www.ncbi.nlm.nih.gov/pubmed/12912695>.

201. Ossoinig KC. Standardized echography: basic principles, clinical applications, and results. *Int Ophthalmol Clin* 1979;19:127-210. Available at: <https://www.ncbi.nlm.nih.gov/pubmed/395120>.



202. Sobottka B, Schlote T, Krumpaszky HG, Kreissig I. Choroidal metastases and choroidal melanomas: comparison of ultrasonographic findings. *Br J Ophthalmol* 1998;82:159-161. Available at: <https://www.ncbi.nlm.nih.gov/pubmed/9613382>.

203. Materin MA, Raducu R, Bianciotto C, Shields CL. Fundus autofluorescence and optical coherence tomography findings in choroidal melanocytic lesions. *Middle East Afr J Ophthalmol* 2010;17:201-206. Available at: <https://www.ncbi.nlm.nih.gov/pubmed/20844674>.

204. Muskens RP, Van Best JA, Bleeker JC, Keunen JE. Corneal autofluorescence in choroidal melanoma or in choroidal naevus. *Br J Ophthalmol* 2001;85:662-665. Available at: <https://www.ncbi.nlm.nih.gov/pubmed/11371483>.

205. Shields CL, Bianciotto C, Pirondini C, et al. Autofluorescence of choroidal melanoma in 51 cases. *Br J Ophthalmol* 2008;92:617-622. Available at: <https://www.ncbi.nlm.nih.gov/pubmed/18441171>.

206. Cennamo G, Romano MR, Velotti N, et al. Fundus autofluorescence of choroidal nevi and melanoma. *Acta Ophthalmol* 2018;96:e102-e104. Available at: <https://www.ncbi.nlm.nih.gov/pubmed/28205424>.

207. Gunduz K, Pulido JS, Ezzat K, et al. Review of fundus autofluorescence in choroidal melanocytic lesions. *Eye (Lond)* 2009;23:497-503. Available at: <https://www.ncbi.nlm.nih.gov/pubmed/18670456>.

208. Lavinsky D, Belfort RN, Navajas E, et al. Fundus autofluorescence of choroidal nevus and melanoma. *Br J Ophthalmol* 2007;91:1299-1302. Available at: <https://www.ncbi.nlm.nih.gov/pubmed/17431017>.

209. Gunduz K, Pulido JS, Bakri SJ, Petit-Fond E. Fundus autofluorescence in choroidal melanocytic lesions. *Retina* 2007;27:681-687. Available at: <https://www.ncbi.nlm.nih.gov/pubmed/17621175>.

210. Shields CL, Pirondini C, Bianciotto C, et al. Autofluorescence of choroidal nevus in 64 cases. *Retina* 2008;28:1035-1043. Available at: <https://www.ncbi.nlm.nih.gov/pubmed/18779708>.

211. Salvanos P, Utheim TP, Moe MC, et al. Autofluorescence imaging in the differential diagnosis of optic disc melanocytoma. *Acta Ophthalmol* 2015;93:476-480. Available at: <https://www.ncbi.nlm.nih.gov/pubmed/25923254>.

212. Singh AD, Belfort RN, Sayanagi K, Kaiser PK. Fourier domain optical coherence tomographic and auto-fluorescence findings in indeterminate choroidal melanocytic lesions. *Br J Ophthalmol* 2010;94:474-478. Available at: <https://www.ncbi.nlm.nih.gov/pubmed/19822920>.

213. Crema H, Habal S, Gonzalez JE, Pavlin CJ. Role of optical coherence tomography in verifying the specificity of ultrasonography in detecting subtle subretinal fluid associated with small choroidal melanocytic tumors. *Retina* 2014;34:360-365. Available at: <https://www.ncbi.nlm.nih.gov/pubmed/23807190>.

214. Shah SU, Kaliki S, Shields CL, et al. Enhanced depth imaging optical coherence tomography of choroidal nevus in 104 cases. *Ophthalmology* 2012;119:1066-1072. Available at: <https://www.ncbi.nlm.nih.gov/pubmed/22297027>.

215. Shields CL, Kaliki S, Rojanaporn D, et al. Enhanced depth imaging optical coherence tomography of small choroidal melanoma: comparison with choroidal nevus. *Arch Ophthalmol* 2012;130:850-856. Available at: <https://www.ncbi.nlm.nih.gov/pubmed/22776921>.

216. Filloy A, Caminal JM, Arias L, et al. Swept source optical coherence tomography imaging of a series of choroidal tumours. *Can J Ophthalmol* 2015;50:242-248. Available at: <https://www.ncbi.nlm.nih.gov/pubmed/26040226>.

217. Espinoza G, Rosenblatt B, Harbour JW. Optical coherence tomography in the evaluation of retinal changes associated with suspicious choroidal melanocytic tumors. *Am J Ophthalmol* 2004;137:90-95. Available at: <https://www.ncbi.nlm.nih.gov/pubmed/14700649>.



218. Sayanagi K, Pelayes DE, Kaiser PK, Singh AD. 3D Spectral domain optical coherence tomography findings in choroidal tumors. *Eur J Ophthalmol* 2011;21:271-275. Available at: <https://www.ncbi.nlm.nih.gov/pubmed/21038307>.
219. Leshno A, Vishnevskia-Dai V, Barak A, et al. Optical Density Ratio of the Subretinal Fluid in Choroidal Melanoma and Metastasis. *Retina* 2019;39:685-691. Available at: <https://www.ncbi.nlm.nih.gov/pubmed/29252972>.
220. Toledo JJ, Asencio M, Garcia JR, et al. OCT Angiography: Imaging of Choroidal and Retinal Tumors. *Ophthalmol Retina* 2018;2:613-622. Available at: <https://www.ncbi.nlm.nih.gov/pubmed/31047615>.
221. Garcia-Arumi Fuste C, Peralta Iturburu F, Garcia-Arumi J. Is optical coherence tomography angiography helpful in the differential diagnosis of choroidal nevus versus melanoma? *Eur J Ophthalmol* 2020;30:723-729. Available at: <https://www.ncbi.nlm.nih.gov/pubmed/31210061>.
222. Bianciotto C, Shields CL, Guzman JM, et al. Assessment of anterior segment tumors with ultrasound biomicroscopy versus anterior segment optical coherence tomography in 200 cases. *Ophthalmology* 2011;118:1297-1302. Available at: <https://www.ncbi.nlm.nih.gov/pubmed/21377736>.
223. Augsburger JJ, Golden MI, Shields JA. Fluorescein angiography of choroidal malignant melanomas with retinal invasion. *Retina* 1984;4:232-241. Available at: <https://www.ncbi.nlm.nih.gov/pubmed/6531518>.
224. Sallet G, Amoaku WM, Lafaut BA, et al. Indocyanine green angiography of choroidal tumors. *Graefes Arch Clin Exp Ophthalmol* 1995;233:677-689. Available at: <https://www.ncbi.nlm.nih.gov/pubmed/8566823>.
225. Shields CL, Pellegrini M, Kligman BE, et al. Ciliary body and choroidal pseudomelanoma from ultrasonographic imaging of hypermature cataract in 20 cases. *Ophthalmology* 2013;120:2546-2551. Available at: <https://www.ncbi.nlm.nih.gov/pubmed/23916484>.
226. Polivogianis L, Seddon JM, Glynn RJ, et al. Comparison of transillumination and histologic slide measurements of tumor diameter in uveal melanoma. *Ophthalmology* 1988;95:1576-1582. Available at: <https://www.ncbi.nlm.nih.gov/pubmed/3062526>.
227. Recsan Z, Karlinger K, Fodor M, et al. MRI for the evaluation of scleral invasion and extrascleral extension of uveal melanomas. *Clin Radiol* 2002;57:371-376. Available at: <https://www.ncbi.nlm.nih.gov/pubmed/12014934>.
228. Wang Y, Li YY, Su F, Xiao LH. [Clinical observation of extraocular extension of choroidal melanoma]. *Zhonghua Yan Ke Za Zhi* 2011;47:242-247. Available at: <https://www.ncbi.nlm.nih.gov/pubmed/21609626>.
229. Nguyen HG, Sznitman R, Maeder P, et al. Personalized Anatomic Eye Model From T1-Weighted Volume Interpolated Gradient Echo Magnetic Resonance Imaging of Patients With Uveal Melanoma. *Int J Radiat Oncol Biol Phys* 2018;102:813-820. Available at: <https://www.ncbi.nlm.nih.gov/pubmed/29970318>.
230. Zoberi JE, Garcia-Ramirez J, Hedrick S, et al. MRI-based treatment planning and dose delivery verification for intraocular melanoma brachytherapy. *Brachytherapy* 2018;17:31-39. Available at: <https://www.ncbi.nlm.nih.gov/pubmed/28818442>.
231. Bagger MM. Intraocular biopsy of uveal melanoma Risk assessment and identification of genetic prognostic markers. *Acta Ophthalmol* 2018;96 Suppl A112:1-28. Available at: <https://www.ncbi.nlm.nih.gov/pubmed/30133961>.
232. Kim RS, Chevez-Barrios P, Divatia M, et al. Yield, Techniques, and Complications of Transvitreal and Transscleral Biopsies in Small Uveal Melanoma. *JAMA Ophthalmol* 2018;136:482-488. Available at: <https://www.ncbi.nlm.nih.gov/pubmed/29596552>.



NCCN Guidelines Version 2.2021

Melanoma: Uveal

233. Singh AD, Medina CA, Singh N, et al. Fine-needle aspiration biopsy of uveal melanoma: outcomes and complications. *Br J Ophthalmol* 2016;100:456-462. Available at: <https://www.ncbi.nlm.nih.gov/pubmed/26231747>.

234. Grixti A, Angi M, Damato BE, et al. Vitreoretinal surgery for complications of choroidal tumor biopsy. *Ophthalmology* 2014;121:2482-2488. Available at: <https://www.ncbi.nlm.nih.gov/pubmed/25085629>.

235. Sellam A, Desjardins L, Barnhill R, et al. Fine Needle Aspiration Biopsy in Uveal Melanoma: Technique, Complications, and Outcomes. *Am J Ophthalmol* 2016;162:28-34 e21. Available at: <https://www.ncbi.nlm.nih.gov/pubmed/26556006>.

236. Augsburger JJ, Correa ZM, Augsburger BD. Frequency and implications of discordant gene expression profile class in posterior uveal melanomas sampled by fine needle aspiration biopsy. *Am J Ophthalmol* 2015;159:248-256. Available at: <https://www.ncbi.nlm.nih.gov/pubmed/25448994>.

237. Nagiel A, McCannel CA, Moreno C, McCannel TA. Vitrectomy-Assisted Biopsy for Molecular Prognostication of Choroidal Melanoma 2 Mm or Less in Thickness with a 27-Gauge Cutter. *Retina* 2017;37:1377-1382. Available at: <https://www.ncbi.nlm.nih.gov/pubmed/28486310>.

238. Grewal DS, Cummings TJ, Mruthyunjaya P. Outcomes of 27-Gauge Vitrectomy-Assisted Choroidal and Subretinal Biopsy. *Ophthalmic Surg Lasers Imaging Retina* 2017;48:406-415. Available at: <https://www.ncbi.nlm.nih.gov/pubmed/28499052>.

239. Bagger M, Tebering JF, Kiilgaard JF. The ocular consequences and applicability of minimally invasive 25-gauge transvitreal retinochoroidal biopsy. *Ophthalmology* 2013;120:2565-2572. Available at: <https://www.ncbi.nlm.nih.gov/pubmed/24053996>.

240. Jensen OA, Prause JU, Scherfig E. Transvitreal retino-choroidal biopsy of suspected malignant lesions of the choroid. Follow-up of cases over 7 years. *Acta Ophthalmol Scand* 1997;75:409-411. Available at: <https://www.ncbi.nlm.nih.gov/pubmed/9374250>.

241. Seregard S, All-Ericsson C, Hjelmqvist L, et al. Diagnostic incisional biopsies in clinically indeterminate choroidal tumours. *Eye (Lond)* 2013;27:115-118. Available at: <https://www.ncbi.nlm.nih.gov/pubmed/23154498>.

242. Akgul H, Otterbach F, Bornfeld N, Jurklics B. Intraocular biopsy using special forceps: a new instrument and refined surgical technique. *Br J Ophthalmol* 2011;95:79-82. Available at: <https://www.ncbi.nlm.nih.gov/pubmed/21163820>.

243. Kvanta A, Seregard S, Kopp ED, et al. Choroidal biopsies for intraocular tumors of indeterminate origin. *Am J Ophthalmol* 2005;140:1002-1006. Available at: <https://www.ncbi.nlm.nih.gov/pubmed/16376642>.

244. Bagger M, Smidt-Nielsen I, Andersen MK, et al. Long-Term Metastatic Risk after Biopsy of Posterior Uveal Melanoma. *Ophthalmology* 2018;125:1969-1976. Available at: <https://www.ncbi.nlm.nih.gov/pubmed/29705056>.

245. Char DH, Miller T. Accuracy of presumed uveal melanoma diagnosis before alternative therapy. *Br J Ophthalmol* 1995;79:692-696. Available at: <https://www.ncbi.nlm.nih.gov/pubmed/7662638>.

246. McCannel TA, Chang MY, Burgess BL. Multi-year follow-up of fine-needle aspiration biopsy in choroidal melanoma. *Ophthalmology* 2012;119:606-610. Available at: <https://www.ncbi.nlm.nih.gov/pubmed/22226884>.

247. Eide N, Walaas L. Fine-needle aspiration biopsy and other biopsies in suspected intraocular malignant disease: a review. *Acta Ophthalmol* 2009;87:588-601. Available at: <https://www.ncbi.nlm.nih.gov/pubmed/19719804>.

248. Frizziero L, Midena E, Trainiti S, et al. Uveal Melanoma Biopsy: A Review. *Cancers (Basel)* 2019;11. Available at: <https://www.ncbi.nlm.nih.gov/pubmed/31366043>.



249. Matet A, Ait Rais K, Malaise D, et al. Comparative Cytogenetic Abnormalities in Paired Choroidal Melanoma Samples Obtained Before and After Proton Beam Irradiation by Transscleral Fine-Needle Aspiration Biopsy and Endoresection. *Cancers (Basel)* 2019;11. Available at: <https://www.ncbi.nlm.nih.gov/pubmed/31416209>.

250. Cohen VM, Dinakaran S, Parsons MA, Rennie IG. Transvitreal fine needle aspiration biopsy: the influence of intraocular lesion size on diagnostic biopsy result. *Eye (Lond)* 2001;15:143-147. Available at: <https://www.ncbi.nlm.nih.gov/pubmed/11339578>.

251. Eide N, Syrdalen P, Walaas L, Hagmar B. Fine needle aspiration biopsy in selecting treatment for inconclusive intraocular disease. *Acta Ophthalmol Scand* 1999;77:448-452. Available at: <https://www.ncbi.nlm.nih.gov/pubmed/10463420>.

252. Correa ZM, Augsburger JJ. Sufficiency of FNAB aspirates of posterior uveal melanoma for cytologic versus GEP classification in 159 patients, and relative prognostic significance of these classifications. *Graefes Arch Clin Exp Ophthalmol* 2014;252:131-135. Available at: <https://www.ncbi.nlm.nih.gov/pubmed/24270974>.

253. Singh AD, Aziz HA, Pelayes D, Biscotti CV. Twenty-five-gauge cannula-assisted fine-needle aspiration biopsy of choroidal melanoma: Cytopathological Analysis. *Retina* 2017;37:1674-1677. Available at: <https://www.ncbi.nlm.nih.gov/pubmed/28005633>.

254. Reddy DM, Mason LB, Mason JO, 3rd, et al. Vitrectomy and Vitrector Port Needle Biopsy of Choroidal Melanoma for Gene Expression Profile Testing Immediately before Brachytherapy. *Ophthalmology* 2017;124:1377-1382. Available at: <https://www.ncbi.nlm.nih.gov/pubmed/28461017>.

255. Kim RS, Chevez-Barrios P, Bretana ME, et al. Histopathologic Analysis of Transvitreal Fine Needle Aspiration Biopsy Needle Tracts for Uveal Melanoma. *Am J Ophthalmol* 2017;174:9-16. Available at: <https://www.ncbi.nlm.nih.gov/pubmed/27818205>.

256. Chang MY, McCannel TA. Comparison of uveal melanoma cytopathologic sample retrieval in trans-scleral versus vitrectomy-assisted transvitreal fine needle aspiration biopsy. *Br J Ophthalmol* 2014;98:1654-1658. Available at: <https://www.ncbi.nlm.nih.gov/pubmed/24997179>.

257. Augsburger JJ, Correa ZM, Trichopoulos N. Prognostic implications of cytopathologic classification of melanocytic uveal tumors evaluated by fine-needle aspiration biopsy. *Arq Bras Oftalmol* 2013;76:72-79. Available at: <https://www.ncbi.nlm.nih.gov/pubmed/23828465>.

258. Shields CL, Materin MA, Teixeira L, et al. Small choroidal melanoma with chromosome 3 monosomy on fine-needle aspiration biopsy. *Ophthalmology* 2007;114:1919-1924. Available at: <https://www.ncbi.nlm.nih.gov/pubmed/17698199>.

259. Shields CL, Ganguly A, Materin MA, et al. Chromosome 3 analysis of uveal melanoma using fine-needle aspiration biopsy at the time of plaque radiotherapy in 140 consecutive cases. *Trans Am Ophthalmol Soc* 2007;105:43-52; discussion 52-43. Available at: <https://www.ncbi.nlm.nih.gov/pubmed/18427593>.

260. Metz CH, Bornfeld N, Metz KA, Gok M. Suspected vitreous seeding of uveal melanoma: relevance of diagnostic vitrectomy. *Br J Ophthalmol* 2016;100:660-664. Available at: <https://www.ncbi.nlm.nih.gov/pubmed/26359338>.

261. Glasgow BJ, Brown HH, Zargoza AM, Foos RY. Quantitation of tumor seeding from fine needle aspiration of ocular melanomas. *Am J Ophthalmol* 1988;105:538-546. Available at: <https://www.ncbi.nlm.nih.gov/pubmed/3369520>.

262. Karciloglu ZA, Gordon RA, Karciloglu GL. Tumor seeding in ocular fine needle aspiration biopsy. *Ophthalmology* 1985;92:1763-1767. Available at: <https://www.ncbi.nlm.nih.gov/pubmed/4088631>.



NCCN Guidelines Version 2.2021

Melanoma: Uveal

263. Mashayekhi A, Lim RP, Shields CL, et al. Extraocular Extension of Ciliochoroidal Melanoma after Transscleral Fine-Needle Aspiration Biopsy. Retin Cases Brief Rep 2016;10:289-292. Available at: <https://www.ncbi.nlm.nih.gov/pubmed/26655386>.

264. Scheffler AC, Gologorsky D, Marr BP, et al. Extraocular extension of uveal melanoma after fine-needle aspiration, vitrectomy, and open biopsy. JAMA Ophthalmol 2013;131:1220-1224. Available at: <https://www.ncbi.nlm.nih.gov/pubmed/24030334>.

265. Caminal JM, Sanz S, Carreras M, et al. Epibulbar seeding at the site of a transvitreal fine-needle aspiration biopsy. Arch Ophthalmol 2006;124:587-589. Available at: <https://www.ncbi.nlm.nih.gov/pubmed/16606890>.

266. Bagger M, Andersen MT, Heegaard S, et al. Transvitreal Retinochoroidal Biopsy Provides a Representative Sample From Choroidal Melanoma for Detection of Chromosome 3 Aberrations. Invest Ophthalmol Vis Sci 2015;56:5917-5924. Available at: <https://www.ncbi.nlm.nih.gov/pubmed/26377078>.

267. Sen J, Groenewald C, Hiscott PS, et al. Transretinal choroidal tumor biopsy with a 25-gauge vitrector. Ophthalmology 2006;113:1028-1031. Available at: <https://www.ncbi.nlm.nih.gov/pubmed/16751041>.

268. Bechrakis NE, Foerster MH, Bornfeld N. Biopsy in indeterminate intraocular tumors. Ophthalmology 2002;109:235-242. Available at: <https://www.ncbi.nlm.nih.gov/pubmed/11825801>.

269. Raja V, Russo A, Coupland S, et al. Extraocular seeding of choroidal melanoma after a transretinal biopsy with a 25-gauge vitrector. Retin Cases Brief Rep 2011;5:194-196. Available at: <https://www.ncbi.nlm.nih.gov/pubmed/25390162>.

270. Koch KR, Hishmi AM, Ortmann M, Heindl LM. Uveal Melanoma Cell Seeding after Transretinal Tumor Biopsy? Ocul Oncol Pathol 2017;3:164-167. Available at: <https://www.ncbi.nlm.nih.gov/pubmed/29071267>.

271. Foulds WS. The uses and limitations of intraocular biopsy. Eye (Lond) 1992;6 (Pt 1):11-27. Available at: <https://www.ncbi.nlm.nih.gov/pubmed/1426393>.

272. Chang MY, McCannel TA. Local treatment failure after globe-conserving therapy for choroidal melanoma. Br J Ophthalmol 2013;97:804-811. Available at: <https://www.ncbi.nlm.nih.gov/pubmed/23645818>.

273. Bechrakis NE, Petousis V, Willerding G, et al. Ten-year results of transscleral resection of large uveal melanomas: local tumour control and metastatic rate. Br J Ophthalmol 2010;94:460-466. Available at: <https://www.ncbi.nlm.nih.gov/pubmed/19965818>.

274. Damato BE, Paul J, Foulds WS. Risk factors for residual and recurrent uveal melanoma after trans-scleral local resection. Br J Ophthalmol 1996;80:102-108. Available at: <https://www.ncbi.nlm.nih.gov/pubmed/8814738>.

275. Shields JA, Shields CL, Shah P, Sivalingam V. Partial lamellar sclerouvectomy for ciliary body and choroidal tumors. Ophthalmology 1991;98:971-983. Available at: <https://www.ncbi.nlm.nih.gov/pubmed/1866153>.

276. Caminal JM, Padron-Perez N, Arias L, et al. Transscleral resection without hypotensive anaesthesia vs iodine-125 plaque brachytherapy in the treatment of choroidal melanoma. Eye (Lond) 2016;30:833-842. Available at: <https://www.ncbi.nlm.nih.gov/pubmed/27034202>.

277. Krantz BA, Dave N, Komatsubara KM, et al. Uveal melanoma: epidemiology, etiology, and treatment of primary disease. Clin Ophthalmol 2017;11:279-289. Available at: <https://www.ncbi.nlm.nih.gov/pubmed/28203054>.

278. Puusaari I, Damato B, Kivela T. Transscleral local resection versus iodine brachytherapy for uveal melanomas that are large because of tumour height. Graefes Arch Clin Exp Ophthalmol 2007;245:522-533. Available at: <https://www.ncbi.nlm.nih.gov/pubmed/17111148>.



279. Kivela T, Puusaari I, Damato B. Transscleral resection versus iodine brachytherapy for choroidal malignant melanomas 6 millimeters or more in thickness: a matched case-control study. *Ophthalmology* 2003;110:2235-2244. Available at: <https://www.ncbi.nlm.nih.gov/pubmed/14597535>.

280. Damato BE. Local resection of uveal melanoma. *Dev Ophthalmol* 2012;49:66-80. Available at: <https://www.ncbi.nlm.nih.gov/pubmed/22042014>.

281. Dogrusoz M, Jager MJ, Damato B. Uveal Melanoma Treatment and Prognostication. *Asia Pac J Ophthalmol (Phila)* 2017;6:186-196. Available at: <https://www.ncbi.nlm.nih.gov/pubmed/28399342>.

282. Yang J, Manson DK, Marr BP, Carvajal RD. Treatment of uveal melanoma: where are we now? *Ther Adv Med Oncol* 2018;10:1758834018757175. Available at: <https://www.ncbi.nlm.nih.gov/pubmed/29497459>.

283. Dogrusoz M, Kroes WG, van Duinen SG, et al. Radiation Treatment Affects Chromosome Testing in Uveal Melanoma. *Invest Ophthalmol Vis Sci* 2015;56:5956-5964. Available at: <https://www.ncbi.nlm.nih.gov/pubmed/26393462>.

284. Ophthalmic Oncology Task F. Local Recurrence Significantly Increases the Risk of Metastatic Uveal Melanoma. *Ophthalmology* 2016;123:86-91. Available at: <https://www.ncbi.nlm.nih.gov/pubmed/26505803>.

285. Shields CL, Kaliki S, Furuta M, et al. American Joint Committee on Cancer classification of posterior uveal melanoma (tumor size category) predicts prognosis in 7731 patients. *Ophthalmology* 2013;120:2066-2071. Available at: <https://www.ncbi.nlm.nih.gov/pubmed/23664467>.

286. Isager P, Ehlers N, Overgaard J. Have choroidal and ciliary body melanomas changed during the period 1955-2000? *Acta Ophthalmol Scand* 2004;82:509-516. Available at: <https://www.ncbi.nlm.nih.gov/pubmed/15453845>.

287. Rao YJ, Sein J, Badiyan S, et al. Patterns of care and survival outcomes after treatment for uveal melanoma in the post-coms era (2004-2013): a surveillance, epidemiology, and end results analysis. *J Contemp Brachytherapy* 2017;9:453-465. Available at: <https://www.ncbi.nlm.nih.gov/pubmed/29204166>.

288. Vidoris AAC, Maia A, Lowen M, et al. Outcomes of primary endoresection for choroidal melanoma. *Int J Retina Vitreous* 2017;3:42. Available at: <https://www.ncbi.nlm.nih.gov/pubmed/29142760>.

289. Konstantinidis L, Groenewald C, Coupland SE, Damato B. Long-term outcome of primary endoresection of choroidal melanoma. *Br J Ophthalmol* 2014;98:82-85. Available at: <https://www.ncbi.nlm.nih.gov/pubmed/24169650>.

290. Caminal JM, Mejia K, Masuet-Aumatell C, et al. Endoresection versus iodine-125 plaque brachytherapy for the treatment of choroidal melanoma. *Am J Ophthalmol* 2013;156:334-342 e331. Available at: <https://www.ncbi.nlm.nih.gov/pubmed/23677135>.

291. Garcia-Arumi J, Zapata MA, Balaguer O, et al. Endoresection in high posterior choroidal melanomas: long-term outcome. *Br J Ophthalmol* 2008;92:1040-1045. Available at: <https://www.ncbi.nlm.nih.gov/pubmed/18653597>.

292. Kertes PJ, Johnson JC, Peyman GA. Internal resection of posterior uveal melanomas. *Br J Ophthalmol* 1998;82:1147-1153. Available at: <https://www.ncbi.nlm.nih.gov/pubmed/9924302>.

293. Damato B, Groenewald C, McGalliard J, Wong D. Endoresection of choroidal melanoma. *Br J Ophthalmol* 1998;82:213-218. Available at: <https://www.ncbi.nlm.nih.gov/pubmed/9602614>.

294. The Collaborative Ocular Melanoma Study (COMS) randomized trial of pre-enucleation radiation of large choroidal melanoma III: local complications and observations following enucleation COMS report no. 11. *Am J Ophthalmol* 1998;126:362-372. Available at: <https://www.ncbi.nlm.nih.gov/pubmed/9744369>.



295. Collaborative Ocular Melanoma Study G. Assessment of metastatic disease status at death in 435 patients with large choroidal melanoma in the Collaborative Ocular Melanoma Study (COMS): COMS report no. 15. Arch Ophthalmol 2001;119:670-676. Available at: <https://www.ncbi.nlm.nih.gov/pubmed/11346394>.

296. Weis E, Salopek TG, McKinnon JG, et al. Management of uveal melanoma: a consensus-based provincial clinical practice guideline. Curr Oncol 2016;23:e57-64. Available at: <https://www.ncbi.nlm.nih.gov/pubmed/26966414>.

297. Van Acker E, De Potter P. [Porous polyethylene (Medpor) orbital implant. Prospective study of 75 primary implantations]. J Fr Ophtalmol 2001;24:1067-1073. Available at: <https://www.ncbi.nlm.nih.gov/pubmed/11913237>.

298. Ho VWM, Hussain RN, Czanner G, et al. Porous Versus Nonporous Orbital Implants After Enucleation for Uveal Melanoma: A Randomized Study. Ophthalmic Plast Reconstr Surg 2017;33:452-458. Available at: <https://www.ncbi.nlm.nih.gov/pubmed/27861329>.

299. Hope-Stone L, Brown SL, Heimann H, et al. Phantom Eye Syndrome: Patient Experiences after Enucleation for Uveal Melanoma. Ophthalmology 2015;122:1585-1590. Available at: <https://www.ncbi.nlm.nih.gov/pubmed/26004080>.

300. Hawkins BS, Collaborative Ocular Melanoma Study G. The Collaborative Ocular Melanoma Study (COMS) randomized trial of pre-enucleation radiation of large choroidal melanoma: IV. Ten-year mortality findings and prognostic factors. COMS report number 24. Am J Ophthalmol 2004;138:936-951. Available at: <https://www.ncbi.nlm.nih.gov/pubmed/15629284>.

301. The Collaborative Ocular Melanoma Study (COMS) randomized trial of pre-enucleation radiation of large choroidal melanoma II: initial mortality findings. COMS report no. 10. Am J Ophthalmol 1998;125:779-796. Available at: <https://www.ncbi.nlm.nih.gov/pubmed/9645716>.

302. Augsburger JJ, Lauritzen K, Gamel JW, et al. Matched group study of preenucleation radiotherapy versus enucleation alone for primary malignant melanoma of the choroid and ciliary body. Am J Clin Oncol 1990;13:382-387. Available at: <https://www.ncbi.nlm.nih.gov/pubmed/2220658>.

303. Diener-West M, Earle JD, Fine SL, et al. The COMS randomized trial of iodine 125 brachytherapy for choroidal melanoma, III: initial mortality findings. COMS Report No. 18. Arch Ophthalmol 2001;119:969-982. Available at: <https://www.ncbi.nlm.nih.gov/pubmed/11448319>.

304. Collaborative Ocular Melanoma Study G. The COMS randomized trial of iodine 125 brachytherapy for choroidal melanoma: V. Twelve-year mortality rates and prognostic factors: COMS report No. 28. Arch Ophthalmol 2006;124:1684-1693. Available at: <https://www.ncbi.nlm.nih.gov/pubmed/17159027>.

305. Augsburger JJ, Gamel JW, Sardi VF, et al. Enucleation vs cobalt plaque radiotherapy for malignant melanomas of the choroid and ciliary body. Arch Ophthalmol 1986;104:655-661. Available at: <https://www.ncbi.nlm.nih.gov/pubmed/3518677>.

306. Augsburger JJ, Correa ZM, Freire J, Brady LW. Long-term survival in choroidal and ciliary body melanoma after enucleation versus plaque radiation therapy. Ophthalmology 1998;105:1670-1678. Available at: <https://www.ncbi.nlm.nih.gov/pubmed/9754176>.

307. Augsburger JJ, Gamel JW, Lauritzen K, Brady LW. Cobalt-60 plaque radiotherapy vs enucleation for posterior uveal melanoma. Am J Ophthalmol 1990;109:585-592. Available at: <https://www.ncbi.nlm.nih.gov/pubmed/2333923>.

308. Adams KS, Abramson DH, Ellsworth RM, et al. Cobalt plaque versus enucleation for uveal melanoma: comparison of survival rates. Br J Ophthalmol 1988;72:494-497. Available at: <https://www.ncbi.nlm.nih.gov/pubmed/3415941>.



309. Markoe AM, Brady LW, Jr., Shields JA, et al. Malignant melanoma of the eye: treatment of posterior uveal lesions by Co-60 plaque radiotherapy versus enucleation. *Radiology* 1985;156:801-803. Available at: <https://www.ncbi.nlm.nih.gov/pubmed/4023247>.

310. Brady LW, Hernandez JC. Brachytherapy of choroidal melanomas. *Strahlenther Onkol* 1992;168:61-65. Available at: <https://www.ncbi.nlm.nih.gov/pubmed/1542847>.

311. Seddon JM, Gragoudas ES, Egan KM, et al. Relative survival rates after alternative therapies for uveal melanoma. *Ophthalmology* 1990;97:769-777. Available at: <https://www.ncbi.nlm.nih.gov/pubmed/2374681>.

312. Mosci C, Lanza FB, Barla A, et al. Comparison of clinical outcomes for patients with large choroidal melanoma after primary treatment with enucleation or proton beam radiotherapy. *Ophthalmologica* 2012;227:190-196. Available at: <https://www.ncbi.nlm.nih.gov/pubmed/22269846>.

313. Dinca EB, Yianni J, Rowe J, et al. Survival and complications following gamma knife radiosurgery or enucleation for ocular melanoma: a 20-year experience. *Acta Neurochir (Wien)* 2012;154:605-610. Available at: <https://www.ncbi.nlm.nih.gov/pubmed/22231777>.

314. Furdova A, Slezak P, Chorvath M, et al. No differences in outcome between radical surgical treatment (enucleation) and stereotactic radiosurgery in patients with posterior uveal melanoma. *Neoplasma* 2010;57:377-381. Available at: <https://www.ncbi.nlm.nih.gov/pubmed/20429631>.

315. Cohen VM, Carter MJ, Kemeny A, et al. Metastasis-free survival following treatment for uveal melanoma with either stereotactic radiosurgery or enucleation. *Acta Ophthalmol Scand* 2003;81:383-388. Available at: <https://www.ncbi.nlm.nih.gov/pubmed/12859266>.

316. Melia M, Moy CS, Reynolds SM, et al. Quality of life after iodine 125 brachytherapy vs enucleation for choroidal melanoma: 5-year results from the Collaborative Ocular Melanoma Study: COMS QOLS Report No. 3. *Arch Ophthalmol* 2006;124:226-238. Available at: <https://www.ncbi.nlm.nih.gov/pubmed/16476893>.

317. van Beek JGM, Buitendijk GHS, Timman R, et al. Quality of life: fractionated stereotactic radiotherapy versus enucleation treatment in uveal melanoma patients. *Acta Ophthalmol* 2018;96:841-848. Available at: <https://www.ncbi.nlm.nih.gov/pubmed/30284368>.

318. Damato B, Hope-Stone L, Cooper B, et al. Patient-reported Outcomes and Quality of Life After Treatment of Choroidal Melanoma: A Comparison of Enucleation Versus Radiotherapy in 1596 Patients. *Am J Ophthalmol* 2018;193:230-251. Available at: <https://www.ncbi.nlm.nih.gov/pubmed/29555484>.

319. Brandberg Y, Kock E, Oskar K, et al. Psychological reactions and quality of life in patients with posterior uveal melanoma treated with ruthenium plaque therapy or enucleation: a one year follow-up study. *Eye (Lond)* 2000;14:839-846. Available at: <https://www.ncbi.nlm.nih.gov/pubmed/11584839>.

320. Klingenstein A, Furweger C, Muhlhofer AK, et al. Quality of life in the follow-up of uveal melanoma patients after enucleation in comparison to CyberKnife treatment. *Graefes Arch Clin Exp Ophthalmol* 2016;254:1005-1012. Available at: <https://www.ncbi.nlm.nih.gov/pubmed/26573389>.

321. Cruickshanks KJ, Fryback DG, Nondahl DM, et al. Treatment choice and quality of life in patients with choroidal melanoma. *Arch Ophthalmol* 1999;117:461-467. Available at: <https://www.ncbi.nlm.nih.gov/pubmed/10206573>.

322. Available at: <http://documents.cap.org/protocols/cp-uveal-melanoma-17protocol-4000.pdf>. Accessed May 21st, 2021.



NCCN Guidelines Version 2.2021

Melanoma: Uveal

323. Abrams MJ, Gagne NL, Melhus CS, Mignano JE. Brachytherapy vs. external beam radiotherapy for choroidal melanoma: Survival and patterns-of-care analyses. *Brachytherapy* 2016;15:216-223. Available at: <https://www.ncbi.nlm.nih.gov/pubmed/26846381>.

324. Desjardins L, Levy-Gabriel C, Lumbroso-Lerouic L, et al. [Prognostic factors for malignant uveal melanoma. Retrospective study on 2,241 patients and recent contribution of monosomy-3 research]. *J Fr Ophtalmol* 2006;29:741-749. Available at: <https://www.ncbi.nlm.nih.gov/pubmed/16988624>.

325. Echegaray JJ, Bechrakis NE, Singh N, et al. Iodine-125 Brachytherapy for Uveal Melanoma: A Systematic Review of Radiation Dose. *Ocul Oncol Pathol* 2017;3:193-198. Available at: <https://www.ncbi.nlm.nih.gov/pubmed/29071269>.

326. Rospond-Kubiak I, Kociecki J, Damato B. Clinical evaluation of a paper chart for predicting ruthenium plaque placement in relation to choroidal melanoma. *Eye (Lond)* 2018;32:421-425. Available at: <https://www.ncbi.nlm.nih.gov/pubmed/28960216>.

327. Sanchez-Tabernero S, Garcia-Alvarez C, Munoz-Moreno MF, et al. Pattern of Local Recurrence After I-125 Episcleral Brachytherapy for Uveal Melanoma in a Spanish Referral Ocular Oncology Unit. *Am J Ophthalmol* 2017;180:39-45. Available at: <https://www.ncbi.nlm.nih.gov/pubmed/28572063>.

328. McCannel TA, Kamrava M, Demanes J, et al. 23-mm iodine-125 plaque for uveal melanoma: benefit of vitrectomy and silicone oil on visual acuity. *Graefes Arch Clin Exp Ophthalmol* 2016;254:2461-2467. Available at: <https://www.ncbi.nlm.nih.gov/pubmed/27638702>.

329. Collaborative Ocular Melanoma Study G. Incidence of cataract and outcomes after cataract surgery in the first 5 years after iodine 125 brachytherapy in the Collaborative Ocular Melanoma Study: COMS Report No. 27. *Ophthalmology* 2007;114:1363-1371. Available at: <https://www.ncbi.nlm.nih.gov/pubmed/17337065>.

330. Pilotto E, Vujosevic S, De Belvis V, et al. Long-term choroidal vascular changes after iodine brachytherapy versus transpupillary thermotherapy for choroidal melanoma. *Eur J Ophthalmol* 2009;19:646-653. Available at: <https://www.ncbi.nlm.nih.gov/pubmed/19551682>.

331. Sobrin L, Schiffman JC, Markoe AM, Murray TG. Outcomes of iodine 125 plaque radiotherapy after initial observation of suspected small choroidal melanomas: a pilot study. *Ophthalmology* 2005;112:1777-1783. Available at: <https://www.ncbi.nlm.nih.gov/pubmed/16095708>.

332. Seregard S. Long-term survival after ruthenium plaque radiotherapy for uveal melanoma. A meta-analysis of studies including 1,066 patients. *Acta Ophthalmol Scand* 1999;77:414-417. Available at: <https://www.ncbi.nlm.nih.gov/pubmed/10463412>.

333. Finger PT, Berson A, Szechter A. Palladium-103 plaque radiotherapy for choroidal melanoma: results of a 7-year study. *Ophthalmology* 1999;106:606-613. Available at: <https://www.ncbi.nlm.nih.gov/pubmed/10080222>.

334. Miguel D, de Frutos-Baraja JM, Lopez-Lara F, et al. Visual outcome after posterior uveal melanoma episcleral brachytherapy including radiobiological doses. *J Contemp Brachytherapy* 2018;10:123-131. Available at: <https://www.ncbi.nlm.nih.gov/pubmed/29789761>.

335. Tsui I, Beardsley RM, McCannel TA, et al. Visual Acuity, Contrast Sensitivity and Color Vision Three Years After Iodine-125 Brachytherapy for Choroidal and Ciliary Body Melanoma. *Open Ophthalmol J* 2015;9:131-135. Available at: <https://www.ncbi.nlm.nih.gov/pubmed/26312123>.

336. Boldt HC, Melia BM, Liu JC, et al. I-125 brachytherapy for choroidal melanoma photographic and angiographic abnormalities: the Collaborative Ocular Melanoma Study: COMS Report No. 30. *Ophthalmology* 2009;116:106-115 e101. Available at: <https://www.ncbi.nlm.nih.gov/pubmed/19118701>.



337. Finger PT, Chin KJ, Tena LB. A five-year study of slotted eye plaque radiation therapy for choroidal melanoma: near, touching, or surrounding the optic nerve. *Ophthalmology* 2012;119:415-422. Available at: <https://www.ncbi.nlm.nih.gov/pubmed/22133796>.

338. Almony A, Breit S, Zhao H, et al. Tilting of radioactive plaques after initial accurate placement for treatment of uveal melanoma. *Arch Ophthalmol* 2008;126:65-70. Available at: <https://www.ncbi.nlm.nih.gov/pubmed/18195220>.

339. Rivard MJ, Chiu-Tsao S-T, Finger PT, et al. Comparison of dose calculation methods for brachytherapy of intraocular tumors. *Med Phys* 2010;38:306-316. Available at: <https://www.ncbi.nlm.nih.gov/pubmed/21361199>.

340. Meeralakshmi P, Shah PK, Narendran V. Experiences of two different modalities in the management of choroidal melanoma in the Asian Indian population. *South Asian J Cancer* 2017;6:134-136. Available at: <https://www.ncbi.nlm.nih.gov/pubmed/28975125>.

341. Karlovits B, Trombetta MG, Verstraeten T, et al. Local control and visual acuity following treatment of medium-sized ocular melanoma using a contact eye plaque: a single surgeon experience. *Brachytherapy* 2011;10:228-231. Available at: <https://www.ncbi.nlm.nih.gov/pubmed/20932809>.

342. Wagner A, Chen A, Cook T, et al. Outcomes and control rates for I-125 plaque brachytherapy for uveal melanoma: a community-based institutional experience. *ISRN Ophthalmol* 2014;2014:950975. Available at: <https://www.ncbi.nlm.nih.gov/pubmed/24734198>.

343. Berry JL, Dandapani SV, Stevanovic M, et al. Outcomes of choroidal melanomas treated with eye physics: a 20-year review. *JAMA Ophthalmol* 2013;131:1435-1442. Available at: <https://www.ncbi.nlm.nih.gov/pubmed/24008431>.

344. Krema H, Heydarian M, Beiki-Ardakani A, et al. A comparison between (1)(2)(5)Iodine brachytherapy and stereotactic radiotherapy in the management of juxtapapillary choroidal melanoma. *Br J Ophthalmol* 2013;97:327-332. Available at: <https://www.ncbi.nlm.nih.gov/pubmed/23335213>.

345. Wilson MW, Hungerford JL. Comparison of episcleral plaque and proton beam radiation therapy for the treatment of choroidal melanoma. *Ophthalmology* 1999;106:1579-1587. Available at: <https://www.ncbi.nlm.nih.gov/pubmed/10442907>.

346. Char DH, Kroll S, Phillips TL, Quivey JM. Late radiation failures after iodine 125 brachytherapy for uveal melanoma compared with charged-particle (proton or helium ion) therapy. *Ophthalmology* 2002;109:1850-1854. Available at: <https://www.ncbi.nlm.nih.gov/pubmed/12359605>.

347. Char DH, Quivey JM, Castro JR, et al. Helium ions versus iodine 125 brachytherapy in the management of uveal melanoma. A prospective, randomized, dynamically balanced trial. *Ophthalmology* 1993;100:1547-1554. Available at: <https://www.ncbi.nlm.nih.gov/pubmed/8414414>.

348. Harbour JW, Char DH, Kroll S, et al. Metastatic risk for distinct patterns of postirradiation local recurrence of posterior uveal melanoma. *Ophthalmology* 1997;104:1785-1792; discussion 1792-1783. Available at: <https://www.ncbi.nlm.nih.gov/pubmed/9373108>.

349. Wang Z, Nabhan M, Schild SE, et al. Charged particle radiation therapy for uveal melanoma: a systematic review and meta-analysis. *Int J Radiat Oncol Biol Phys* 2013;86:18-26. Available at: <https://www.ncbi.nlm.nih.gov/pubmed/23040219>.

350. Badiyan SN, Rao RC, Apicelli AJ, et al. Outcomes of iodine-125 plaque brachytherapy for uveal melanoma with intraoperative ultrasonography and supplemental transpupillary thermotherapy. *Int J Radiat Oncol Biol Phys* 2014;88:801-805. Available at: <https://www.ncbi.nlm.nih.gov/pubmed/24462385>.



351. Jensen AW, Petersen IA, Kline RW, et al. Radiation complications and tumor control after 125I plaque brachytherapy for ocular melanoma. *Int J Radiat Oncol Biol Phys* 2005;63:101-108. Available at: <https://www.ncbi.nlm.nih.gov/pubmed/16111577>.

352. Quivey JM, Augsburger J, Snelling L, Brady LW. 125I plaque therapy for uveal melanoma. Analysis of the impact of time and dose factors on local control. *Cancer* 1996;77:2356-2362. Available at: <https://www.ncbi.nlm.nih.gov/pubmed/8635107>.

353. Oellers P, Mowery YM, Perez BA, et al. Efficacy and Safety of Low-Dose Iodine Plaque Brachytherapy for Juxtapapillary Choroidal Melanoma. *Am J Ophthalmol* 2018;186:32-40. Available at: <https://www.ncbi.nlm.nih.gov/pubmed/29199010>.

354. Perez BA, Mettu P, Vajzovic L, et al. Uveal melanoma treated with iodine-125 episcleral plaque: an analysis of dose on disease control and visual outcomes. *Int J Radiat Oncol Biol Phys* 2014;89:127-136. Available at: <https://www.ncbi.nlm.nih.gov/pubmed/24613808>.

355. Aziz HA, Singh N, Bena J, et al. Vision Loss Following Episcleral Brachytherapy for Uveal Melanoma: Development of a Vision Prognostication Tool. *JAMA Ophthalmol* 2016;134:615-620. Available at: <https://www.ncbi.nlm.nih.gov/pubmed/27101414>.

356. Murray TG, Markoe AM, Gold AS, et al. Long-term followup comparing two treatment dosing strategies of (125) I plaque radiotherapy in the management of small/medium posterior uveal melanoma. *J Ophthalmol* 2013;2013:517032. Available at: <https://www.ncbi.nlm.nih.gov/pubmed/23533708>.

357. Khan N, Khan MK, Bena J, et al. Plaque brachytherapy for uveal melanoma: a vision prognostication model. *Int J Radiat Oncol Biol Phys* 2012;84:e285-290. Available at: <https://www.ncbi.nlm.nih.gov/pubmed/22658514>.

358. Puusaari I, Heikkonen J, Kivela T. Effect of radiation dose on ocular complications after iodine brachytherapy for large uveal melanoma: empirical data and simulation of collimating plaques. *Invest Ophthalmol Vis Sci* 2004;45:3425-3434. Available at: <https://www.ncbi.nlm.nih.gov/pubmed/15452045>.

359. Char DH, Kroll S, Quivey JM, Castro J. Long term visual outcome of radiated uveal melanomas in eyes eligible for randomisation to enucleation versus brachytherapy. *Br J Ophthalmol* 1996;80:117-124. Available at: <https://www.ncbi.nlm.nih.gov/pubmed/8814740>.

360. Wisely CE, Hadziahmetovic M, Reem RE, et al. Long-term visual acuity outcomes in patients with uveal melanoma treated with 125I episcleral OSU-Nag plaque brachytherapy. *Brachytherapy* 2016;15:12-22. Available at: <https://www.ncbi.nlm.nih.gov/pubmed/26525215>.

361. De Caluwe A, Termote K, Van Gestel D, Van Limbergen E. Dose-response in choroidal melanoma. *Radiother Oncol* 2018;127:374-378. Available at: <https://www.ncbi.nlm.nih.gov/pubmed/29680322>.

362. Danish H, Ferris MJ, Balagamwala E, et al. Comparative outcomes and toxicities for ruthenium-106 versus palladium-103 in the treatment of choroidal melanoma. *Melanoma Res* 2018;28:120-125. Available at: <https://www.ncbi.nlm.nih.gov/pubmed/29303890>.

363. Cho Y, Chang JS, Yoon JS, et al. Ruthenium-106 Brachytherapy with or without Additional Local Therapy Shows Favorable Outcome for Variable-Sized Choroidal Melanomas in Korean Patients. *Cancer Res Treat* 2018;50:138-147. Available at: <https://www.ncbi.nlm.nih.gov/pubmed/28343376>.

364. Siedlecki J, Reiterer V, Leicht S, et al. Incidence of secondary glaucoma after treatment of uveal melanoma with robotic radiosurgery versus brachytherapy. *Acta Ophthalmol* 2017;95:e734-e739. Available at: <https://www.ncbi.nlm.nih.gov/pubmed/28387434>.



365. Tagliaferri L, Pagliara MM, Masciocchi C, et al. Nomogram for predicting radiation maculopathy in patients treated with Ruthenium-106 plaque brachytherapy for uveal melanoma. *J Contemp Brachytherapy* 2017;9:540-547. Available at: <https://www.ncbi.nlm.nih.gov/pubmed/29441098>.

366. Marinkovic M, Horeweg N, Fiocco M, et al. Ruthenium-106 brachytherapy for choroidal melanoma without transpupillary thermotherapy: Similar efficacy with improved visual outcome. *Eur J Cancer* 2016;68:106-113. Available at: <https://www.ncbi.nlm.nih.gov/pubmed/27741435>.

367. Kaiserman I, Anteby I, Chowers I, et al. Post-brachytherapy initial tumour regression rate correlates with metastatic spread in posterior uveal melanoma. *Br J Ophthalmol* 2004;88:892-895. Available at: <https://www.ncbi.nlm.nih.gov/pubmed/15205232>.

368. Georgopoulos M, Zehetmayer M, Ruhswurm I, et al. Tumour regression of uveal melanoma after ruthenium-106 brachytherapy or stereotactic radiotherapy with gamma knife or linear accelerator. *Ophthalmologica* 2003;217:315-319. Available at: <https://www.ncbi.nlm.nih.gov/pubmed/12913319>.

369. Coleman DJ, Silverman RH, Rondeau MJ, et al. Ultrasonic tissue characterization of uveal melanoma and prediction of patient survival after enucleation and brachytherapy. *Am J Ophthalmol* 1991;112:682-688. Available at: <https://www.ncbi.nlm.nih.gov/pubmed/1957904>.

370. Gragoudas ES, Lane AM, Regan S, et al. A randomized controlled trial of varying radiation doses in the treatment of choroidal melanoma. *Arch Ophthalmol* 2000;118:773-778. Available at: <https://www.ncbi.nlm.nih.gov/pubmed/10865313>.

371. Lin AJ, Rao YJ, Acharya S, et al. Patterns of care and outcomes of proton and eye plaque brachytherapy for uveal melanoma: Review of the National Cancer Database. *Brachytherapy* 2017;16:1225-1231. Available at: <https://www.ncbi.nlm.nih.gov/pubmed/28966081>.

372. Castro JR, Char DH, Petti PL, et al. 15 years experience with helium ion radiotherapy for uveal melanoma. *Int J Radiat Oncol Biol Phys* 1997;39:989-996. Available at: <https://www.ncbi.nlm.nih.gov/pubmed/9392536>.

373. Tsuji H, Ishikawa H, Yanagi T, et al. Carbon-ion radiotherapy for locally advanced or unfavorably located choroidal melanoma: a Phase I/II dose-escalation study. *Int J Radiat Oncol Biol Phys* 2007;67:857-862. Available at: <https://www.ncbi.nlm.nih.gov/pubmed/17161555>.

374. Hrbacek J, Mishra KK, Kacperek A, et al. Practice Patterns Analysis of Ocular Proton Therapy Centers: The International OPTIC Survey. *Int J Radiat Oncol Biol Phys* 2016;95:336-343. Available at: <https://www.ncbi.nlm.nih.gov/pubmed/27084651>.

375. Hartsell WF, Kapur R, Hartsell SO, et al. Feasibility of Proton Beam Therapy for Ocular Melanoma Using a Novel 3D Treatment Planning Technique. *Int J Radiat Oncol Biol Phys* 2016;95:353-359. Available at: <https://www.ncbi.nlm.nih.gov/pubmed/27084652>.

376. Krema H, Heydarian M, Beiki-Ardakani A, et al. Dosimetric and late radiation toxicity comparison between iodine-125 brachytherapy and stereotactic radiation therapy for juxtapapillary choroidal melanoma. *Int J Radiat Oncol Biol Phys* 2013;86:510-515. Available at: <https://www.ncbi.nlm.nih.gov/pubmed/23507292>.

377. Sikuade MJ, Salvi S, Rundle PA, et al. Outcomes of treatment with stereotactic radiosurgery or proton beam therapy for choroidal melanoma. *Eye (Lond)* 2015;29:1194-1198. Available at: <https://www.ncbi.nlm.nih.gov/pubmed/26160531>.

378. Furdova A, Horkovicova K, Justusova P, Sramka M. Is it sufficient to repeat LINEAR accelerator stereotactic radiosurgery in choroidal melanoma? *Bratisl Lek Listy* 2016;117:456-462. Available at: <https://www.ncbi.nlm.nih.gov/pubmed/27546698>.



379. Muller K, Naus N, Nowak PJ, et al. Fractionated stereotactic radiotherapy for uveal melanoma, late clinical results. *Radiother Oncol* 2012;102:219-224. Available at:

<https://www.ncbi.nlm.nih.gov/pubmed/21864922>.

380. Modorati G, Miserocchi E, Galli L, et al. Gamma knife radiosurgery for uveal melanoma: 12 years of experience. *Br J Ophthalmol* 2009;93:40-44. Available at:

<https://www.ncbi.nlm.nih.gov/pubmed/18757470>.

381. Fakiris AJ, Lo SS, Henderson MA, et al. Gamma-knife-based stereotactic radiosurgery for uveal melanoma. *Stereotact Funct Neurosurg* 2007;85:106-112. Available at:

<https://www.ncbi.nlm.nih.gov/pubmed/17228176>.

382. Simonova G, Novotny J, Jr., Liscak R, Pilbauer J. Leksell gamma knife treatment of uveal melanoma. *J Neurosurg* 2002;97:635-639. Available at: <https://www.ncbi.nlm.nih.gov/pubmed/12507111>.

383. Mueller AJ, Talies S, Schaller UC, et al. Stereotactic radiosurgery of large uveal melanomas with the gamma-knife. *Ophthalmology* 2000;107:1381-1387; discussion 1387-1388. Available at:

<https://www.ncbi.nlm.nih.gov/pubmed/10889116>.

384. Zehetmayer M, Kitz K, Menapace R, et al. Local tumor control and morbidity after one to three fractions of stereotactic external beam irradiation for uveal melanoma. *Radiother Oncol* 2000;55:135-144. Available at: <https://www.ncbi.nlm.nih.gov/pubmed/10799725>.

385. Haji Mohd Yasin NA, Gray AR, Bevin TH, et al. Choroidal melanoma treated with stereotactic fractionated radiotherapy and prophylactic intravitreal bevacizumab: The Dunedin Hospital experience. *J Med Imaging Radiat Oncol* 2016;60:756-763. Available at:

<https://www.ncbi.nlm.nih.gov/pubmed/27378522>.

386. Wackernagel W, Holl E, Tarmann L, et al. Local tumour control and eye preservation after gamma-knife radiosurgery of choroidal melanomas. *Br J Ophthalmol* 2014;98:218-223. Available at:

<https://www.ncbi.nlm.nih.gov/pubmed/24169651>.

387. Dunavoelgyi R, Zehetmayer M, Gleiss A, et al. Hypofractionated stereotactic photon radiotherapy of posteriorly located choroidal melanoma with five fractions at ten Gy--clinical results after six years of experience. *Radiother Oncol* 2013;108:342-347. Available at:

<https://www.ncbi.nlm.nih.gov/pubmed/24044800>.

388. Dunavoelgyi R, Dieckmann K, Gleiss A, et al. Local tumor control, visual acuity, and survival after hypofractionated stereotactic photon radiotherapy of choroidal melanoma in 212 patients treated between 1997 and 2007. *Int J Radiat Oncol Biol Phys* 2011;81:199-205. Available at: <https://www.ncbi.nlm.nih.gov/pubmed/20675066>.

389. Dieckmann K, Georg D, Zehetmayer M, et al. LINAC based stereotactic radiotherapy of uveal melanoma: 4 years clinical experience. *Radiother Oncol* 2003;67:199-206. Available at:

<https://www.ncbi.nlm.nih.gov/pubmed/12812851>.

390. Suesskind D, Scheiderbauer J, Buchgeister M, et al. Retrospective evaluation of patients with uveal melanoma treated by stereotactic radiosurgery with and without tumor resection. *JAMA Ophthalmol* 2013;131:630-637. Available at:

<https://www.ncbi.nlm.nih.gov/pubmed/23494018>.

391. Kosydar S, Robertson JC, Woodfin M, et al. Systematic Review and Meta-Analysis on the Use of Photon-based Stereotactic Radiosurgery Versus Fractionated Stereotactic Radiotherapy for the Treatment of Uveal Melanoma. *Am J Clin Oncol* 2020. Available at:

<https://www.ncbi.nlm.nih.gov/pubmed/33208706>.

392. Yazici G, Kiratli H, Ozyigit G, et al. Stereotactic Radiosurgery and Fractionated Stereotactic Radiation Therapy for the Treatment of Uveal Melanoma. *Int J Radiat Oncol Biol Phys* 2017;98:152-158. Available at:

<https://www.ncbi.nlm.nih.gov/pubmed/28586956>.

393. Furdova A, Babal P, Kobzova D, et al. Uveal melanoma survival rates after single dose stereotactic radiosurgery. *Neoplasma* 2018;65:965-971. Available at:

<https://www.ncbi.nlm.nih.gov/pubmed/30334446>.



NCCN Guidelines Version 2.2021

Melanoma: Uveal

394. van den Bosch T, Vaarwater J, Verdijk R, et al. Risk factors associated with secondary enucleation after fractionated stereotactic radiotherapy in uveal melanoma. *Acta Ophthalmol* 2015;93:555-560. Available at: <https://www.ncbi.nlm.nih.gov/pubmed/25879399>.

395. Sarici AM, Pazarli H. Gamma-knife-based stereotactic radiosurgery for medium- and large-sized posterior uveal melanoma. *Graefes Arch Clin Exp Ophthalmol* 2013;251:285-294. Available at: <https://www.ncbi.nlm.nih.gov/pubmed/22944897>.

396. Eibl-Lindner K, Furweger C, Nentwich M, et al. Robotic radiosurgery for the treatment of medium and large uveal melanoma. *Melanoma Res* 2016;26:51-57. Available at: <https://www.ncbi.nlm.nih.gov/pubmed/26484738>.

397. Zahorjanova P, Furdova A, Waczulikova I, et al. Radiation Maculopathy after One-Day Session Stereotactic Radiosurgery in Patients with Ciliary Body and Choroidal Melanoma. *Cesk Slov Oftalmol* 2019;75:3-10. Available at: <https://www.ncbi.nlm.nih.gov/pubmed/31382751>.

398. Horwath-Winter J, Schneider MR, Wackernagel W, et al. Influence of single-fraction Gamma-Knife radiosurgery on ocular surface and tear function in choroidal melanoma patients. *Br J Ophthalmol* 2013;97:466-470. Available at: <https://www.ncbi.nlm.nih.gov/pubmed/23349246>.

399. Dunavoelgyi R, Dieckmann K, Gleiss A, et al. Radiogenic side effects after hypofractionated stereotactic photon radiotherapy of choroidal melanoma in 212 patients treated between 1997 and 2007. *Int J Radiat Oncol Biol Phys* 2012;83:121-128. Available at: <https://www.ncbi.nlm.nih.gov/pubmed/21945109>.

400. Gigliotti CR, Modorati G, Di Nicola M, et al. Predictors of radio-induced visual impairment after radiosurgery for uveal melanoma. *Br J Ophthalmol* 2018;102:833-839. Available at: <https://www.ncbi.nlm.nih.gov/pubmed/28903963>.

401. Dunavoelgyi R, Georg D, Zehetmayer M, et al. Dose-response of critical structures in the posterior eye segment to hypofractionated stereotactic photon radiotherapy of choroidal melanoma. *Radiother Oncol* 2013;108:348-353. Available at: <https://www.ncbi.nlm.nih.gov/pubmed/24044791>.

402. Augsburger JJ, Roth SE, Magargal LE, Shields JA. Panretinal photocoagulation for radiation-induced ocular ischemia. *Ophthalmic Surg* 1987;18:589-593. Available at: <https://www.ncbi.nlm.nih.gov/pubmed/3658314>.

403. Konstantinidis L, Groenewald C, Coupland SE, Damato B. Trans-scleral local resection of toxic choroidal melanoma after proton beam radiotherapy. *Br J Ophthalmol* 2014;98:775-779. Available at: <https://www.ncbi.nlm.nih.gov/pubmed/24568869>.

404. Finger PT, Chin KJ. Antivascular endothelial growth factor bevacizumab for radiation optic neuropathy: secondary to plaque radiotherapy. *Int J Radiat Oncol Biol Phys* 2012;82:789-798. Available at: <https://www.ncbi.nlm.nih.gov/pubmed/21277107>.

405. Finger PT, Chin KJ, Semenova EA. Intravitreal anti-VEGF therapy for macular radiation retinopathy: a 10-year study. *Eur J Ophthalmol* 2016;26:60-66. Available at: <https://www.ncbi.nlm.nih.gov/pubmed/26391167>.

406. Roelofs K, Larocque MP, Murtha A, Weis E. The Use of Intravitreal Anti-VEGF and Triamcinolone in the Treatment of Radiation Papillopathy. *Ocul Oncol Pathol* 2018;4:395-400. Available at: <https://www.ncbi.nlm.nih.gov/pubmed/30574493>.

407. Russo A, Reibaldi M, Avitabile T, et al. Dexamethasone Intravitreal Implant Vs Ranibizumab in the Treatment of Macular Edema Secondary to Brachytherapy for Choroidal Melanoma. *Retina* 2018;38:788-794. Available at: <https://www.ncbi.nlm.nih.gov/pubmed/28272283>.



408. Daruich A, Matet A, Schalenbourg A, Zografos L. Intravitreal anti-vascular endothelial growth factor treatment at 2-month intervals reduces foveal avascular zone enlargement and vision loss in radiation maculopathy: A Pilot Study. *Retina* 2019;39:1519-1526. Available at: <https://www.ncbi.nlm.nih.gov/pubmed/29746413>.
409. Murray TG, Latiff A, Villegas VM, Gold AS. Aflibercept for Radiation Maculopathy Study: A Prospective, Randomized Clinical Study. *Ophthalmol Retina* 2019;3:561-566. Available at: <https://www.ncbi.nlm.nih.gov/pubmed/31277797>.
410. Caminal JM, Flores-Moreno I, Arias L, et al. Intravitreal Dexamethasone Implant for Radiation Maculopathy Secondary to Plaque Brachytherapy in Choroidal Melanoma. *Retina* 2015;35:1890-1897. Available at: <https://www.ncbi.nlm.nih.gov/pubmed/26035401>.
411. Mashayekhi A, Rojanaporn D, Al-Dahmash S, et al. Monthly intravitreal bevacizumab for macular edema after iodine-125 plaque radiotherapy of uveal melanoma. *Eur J Ophthalmol* 2014;24:228-234. Available at: <https://www.ncbi.nlm.nih.gov/pubmed/23934823>.
412. Horgan N, Shields CL, Mashayekhi A, et al. Periocular triamcinolone for prevention of macular edema after iodine 125 plaque radiotherapy of uveal melanoma. *Retina* 2008;28:987-995. Available at: <https://www.ncbi.nlm.nih.gov/pubmed/18698302>.
413. Horgan N, Shields CL, Mashayekhi A, et al. Periocular triamcinolone for prevention of macular edema after plaque radiotherapy of uveal melanoma: a randomized controlled trial. *Ophthalmology* 2009;116:1383-1390. Available at: <https://www.ncbi.nlm.nih.gov/pubmed/19481812>.
414. Kim IK, Lane AM, Jain P, et al. Ranibizumab for the Prevention of Radiation Complications in Patients Treated With Proton Beam Irradiation for Choroidal Melanoma. *Trans Am Ophthalmol Soc* 2016;114:T2. Available at: <https://www.ncbi.nlm.nih.gov/pubmed/27630373>.
415. Shields JA, Glazer LC, Mieler WF, et al. Comparison of xenon arc and argon laser photocoagulation in the treatment of choroidal melanomas. *Am J Ophthalmol* 1990;109:647-655. Available at: <https://www.ncbi.nlm.nih.gov/pubmed/2346193>.
416. Munzenrider JE, Verhey LJ, Gragoudas ES, et al. Conservative treatment of uveal melanoma: local recurrence after proton beam therapy. *Int J Radiat Oncol Biol Phys* 1989;17:493-498. Available at: <https://www.ncbi.nlm.nih.gov/pubmed/2550395>.
417. Shields CL, Shields JA, Gunduz K, et al. Radiation therapy for uveal malignant melanoma. *Ophthalmic Surg Lasers* 1998;29:397-409. Available at: <https://www.ncbi.nlm.nih.gov/pubmed/9599365>.
418. Sagoo MS, Shields CL, Mashayekhi A, et al. Plaque radiotherapy for choroidal melanoma encircling the optic disc (circumpapillary choroidal melanoma). *Arch Ophthalmol* 2007;125:1202-1209. Available at: <https://www.ncbi.nlm.nih.gov/pubmed/17846359>.
419. Peyman GA, Gremillion CM. Eye wall resection in the management of uveal neoplasms. *Jpn J Ophthalmol* 1989;33:458-471. Available at: <https://www.ncbi.nlm.nih.gov/pubmed/2625780>.
420. Shields JA, Shields CL, Peairs R, Racciato P. Laser ablation of an enlarging small melanocytic choroidal tumor: 16-year follow-up and rationale for treatment. *Ophthalmic Surg Lasers Imaging* 2006;37:79-81. Available at: <https://www.ncbi.nlm.nih.gov/pubmed/16468559>.
421. Qiang Z, Cairns JD. Laser photocoagulation treatment of choroidal melanoma. *Aust N Z J Ophthalmol* 1993;21:87-92. Available at: <https://www.ncbi.nlm.nih.gov/pubmed/8333939>.
422. Shields JA, Shields CL. Current management of posterior uveal melanoma. *Mayo Clin Proc* 1993;68:1196-1200. Available at: <https://www.ncbi.nlm.nih.gov/pubmed/8246622>.



423. Riechardt AI, Cordini D, Dobner B, et al. Salvage proton beam therapy in local recurrent uveal melanoma. *Am J Ophthalmol* 2014;158:948-956. Available at: <https://www.ncbi.nlm.nih.gov/pubmed/25038327>.

424. Brewington BY, Shao YF, Davidorf FH, Cebulla CM. Brachytherapy for patients with uveal melanoma: historical perspectives and future treatment directions. *Clin Ophthalmol* 2018;12:925-934. Available at: <https://www.ncbi.nlm.nih.gov/pubmed/29844657>.

425. Rodriguez A, Duenas-Gonzalez A, Delgado-Pelayo S. Clinical presentation and management of uveal melanoma. *Mol Clin Oncol* 2016;5:675-677. Available at: <https://www.ncbi.nlm.nih.gov/pubmed/28101347>.

426. Augsburger JJ, Mullen D, Kleinedam M. Planned combined I-125 plaque irradiation and indirect ophthalmoscope laser therapy for choroidal malignant melanoma. *Ophthalmic Surg* 1993;24:76-81. Available at: <https://www.ncbi.nlm.nih.gov/pubmed/8446358>.

427. Tse DT. Laser photocoagulation of choroidal malignant melanoma. *Biomed Pharmacother* 1986;40:323-325. Available at: <https://www.ncbi.nlm.nih.gov/pubmed/3828478>.

428. Brancato R, Menchini U, Pece A. Enucleation after argon laser photocoagulation for choroidal melanoma. *Ann Ophthalmol* 1988;20:296-298. Available at: <https://www.ncbi.nlm.nih.gov/pubmed/3056206>.

429. Beaumont P. Laser photocoagulation treatment of choroidal melanoma. *Aust N Z J Ophthalmol* 1994;22:85-86. Available at: <https://www.ncbi.nlm.nih.gov/pubmed/8037923>.

430. Aaberg TM, Jr. Laser for choroidal melanoma. *Int Ophthalmol Clin* 2006;46:15-26. Available at: <https://www.ncbi.nlm.nih.gov/pubmed/16365552>.

431. Harbour JW, Meredith TA, Thompson PA, Gordon ME. Transpupillary thermotherapy versus plaque radiotherapy for suspected choroidal melanomas. *Ophthalmology* 2003;110:2207-2214; discussion 2215. Available at: <https://www.ncbi.nlm.nih.gov/pubmed/14597531>.

432. De Potter P, Jamart J. Adjuvant indocyanine green in transpupillary thermotherapy for choroidal melanoma. *Ophthalmology* 2003;110:406-413; discussion 413-404. Available at: <https://www.ncbi.nlm.nih.gov/pubmed/12578788>.

433. Chojniak MM, Chojniak R, Nishimoto IN, et al. Primary transpupillary thermotherapy for small choroidal melanoma. *Graefes Arch Clin Exp Ophthalmol* 2011;249:1859-1865. Available at: <https://www.ncbi.nlm.nih.gov/pubmed/21713533>.

434. Parrozzani R, Boccassini B, De Belvis V, et al. Long-term outcome of transpupillary thermotherapy as primary treatment of selected choroidal melanoma. *Acta Ophthalmol* 2009;87:789-792. Available at: <https://www.ncbi.nlm.nih.gov/pubmed/18778335>.

435. Win PH, Robertson DM, Buettner H, et al. Extended follow-up of small melanocytic choroidal tumors treated with transpupillary thermotherapy. *Arch Ophthalmol* 2006;124:503-506. Available at: <https://www.ncbi.nlm.nih.gov/pubmed/16606875>.

436. Spire M, Devouassoux MS, Kodjikian L, et al. Primary transpupillary thermotherapy for 18 small posterior pole uveal melanomas. *Am J Ophthalmol* 2006;141:840-849. Available at: <https://www.ncbi.nlm.nih.gov/pubmed/16678505>.

437. Horgan N, Shields CL, Mashayekhi A, et al. Early macular morphological changes following plaque radiotherapy for uveal melanoma. *Retina* 2008;28:263-273. Available at: <https://www.ncbi.nlm.nih.gov/pubmed/18301032>.



438. Desjardins L, Lumbroso-Le Rouic L, Levy-Gabriel C, et al. Combined proton beam radiotherapy and transpupillary thermotherapy for large uveal melanomas: a randomized study of 151 patients. *Ophthalmic Res* 2006;38:255-260. Available at: <https://www.ncbi.nlm.nih.gov/pubmed/16888407>.

439. Bartlema YM, Oosterhuis JA, Journee-De Korver JG, et al. Combined plaque radiotherapy and transpupillary thermotherapy in choroidal melanoma: 5 years' experience. *Br J Ophthalmol* 2003;87:1370-1373. Available at: <https://www.ncbi.nlm.nih.gov/pubmed/14609837>.

440. Girvigian MR, Astrahan MA, Lim JI, et al. Episcleral plaque 125I radiotherapy with episcleral LCF hyperthermia: a prospective randomized trial. *Brachytherapy* 2003;2:229-239. Available at: <https://www.ncbi.nlm.nih.gov/pubmed/15062131>.

441. Shields CL, Cater J, Shields JA, et al. Combined plaque radiotherapy and transpupillary thermotherapy for choroidal melanoma: tumor control and treatment complications in 270 consecutive patients. *Arch Ophthalmol* 2002;120:933-940. Available at: <https://www.ncbi.nlm.nih.gov/pubmed/12096964>.

442. Petrovich Z, Astrahan MA, Luxton G, et al. Episcleral plaque thermoradiotherapy in patients with choroidal melanoma. *Int J Radiat Oncol Biol Phys* 1992;23:599-603. Available at: <https://www.ncbi.nlm.nih.gov/pubmed/1612961>.

443. Shields CL, Shields JA, Perez N, et al. Primary transpupillary thermotherapy for small choroidal melanoma in 256 consecutive cases: outcomes and limitations. *Ophthalmology* 2002;109:225-234. Available at: <https://www.ncbi.nlm.nih.gov/pubmed/11825800>.

444. Yarovoy AA, Magaramov DA, Bulgakova ES. The comparison of ruthenium brachytherapy and simultaneous transpupillary thermotherapy of choroidal melanoma with brachytherapy alone. *Brachytherapy* 2012;11:224-229. Available at: <https://www.ncbi.nlm.nih.gov/pubmed/22104351>.

445. Gunduz K, Kurt RA, Akmeshe HE, et al. Ruthenium-106 plaque radiotherapy alone or in combination with transpupillary thermotherapy in the management of choroidal melanoma. *Jpn J Ophthalmol* 2010;54:338-343. Available at: <https://www.ncbi.nlm.nih.gov/pubmed/20700803>.

446. Godfrey DG, Waldron RG, Capone A, Jr. Transpupillary thermotherapy for small choroidal melanoma. *Am J Ophthalmol* 1999;128:88-93. Available at: <https://www.ncbi.nlm.nih.gov/pubmed/10482099>.

447. Crougths P, Baguette MN. [Treatment of choroidal nevi and melanomas using cryo-applications: preliminary study]. *Bull Soc Belge Ophtalmol* 1992;243:87-93. Available at: <https://www.ncbi.nlm.nih.gov/pubmed/1302157>.

448. Brovkina AF, Ziangirova GG, Komarov BA. [Cryodestruction of choroidal melanomas]. *Vestn Oftalmol* 1977;61-63. Available at: <https://www.ncbi.nlm.nih.gov/pubmed/860372>.

449. Abramson DH, Lisman RD. Cryopexy of a choroidal melanoma. *Ann Ophthalmol* 1979;11:1418-1421. Available at: <https://www.ncbi.nlm.nih.gov/pubmed/556166>.

450. Lincoff H, McLean J, Long R. The cryosurgical treatment of intraocular tumors. *Am J Ophthalmol* 1967;63:389-399. Available at: <https://www.ncbi.nlm.nih.gov/pubmed/6019526>.

451. Wilson DJ, Klein ML. Choroidal melanoma treated with cryotherapy. *Arch Ophthalmol* 2002;120:393-395. Available at: <https://www.ncbi.nlm.nih.gov/pubmed/11879148>.

452. Wilson DJ, Klein ML. Cryotherapy as a primary treatment for choroidal melanoma. *Arch Ophthalmol* 2002;120:400-403. Available at: <https://www.ncbi.nlm.nih.gov/pubmed/11879152>.

453. Jalkh AE, Trempe CL, Nasrallah FP, et al. Treatment of small choroidal melanomas with photocoagulation. *Ophthalmic Surg* 1988;19:738-742. Available at: <https://www.ncbi.nlm.nih.gov/pubmed/3194108>.



454. Shields JA. Current approaches to the diagnosis and management of choroidal melanomas. *Surv Ophthalmol* 1977;21:443-463. Available at: <https://www.ncbi.nlm.nih.gov/pubmed/331533>.

455. Bellmann C, Lumbroso-Le Rouic L, Levy C, et al. Uveal melanoma: management and outcome of patients with extraocular spread. *Br J Ophthalmol* 2010;94:569-574. Available at: <https://www.ncbi.nlm.nih.gov/pubmed/19965816>.

456. Shields CL, Sioufi K, Robbins JS, et al. LARGE UVEAL MELANOMA (≥ 10 MM THICKNESS): Clinical Features and Millimeter-by-Millimeter Risk of Metastasis in 1311 Cases. The 2018 Albert E. Finley Lecture. *Retina* 2018;38:2010-2022. Available at: <https://www.ncbi.nlm.nih.gov/pubmed/29528980>.

457. Toth J. [Retrospective study of uveal melanoma]. *Magy Onkol* 2005;49:19-25. Available at: <https://www.ncbi.nlm.nih.gov/pubmed/15902329>.

458. van Beek JG, Koopmans AE, Vaarwater J, et al. The prognostic value of extraocular extension in relation to monosomy 3 and gain of chromosome 8q in uveal melanoma. *Invest Ophthalmol Vis Sci* 2014;55:1284-1291. Available at: <https://www.ncbi.nlm.nih.gov/pubmed/24508790>.

459. Blanco G. Diagnosis and treatment of orbital invasion in uveal melanoma. *Can J Ophthalmol* 2004;39:388-396. Available at: <https://www.ncbi.nlm.nih.gov/pubmed/15327104>.

460. Pereira PR, Odashiro AN, Lim LA, et al. Current and emerging treatment options for uveal melanoma. *Clin Ophthalmol* 2013;7:1669-1682. Available at: <https://www.ncbi.nlm.nih.gov/pubmed/24003303>.

461. Mirkiewicz-Sieradzka B, Zygulska-Mach H, Romanowska B, et al. [Attempts of orbit irradiation after enucleation of the eye with malignant choroidal melanoma. Part I]. *Klin Oczna* 1999;101:287-290. Available at: <https://www.ncbi.nlm.nih.gov/pubmed/10581897>.

462. Shammass HF, Blodi FC. Orbital extension of Choroidal and ciliary body melanomas. *Arch Ophthalmol* 1977;95:2002-2005. Available at: <https://www.ncbi.nlm.nih.gov/pubmed/921579>.

463. Kersten RC, Tse DT, Anderson RL, Blodi FC. The role of orbital exenteration in choroidal melanoma with extrascleral extension. *Ophthalmology* 1985;92:436-443. Available at: <https://www.ncbi.nlm.nih.gov/pubmed/3991131>.

464. Pach JM, Robertson DM, Taney BS, et al. Prognostic factors in choroidal and ciliary body melanomas with extrascleral extension. *Am J Ophthalmol* 1986;101:325-331. Available at: <https://www.ncbi.nlm.nih.gov/pubmed/3953727>.

465. Hykin PG, McCartney AC, Plowman PN, Hungerford JL. Postenucleation orbital radiotherapy for the treatment of malignant melanoma of the choroid with extrascleral extension. *Br J Ophthalmol* 1990;74:36-39. Available at: <https://www.ncbi.nlm.nih.gov/pubmed/2106340>.

466. Gunduz K, Shields CL, Shields JA, et al. Plaque radiotherapy for management of ciliary body and choroidal melanoma with extraocular extension. *Am J Ophthalmol* 2000;130:97-102. Available at: <https://www.ncbi.nlm.nih.gov/pubmed/11004266>.

467. Ang KK, Peters LJ, Weber RS, et al. Postoperative radiotherapy for cutaneous melanoma of the head and neck region. *Int J Radiat Oncol Biol Phys* 1994;30:795-798. Available at: <https://www.ncbi.nlm.nih.gov/pubmed/7960981>.

468. Shields CL, Naseripour M, Cater J, et al. Plaque radiotherapy for large posterior uveal melanomas (> 8 -mm thick) in 354 consecutive patients. *Ophthalmology* 2002;109:1838-1849. Available at: <https://www.ncbi.nlm.nih.gov/pubmed/12359604>.

469. Eskelin S, Pyrhonen S, Summanen P, et al. Tumor doubling times in metastatic malignant melanoma of the uvea: tumor progression before and after treatment. *Ophthalmology* 2000;107:1443-1449. Available at: <https://www.ncbi.nlm.nih.gov/pubmed/10919885>.



470. Kreusel KM, Bechrakis N, Riese J, et al. Combined brachytherapy and transpupillary thermotherapy for large choroidal melanoma: tumor regression and early complications. *Graefes Arch Clin Exp Ophthalmol* 2006;244:1575-1580. Available at:

<https://www.ncbi.nlm.nih.gov/pubmed/16738857>.

471. Sanke RF, Collin JR, Garner A, Packard RB. Local recurrence of choroidal malignant melanoma following enucleation. *Br J Ophthalmol* 1981;65:846-849. Available at:

<https://www.ncbi.nlm.nih.gov/pubmed/7317332>.

472. Boudinet M, Berges O, Le Huerou JY, et al. Quantitative echography in the follow-up of patients treated with proton-beam irradiation for primary choroidal melanomas. *Ultrasound Med Biol* 2007;33:1046-1056. Available at:

<https://www.ncbi.nlm.nih.gov/pubmed/17448588>.

473. Gragoudas ES, Lane AM, Munzenrider J, et al. Long-term risk of local failure after proton therapy for choroidal/ciliary body melanoma. *Trans Am Ophthalmol Soc* 2002;100:43-48; discussion 48-49. Available at: <https://www.ncbi.nlm.nih.gov/pubmed/12545676>.

474. Kim TW, Choi E, Park J, et al. Clinical Outcomes of Proton Beam Therapy for Choroidal Melanoma at a Single Institute in Korea. *Cancer Res Treat* 2018;50:335-344. Available at:

<https://www.ncbi.nlm.nih.gov/pubmed/28421723>.

475. Naeser P, Blomquist E, Montelius A, Thoumas KA. Proton irradiation of malignant uveal melanoma. A five year follow-up of patients treated in Uppsala, Sweden. *Ups J Med Sci* 1998;103:203-211. Available at: <https://www.ncbi.nlm.nih.gov/pubmed/10052109>.

476. Egger E, Zografos L, Schalenbourg A, et al. Eye retention after proton beam radiotherapy for uveal melanoma. *Int J Radiat Oncol Biol Phys* 2003;55:867-880. Available at:

<https://www.ncbi.nlm.nih.gov/pubmed/12605964>.

477. Design and methods of a clinical trial for a rare condition: the Collaborative Ocular Melanoma Study. COMS Report No. 3. *Control Clin Trials* 1993;14:362-391. Available at:

<https://www.ncbi.nlm.nih.gov/pubmed/8222668>.

478. Marchini G, Gerosa M, Piovan E, et al. Gamma Knife stereotactic radiosurgery for uveal melanoma: clinical results after 2 years. *Stereotact Funct Neurosurg* 1996;66 Suppl 1:208-213. Available at:

<https://www.ncbi.nlm.nih.gov/pubmed/9032863>.

479. Salvi SM, Aziz HA, Dar S, et al. Uveal Melanoma Regression after Brachytherapy: Relationship with Chromosome 3 Monosomy Status. *Ocul Oncol Pathol* 2017;3:87-94. Available at:

<https://www.ncbi.nlm.nih.gov/pubmed/28868276>.

480. Diener-West M, Reynolds SM, Agugliaro DJ, et al. Screening for metastasis from choroidal melanoma: the Collaborative Ocular Melanoma Study Group Report 23. *J Clin Oncol* 2004;22:2438-2444. Available at:

<https://www.ncbi.nlm.nih.gov/pubmed/15197206>.

481. Diener-West M, Reynolds SM, Agugliaro DJ, et al. Development of metastatic disease after enrollment in the COMS trials for treatment of choroidal melanoma: Collaborative Ocular Melanoma Study Group Report No. 26. *Arch Ophthalmol* 2005;123:1639-1643. Available at:

<https://www.ncbi.nlm.nih.gov/pubmed/16344433>.

482. Collaborative Ocular Melanoma Study G. Ten-year follow-up of fellow eyes of patients enrolled in Collaborative Ocular Melanoma Study randomized trials: COMS report no. 22. *Ophthalmology* 2004;111:966-976. Available at: <https://www.ncbi.nlm.nih.gov/pubmed/15121376>.

483. Scott JF, Vyas R, Galvin J, et al. Primary bilateral uveal melanoma: a population-based study and systematic review. *Clin Exp Ophthalmol* 2018;46:502-510. Available at:

<https://www.ncbi.nlm.nih.gov/pubmed/29219254>.



484. Khetan V, Ambatipudi S, Gopal L. Presumed metastasis of choroidal melanoma to the contralateral choroid. *Retin Cases Brief Rep* 2010;4:387-389. Available at: <https://www.ncbi.nlm.nih.gov/pubmed/25390926>.

485. Shields JA, Shields CL, Shakin EP, Kobetz LE. Metastasis of choroidal melanoma to the contralateral choroid, orbit, and eyelid. *Br J Ophthalmol* 1988;72:456-460. Available at: <https://www.ncbi.nlm.nih.gov/pubmed/3390423>.

486. Singh AD, Shields JA, Shields CL, Sato T. Choroidal melanoma metastatic to the contralateral choroid. *Am J Ophthalmol* 2001;132:941-943. Available at: <https://www.ncbi.nlm.nih.gov/pubmed/11730671>.

487. Torossian NM, Wallace RT, Hwu WJ, Bedikian AY. Metastasis of ciliary body melanoma to the contralateral eye: a case report and review of uveal melanoma literature. *Case Rep Oncol Med* 2015;2015:427163. Available at: <https://www.ncbi.nlm.nih.gov/pubmed/25874144>.

488. Bourla DH, Young TA. Treatment considerations for primary uveal melanoma with choroidal metastasis to the fellow eye. *Semin Ophthalmol* 2007;22:175-177. Available at: <https://www.ncbi.nlm.nih.gov/pubmed/17763240>.

489. Caminal Mitjana JM, Vila Grane N, Adan Civera A, et al. Clinical Course of a Presumed Metastatic Uveal Melanoma to the Contralateral Choroid. *Semin Ophthalmol* 2015;30:417-419. Available at: <https://www.ncbi.nlm.nih.gov/pubmed/24171794>.

490. Coupland SE, Sidiki S, Clark BJ, et al. Metastatic choroidal melanoma to the contralateral orbit 40 years after enucleation. *Arch Ophthalmol* 1996;114:751-756. Available at: <https://www.ncbi.nlm.nih.gov/pubmed/8639093>.

491. George S, Cooke CA, Mc Ginnity GF, et al. Treated choroidal melanoma with late metastases to the contralateral orbit. *Clin Med Pathol* 2009;2:5-8. Available at: <https://www.ncbi.nlm.nih.gov/pubmed/21151543>.

492. Belfort RN, Muller MS, Isenberg J, et al. Metastatic choroidal melanoma to the contralateral eye: a rare case. *Arq Bras Oftalmol* 2018;81:517-519. Available at: <https://www.ncbi.nlm.nih.gov/pubmed/30328940>.

493. Abrahamsson M. Malignant melanoma of the choroid and the ciliary body 1956-1975 in Halland and Gothenburg. Incidence, histopathology and prognosis. *Acta Ophthalmol (Copenh)* 1983;61:600-610. Available at: <https://www.ncbi.nlm.nih.gov/pubmed/6637421>.

494. Crowley NJ, Seigler HF. Late recurrence of malignant melanoma. Analysis of 168 patients. *Ann Surg* 1990;212:173-177. Available at: <http://www.ncbi.nlm.nih.gov/pubmed/2375648>.

495. Gragoudas ES, Egan KM, Seddon JM, et al. Survival of patients with metastases from uveal melanoma. *Ophthalmology* 1991;98:383-389; discussion 390. Available at: <https://www.ncbi.nlm.nih.gov/pubmed/2023760>.

496. Eskelin S, Pyrhonen S, Summanen P, et al. Screening for metastatic malignant melanoma of the uvea revisited. *Cancer* 1999;85:1151-1159. Available at: <https://www.ncbi.nlm.nih.gov/pubmed/10091801>.

497. Eskelin S, Pyrhonen S, Hahka-Kemppinen M, et al. A prognostic model and staging for metastatic uveal melanoma. *Cancer* 2003;97:465-475. Available at: <https://www.ncbi.nlm.nih.gov/pubmed/12518371>.

498. Finger PT, Kurli M, Reddy S, et al. Whole body PET/CT for initial staging of choroidal melanoma. *Br J Ophthalmol* 2005;89:1270-1274. Available at: <https://www.ncbi.nlm.nih.gov/pubmed/16170114>.

499. Kurli M, Reddy S, Tena LB, et al. Whole body positron emission tomography/computed tomography staging of metastatic choroidal melanoma. *Am J Ophthalmol* 2005;140:193-199. Available at: <https://www.ncbi.nlm.nih.gov/pubmed/15992753>.



NCCN Guidelines Version 2.2021

Melanoma: Uveal

500. Piperno-Neumann S, Servois V, Mariani P, et al. Prospective study of surveillance testing for metastasis in 100 high-risk uveal melanoma patients. *J Fr Ophtalmol* 2015;38:526-534. Available at: <https://www.ncbi.nlm.nih.gov/pubmed/25978872>.

501. Kim JH, Shin SJ, Heo SJ, et al. Prognoses and Clinical Outcomes of Primary and Recurrent Uveal Melanoma. *Cancer Res Treat* 2018;50:1238-1251. Available at: <https://www.ncbi.nlm.nih.gov/pubmed/29281872>.

502. Correa ZM, Augsburger JJ. Independent Prognostic Significance of Gene Expression Profile Class and Largest Basal Diameter of Posterior Uveal Melanomas. *Am J Ophthalmol* 2016;162:20-27 e21. Available at: <https://www.ncbi.nlm.nih.gov/pubmed/26596399>.

503. Cai L, Paez-Escamilla M, Walter SD, et al. Gene Expression Profiling and PRAME Status Versus Tumor-Node-Metastasis Staging for Prognostication in Uveal Melanoma. *Am J Ophthalmol* 2018;195:154-160. Available at: <https://www.ncbi.nlm.nih.gov/pubmed/30092184>.

504. Szalai E, Wells JR, Ward L, Grossniklaus HE. Uveal Melanoma Nuclear BRCA1-Associated Protein-1 Immunoreactivity Is an Indicator of Metastasis. *Ophthalmology* 2018;125:203-209. Available at: <https://www.ncbi.nlm.nih.gov/pubmed/28823399>.

505. Delgado-Ramos GM, Thomas F, VanderWalde A, et al. Risk factors, clinical outcomes, and natural history of uveal melanoma: a single-institution analysis. *Med Oncol* 2019;36:17. Available at: <https://www.ncbi.nlm.nih.gov/pubmed/30666496>.

506. Drabarek W, Yavuzigitoglu S, Obulkasim A, et al. Multi-Modality Analysis Improves Survival Prediction in Enucleated Uveal Melanoma Patients. *Invest Ophthalmol Vis Sci* 2019;60:3595-3605. Available at: <https://www.ncbi.nlm.nih.gov/pubmed/31425584>.

507. Mazloumi M, Vichitvejpaisal P, Dalvin LA, et al. Accuracy of The Cancer Genome Atlas Classification vs American Joint Committee on Cancer Classification for Prediction of Metastasis in Patients With Uveal Melanoma. *JAMA Ophthalmol* 2020;138:260-267. Available at: <https://www.ncbi.nlm.nih.gov/pubmed/31944225>.

508. Mooy C, Vissers K, Luyten G, et al. DNA flow cytometry in uveal melanoma: the effect of pre-enucleation irradiation. *Br J Ophthalmol* 1995;79:174-177. Available at: <https://www.ncbi.nlm.nih.gov/pubmed/7696240>.

509. Staby KM, Gravdal K, Mork SJ, et al. Prognostic impact of chromosomal aberrations and GNAQ, GNA11 and BAP1 mutations in uveal melanoma. *Acta Ophthalmol* 2018;96:31-38. Available at: <https://www.ncbi.nlm.nih.gov/pubmed/28444874>.

510. Robertson AG, Shih J, Yau C, et al. Integrative Analysis Identifies Four Molecular and Clinical Subsets in Uveal Melanoma. *Cancer Cell* 2017;32:204-220 e215. Available at: <https://www.ncbi.nlm.nih.gov/pubmed/28810145>.

511. Prescher G, Bornfeld N, Hirche H, et al. Prognostic implications of monosomy 3 in uveal melanoma. *Lancet* 1996;347:1222-1225. Available at: <https://www.ncbi.nlm.nih.gov/pubmed/8622452>.

512. Petrausch U, Martus P, Tonnies H, et al. Significance of gene expression analysis in uveal melanoma in comparison to standard risk factors for risk assessment of subsequent metastases. *Eye (Lond)* 2008;22:997-1007. Available at: <https://www.ncbi.nlm.nih.gov/pubmed/17384575>.

513. Trolet J, Hupe P, Huon I, et al. Genomic profiling and identification of high-risk uveal melanoma by array CGH analysis of primary tumors and liver metastases. *Invest Ophthalmol Vis Sci* 2009;50:2572-2580. Available at: <https://www.ncbi.nlm.nih.gov/pubmed/19151381>.



NCCN Guidelines Version 2.2021

Melanoma: Uveal

514. Shields CL, Ganguly A, Bianciotto CG, et al. Prognosis of uveal melanoma in 500 cases using genetic testing of fine-needle aspiration biopsy specimens. *Ophthalmology* 2011;118:396-401. Available at: <https://www.ncbi.nlm.nih.gov/pubmed/20869116>.

515. Vaarwater J, van den Bosch T, Mensink HW, et al. Multiplex ligation-dependent probe amplification equals fluorescence in-situ hybridization for the identification of patients at risk for metastatic disease in uveal melanoma. *Melanoma Res* 2012;22:30-37. Available at: <https://www.ncbi.nlm.nih.gov/pubmed/22157614>.

516. Ewens KG, Kanetsky PA, Richards-Yutz J, et al. Genomic profile of 320 uveal melanoma cases: chromosome 8p-loss and metastatic outcome. *Invest Ophthalmol Vis Sci* 2013;54:5721-5729. Available at: <https://www.ncbi.nlm.nih.gov/pubmed/23821189>.

517. Barnhill RL, Ye M, Batistella A, et al. The biological and prognostic significance of angiotropism in uveal melanoma. *Lab Invest* 2017. Available at: <https://www.ncbi.nlm.nih.gov/pubmed/28240745>.

518. Vaquero-Garcia J, Lalonde E, Ewens KG, et al. PRiMeUM: A Model for Predicting Risk of Metastasis in Uveal Melanoma. *Invest Ophthalmol Vis Sci* 2017;58:4096-4105. Available at: <https://www.ncbi.nlm.nih.gov/pubmed/28828481>.

519. Ewens KG, Lalonde E, Richards-Yutz J, et al. Comparison of Germline versus Somatic BAP1 Mutations for Risk of Metastasis in Uveal Melanoma. *BMC Cancer* 2018;18:1172. Available at: <https://www.ncbi.nlm.nih.gov/pubmed/30477459>.

520. Patrone S, Maric I, Rutigliani M, et al. Prognostic value of chromosomal imbalances, gene mutations, and BAP1 expression in uveal melanoma. *Genes Chromosomes Cancer* 2018;57:387-400. Available at: <https://www.ncbi.nlm.nih.gov/pubmed/29689622>.

521. Afshar AR, Damato BE, Stewart JM, et al. Next-Generation Sequencing of Uveal Melanoma for Detection of Genetic Alterations Predicting Metastasis. *Transl Vis Sci Technol* 2019;8:18. Available at: <https://www.ncbi.nlm.nih.gov/pubmed/31024753>.

522. Shields CL, Dalvin LA, Vichitvejpaisal P, et al. Prognostication of uveal melanoma is simple and highly predictive using The Cancer Genome Atlas (TCGA) classification: A review. *Indian J Ophthalmol* 2019;67:1959-1963. Available at: <https://www.ncbi.nlm.nih.gov/pubmed/31755428>.

523. Rodrigues M, Ait Rais K, Salviat F, et al. Association of Partial Chromosome 3 Deletion in Uveal Melanomas With Metastasis-Free Survival. *JAMA Ophthalmol* 2020;138:182-188. Available at: <https://www.ncbi.nlm.nih.gov/pubmed/31895446>.

524. Versluis M, de Lange MJ, van Pelt SI, et al. Digital PCR validates 8q dosage as prognostic tool in uveal melanoma. *PLoS One* 2015;10:e0116371. Available at: <https://www.ncbi.nlm.nih.gov/pubmed/25764247>.

525. Chang MY, Rao NP, Burgess BL, et al. Heterogeneity of monosomy 3 in fine needle aspiration biopsy of choroidal melanoma. *Mol Vis* 2013;19:1892-1900. Available at: <https://www.ncbi.nlm.nih.gov/pubmed/24049435>.

526. Onken MD, Worley LA, Ehlers JP, Harbour JW. Gene expression profiling in uveal melanoma reveals two molecular classes and predicts metastatic death. *Cancer Res* 2004;64:7205-7209. Available at: <https://www.ncbi.nlm.nih.gov/pubmed/15492234>.

527. Tschentscher F, Husing J, Holter T, et al. Tumor classification based on gene expression profiling shows that uveal melanomas with and without monosomy 3 represent two distinct entities. *Cancer Res* 2003;63:2578-2584. Available at: <https://www.ncbi.nlm.nih.gov/pubmed/12750282>.

528. Onken MD, Worley LA, Davila RM, et al. Prognostic testing in uveal melanoma by transcriptomic profiling of fine needle biopsy specimens. *J Mol Diagn* 2006;8:567-573. Available at: <https://www.ncbi.nlm.nih.gov/pubmed/17065425>.



529. Worley LA, Onken MD, Person E, et al. Transcriptomic versus chromosomal prognostic markers and clinical outcome in uveal melanoma. Clin Cancer Res 2007;13:1466-1471. Available at: <https://www.ncbi.nlm.nih.gov/pubmed/17332290>.

530. Onken MD, Worley LA, Tuscan MD, Harbour JW. An accurate, clinically feasible multi-gene expression assay for predicting metastasis in uveal melanoma. J Mol Diagn 2010;12:461-468. Available at: <https://www.ncbi.nlm.nih.gov/pubmed/20413675>.

531. Chappell MC, Char DH, Cole TB, et al. Uveal melanoma: molecular pattern, clinical features, and radiation response. Am J Ophthalmol 2012;154:227-232 e222. Available at: <https://www.ncbi.nlm.nih.gov/pubmed/22541662>.

532. Decatur CL, Ong E, Garg N, et al. Driver Mutations in Uveal Melanoma: Associations With Gene Expression Profile and Patient Outcomes. JAMA Ophthalmol 2016;134:728-733. Available at: <https://www.ncbi.nlm.nih.gov/pubmed/27123562>.

533. Field MG, Decatur CL, Kurtenbach S, et al. PRAME as an Independent Biomarker for Metastasis in Uveal Melanoma. Clin Cancer Res 2016;22:1234-1242. Available at: <https://www.ncbi.nlm.nih.gov/pubmed/26933176>.

534. Plasseraud KM, Cook RW, Tsai T, et al. Clinical Performance and Management Outcomes with the DecisionDx-UM Gene Expression Profile Test in a Prospective Multicenter Study. J Oncol 2016;2016:5325762. Available at: <https://www.ncbi.nlm.nih.gov/pubmed/27446211>.

535. Walter SD, Chao DL, Feuer W, et al. Prognostic Implications of Tumor Diameter in Association With Gene Expression Profile for Uveal Melanoma. JAMA Ophthalmol 2016;134:734-740. Available at: <https://www.ncbi.nlm.nih.gov/pubmed/27123792>.

536. Koopmans AE, Verdijk RM, Brouwer RW, et al. Clinical significance of immunohistochemistry for detection of BAP1 mutations in uveal melanoma. Mod Pathol 2014;27:1321-1330. Available at: <https://www.ncbi.nlm.nih.gov/pubmed/24633195>.

537. Jha J, Singh MK, Singh L, et al. Expression of BAP1 and ATM proteins: Association with AJCC tumor category in uveal melanoma. Ann Diagn Pathol 2019;44:151432. Available at: <https://www.ncbi.nlm.nih.gov/pubmed/31864162>.

538. Szalai E, Jiang Y, van Poppelen NM, et al. Association of Uveal Melanoma Metastatic Rate With Stochastic Mutation Rate and Type of Mutation. JAMA Ophthalmol 2018;136:1115-1120. Available at: <https://www.ncbi.nlm.nih.gov/pubmed/30073324>.

539. Yavuziyigitoglu S, Koopmans AE, Verdijk RM, et al. Uveal Melanomas with SF3B1 Mutations: A Distinct Subclass Associated with Late-Onset Metastases. Ophthalmology 2016;123:1118-1128. Available at: <https://www.ncbi.nlm.nih.gov/pubmed/26923342>.

540. Yavuziyigitoglu S, Mensink HW, Smit KN, et al. Metastatic Disease in Polyploid Uveal Melanoma Patients Is Associated With BAP1 Mutations. Invest Ophthalmol Vis Sci 2016;57:2232-2239. Available at: <https://www.ncbi.nlm.nih.gov/pubmed/27116551>.

541. Scheffler AC, Koca E, Bernicker EH, Correa ZM. Relationship between clinical features, GEP class, and PRAME expression in uveal melanoma. Graefes Arch Clin Exp Ophthalmol 2019;257:1541-1545. Available at: <https://www.ncbi.nlm.nih.gov/pubmed/31065847>.

542. Gombos DS, Van Quill KR, Uusitalo M, O'Brien JM. Geographic disparities in diagnostic screening for metastatic uveal melanoma. Ophthalmology 2004;111:2254-2258. Available at: <https://www.ncbi.nlm.nih.gov/pubmed/15582082>.

543. Felberg NT, Shields JA, Maguire J, et al. Gamma-glutamyl transpeptidase in the prognosis of patients with uveal malignant melanoma. Am J Ophthalmol 1983;95:467-473. Available at: <https://www.ncbi.nlm.nih.gov/pubmed/6132555>.



544. Hicks C, Foss AJ, Hungerford JL. Predictive power of screening tests for metastasis in uveal melanoma. *Eye (Lond)* 1998;12 (Pt 6):945-948. Available at: <https://www.ncbi.nlm.nih.gov/pubmed/10325992>.

545. Kaiserman I, Amer R, Pe'er J. Liver function tests in metastatic uveal melanoma. *Am J Ophthalmol* 2004;137:236-243. Available at: <https://www.ncbi.nlm.nih.gov/pubmed/14962411>.

546. Patel M, Winston CB, Marr BP, et al. Characterization of computed tomography scan abnormalities in patients with biopsy-proven hepatic metastases from uveal melanoma. *Arch Ophthalmol* 2011;129:1576-1582. Available at: <https://www.ncbi.nlm.nih.gov/pubmed/22159677>.

547. Mouriaux F, Diorio C, Bergeron D, et al. Liver function testing is not helpful for early diagnosis of metastatic uveal melanoma. *Ophthalmology* 2012;119:1590-1595. Available at: <https://www.ncbi.nlm.nih.gov/pubmed/22683062>.

548. Wagoner MD, Albert DM. The incidence of metastases from untreated ciliary body and choroidal melanoma. *Arch Ophthalmol* 1982;100:939-940. Available at: <https://www.ncbi.nlm.nih.gov/pubmed/7092632>.

549. Hendler K, Pe'er J, Kaiserman I, et al. Trends in liver function tests: a comparison with serum tumor markers in metastatic uveal melanoma (part 2). *Anticancer Res* 2011;31:351-357. Available at: <https://www.ncbi.nlm.nih.gov/pubmed/21273623>.

550. Semelka RC, Martin DR, Balci C, Lance T. Focal liver lesions: comparison of dual-phase CT and multisequence multiplanar MR imaging including dynamic gadolinium enhancement. *J Magn Reson Imaging* 2001;13:397-401. Available at: <https://www.ncbi.nlm.nih.gov/pubmed/11241813>.

551. Francken AB, Fulham MJ, Millward MJ, Thompson JF. Detection of metastatic disease in patients with uveal melanoma using positron emission tomography. *Eur J Surg Oncol* 2006;32:780-784. Available at: <https://www.ncbi.nlm.nih.gov/pubmed/16765562>.

552. Maeda T, Tateishi U, Suzuki S, et al. Magnetic resonance screening trial for hepatic metastasis in patients with locally controlled choroidal melanoma. *Jpn J Clin Oncol* 2007;37:282-286. Available at: <https://www.ncbi.nlm.nih.gov/pubmed/17553818>.

553. Strobel K, Bode B, Dummer R, et al. Limited value of 18F-FDG PET/CT and S-100B tumour marker in the detection of liver metastases from uveal melanoma compared to liver metastases from cutaneous melanoma. *Eur J Nucl Med Mol Imaging* 2009;36:1774-1782. Available at: <https://www.ncbi.nlm.nih.gov/pubmed/19495748>.

554. Servois V, Mariani P, Malhaire C, et al. Preoperative staging of liver metastases from uveal melanoma by magnetic resonance imaging (MRI) and fluorodeoxyglucose-positron emission tomography (FDG-PET). *Eur J Surg Oncol* 2010;36:189-194. Available at: <https://www.ncbi.nlm.nih.gov/pubmed/19775851>.

555. Orcurto V, Denys A, Voelter V, et al. (18)F-fluorodeoxyglucose positron emission tomography/computed tomography and magnetic resonance imaging in patients with liver metastases from uveal melanoma: results from a pilot study. *Melanoma Res* 2012;22:63-69. Available at: <https://www.ncbi.nlm.nih.gov/pubmed/22027909>.

556. Marshall E, Romaniuk C, Ghaneh P, et al. MRI in the detection of hepatic metastases from high-risk uveal melanoma: a prospective study in 188 patients. *Br J Ophthalmol* 2013;97:159-163. Available at: <https://www.ncbi.nlm.nih.gov/pubmed/23159448>.

557. Wagner M, Mariani P, Bidard FC, et al. Diffusion-weighted MRI for uveal melanoma liver metastasis detection. *Eur Radiol* 2015;25:2263-2273. Available at: <https://www.ncbi.nlm.nih.gov/pubmed/25712144>.

558. Choudhary MM, Gupta A, Bena J, et al. Hepatic Ultrasonography for Surveillance in Patients With Uveal Melanoma. *JAMA Ophthalmol* 2016;134:174-180. Available at: <https://www.ncbi.nlm.nih.gov/pubmed/26633182>.



559. Cohen VML, Pavlidou E, DaCosta J, et al. Staging Uveal Melanoma with Whole-Body Positron-Emission Tomography/Computed Tomography and Abdominal Ultrasound: Low Incidence of Metastatic Disease, High Incidence of Second Primary Cancers. *Middle East Afr J Ophthalmol* 2018;25:91-95. Available at: <https://www.ncbi.nlm.nih.gov/pubmed/30122854>.

560. Rantala ES, Peltola E, Helminen H, et al. Hepatic Ultrasonography Compared With Computed Tomography and Magnetic Resonance Imaging at Diagnosis of Metastatic Uveal Melanoma. *Am J Ophthalmol* 2020;216:156-164. Available at: <https://www.ncbi.nlm.nih.gov/pubmed/32278769>.

561. Wen JC, Sai V, Straatsma BR, McCannel TA. Radiation-related cancer risk associated with surveillance imaging for metastasis from choroidal melanoma. *JAMA Ophthalmol* 2013;131:56-61. Available at: <https://www.ncbi.nlm.nih.gov/pubmed/23307209>.

562. Kodjikian L, Grange JD, Baldo S, et al. Prognostic factors of liver metastases from uveal melanoma. *Graefes Arch Clin Exp Ophthalmol* 2005;243:985-993. Available at: <https://www.ncbi.nlm.nih.gov/pubmed/15891893>.

563. Rivoire M, Kodjikian L, Baldo S, et al. Treatment of liver metastases from uveal melanoma. *Ann Surg Oncol* 2005;12:422-428. Available at: <https://www.ncbi.nlm.nih.gov/pubmed/15886904>.

564. Kim IK, Lane AM, Gragoudas ES. Survival in patients with presymptomatic diagnosis of metastatic uveal melanoma. *Arch Ophthalmol* 2010;128:871-875. Available at: <https://www.ncbi.nlm.nih.gov/pubmed/20625048>.

565. Chin K, Finger PT, Kurli M, et al. Second cancers discovered by (18)FDG PET/CT imaging for choroidal melanoma. *Optometry* 2007;78:396-401. Available at: <https://www.ncbi.nlm.nih.gov/pubmed/17662928>.

566. Diener-West M, Reynolds SM, Agugliaro DJ, et al. Second primary cancers after enrollment in the COMS trials for treatment of choroidal melanoma: COMS Report No. 25. *Arch Ophthalmol* 2005;123:601-604. Available at: <https://www.ncbi.nlm.nih.gov/pubmed/15883277>.

567. Kujala E, Makitie T, Kivela T. Very long-term prognosis of patients with malignant uveal melanoma. *Invest Ophthalmol Vis Sci* 2003;44:4651-4659. Available at: <https://www.ncbi.nlm.nih.gov/pubmed/14578381>.

568. Caminal JM, Martinez J, Arias LL, et al. Multiple neoplasms in patients with uveal melanoma. *Arch Soc Esp Oftalmol* 2007;82:535-540. Available at: <https://www.ncbi.nlm.nih.gov/pubmed/17846942>.

569. Augsburger JJ, Correa ZM, Shaikh AH. Effectiveness of treatments for metastatic uveal melanoma. *Am J Ophthalmol* 2009;148:119-127. Available at: <https://www.ncbi.nlm.nih.gov/pubmed/19375060>.

570. Valpione S, Moser JC, Parrozzani R, et al. Development and external validation of a prognostic nomogram for metastatic uveal melanoma. *PLoS One* 2015;10:e0120181. Available at: <https://www.ncbi.nlm.nih.gov/pubmed/25780931>.

571. Nicholas MN, Khoja L, Atenafu EG, et al. Prognostic factors for first-line therapy and overall survival of metastatic uveal melanoma: The Princess Margaret Cancer Centre experience. *Melanoma Res* 2018;28:571-577. Available at: <https://www.ncbi.nlm.nih.gov/pubmed/30067547>.

572. Lorenzo D, Piulats JM, Ochoa M, et al. Clinical predictors of survival in metastatic uveal melanoma. *Jpn J Ophthalmol* 2019;63:197-209. Available at: <https://www.ncbi.nlm.nih.gov/pubmed/30796549>.

573. Mariani P, Dureau S, Savignoni A, et al. Development of a Prognostic Nomogram for Liver Metastasis of Uveal Melanoma Patients Selected by Liver MRI. *Cancers (Basel)* 2019;11. Available at: <https://www.ncbi.nlm.nih.gov/pubmed/31234340>.



NCCN Guidelines Version 2.2021

Melanoma: Uveal

574. Jochems A, van der Kooij MK, Fiocco M, et al. Metastatic Uveal Melanoma: Treatment Strategies and Survival-Results from the Dutch Melanoma Treatment Registry. *Cancers (Basel)* 2019;11. Available at: <https://www.ncbi.nlm.nih.gov/pubmed/31323802>.

575. Gragoudas ES, Egan KM, Seddon JM, et al. Intraocular recurrence of uveal melanoma after proton beam irradiation. *Ophthalmology* 1992;99:760-766. Available at: <https://www.ncbi.nlm.nih.gov/pubmed/1594223>.

576. Marucci L, Lane AM, Li W, et al. Conservation treatment of the eye: Conformal proton reirradiation for recurrent uveal melanoma. *Int J Radiat Oncol Biol Phys* 2006;64:1018-1022. Available at: <https://www.ncbi.nlm.nih.gov/pubmed/16376492>.

577. Marucci L, Ancukiewicz M, Lane AM, et al. Uveal melanoma recurrence after fractionated proton beam therapy: comparison of survival in patients treated with reirradiation or with enucleation. *Int J Radiat Oncol Biol Phys* 2011;79:842-846. Available at: <https://www.ncbi.nlm.nih.gov/pubmed/20472356>.

578. Seibel I, Cordini D, Rehak M, et al. Local Recurrence After Primary Proton Beam Therapy in Uveal Melanoma: Risk Factors, Retreatment Approaches, and Outcome. *Am J Ophthalmol* 2015;160:628-636. Available at: <https://www.ncbi.nlm.nih.gov/pubmed/26133249>.

579. King B, Morales-Tirado VM, Wynn HG, et al. Repeat Episcleral Plaque Brachytherapy: Clinical Outcomes in Patients Treated for Locally Recurrent Posterior Uveal Melanoma. *Am J Ophthalmol* 2017;176:40-45. Available at: <https://www.ncbi.nlm.nih.gov/pubmed/28048976>.

580. Rantala ES, Hernberg M, Kivela TT. Overall survival after treatment for metastatic uveal melanoma: a systematic review and meta-analysis. *Melanoma Res* 2019;29:561-568. Available at: <https://www.ncbi.nlm.nih.gov/pubmed/30664106>.

581. Rowcroft A, Loveday BPT, Thomson BNJ, et al. Systematic review of liver directed therapy for uveal melanoma hepatic metastases. *HPB (Oxford)* 2020;22:497-505. Available at: <https://www.ncbi.nlm.nih.gov/pubmed/31791894>.

582. Frenkel S, Nir I, Hendler K, et al. Long-term survival of uveal melanoma patients after surgery for liver metastases. *Br J Ophthalmol* 2009;93:1042-1046. Available at: <https://www.ncbi.nlm.nih.gov/pubmed/19429579>.

583. Kivela TT, Piperno-Neumann S, Desjardins L, et al. Validation of a Prognostic Staging for Metastatic Uveal Melanoma: A Collaborative Study of the European Ophthalmic Oncology Group. *Am J Ophthalmol* 2016;168:217-226. Available at: <https://www.ncbi.nlm.nih.gov/pubmed/27296487>.

584. Xu LT, Funchain PF, Bena JF, et al. Uveal Melanoma Metastatic to the Liver: Treatment Trends and Outcomes. *Ocul Oncol Pathol* 2019;5:323-332. Available at: <https://www.ncbi.nlm.nih.gov/pubmed/31559243>.

585. Hsueh EC, Essner R, Foshag LJ, et al. Prolonged survival after complete resection of metastases from intraocular melanoma. *Cancer* 2004;100:122-129. Available at: <https://www.ncbi.nlm.nih.gov/pubmed/14692032>.

586. Augsburger JJ, Correa ZM, Shaikh AH. Quality of evidence about effectiveness of treatments for metastatic uveal melanoma. *Trans Am Ophthalmol Soc* 2008;106:128-135; discussion 135-127. Available at: <https://www.ncbi.nlm.nih.gov/pubmed/19277228>.

587. Buder K, Gesierich A, Gelbrich G, Goebeler M. Systemic treatment of metastatic uveal melanoma: review of literature and future perspectives. *Cancer Med* 2013;2:674-686. Available at: <https://www.ncbi.nlm.nih.gov/pubmed/24403233>.



588. Barnhill R, Vermeulen P, Daelemans S, et al. Replacement and desmoplastic histopathological growth patterns: A pilot study of prediction of outcome in patients with uveal melanoma liver metastases. *J Pathol Clin Res* 2018;4:227-240. Available at: <https://www.ncbi.nlm.nih.gov/pubmed/29917326>.

589. Agarwala SS, Eggermont AM, O'Day S, Zager JS. Metastatic melanoma to the liver: a contemporary and comprehensive review of surgical, systemic, and regional therapeutic options. *Cancer* 2014;120:781-789. Available at: <https://www.ncbi.nlm.nih.gov/pubmed/24301420>.

590. Leyvraz S, Piperno-Neumann S, Suci S, et al. Hepatic intra-arterial versus intravenous fotemustine in patients with liver metastases from uveal melanoma (EORTC 18021): a multicentric randomized trial. *Ann Oncol* 2014;25:742-746. Available at: <https://www.ncbi.nlm.nih.gov/pubmed/24510314>.

591. Salmon RJ, Levy C, Plancher C, et al. Treatment of liver metastases from uveal melanoma by combined surgery-chemotherapy. *Eur J Surg Oncol* 1998;24:127-130. Available at: <https://www.ncbi.nlm.nih.gov/pubmed/9591028>.

592. Mariani P, Piperno-Neumann S, Servois V, et al. Surgical management of liver metastases from uveal melanoma: 16 years' experience at the Institut Curie. *Eur J Surg Oncol* 2009;35:1192-1197. Available at: <https://www.ncbi.nlm.nih.gov/pubmed/19329272>.

593. Ryu SW, Saw R, Scolyer RA, et al. Liver resection for metastatic melanoma: equivalent survival for cutaneous and ocular primaries. *J Surg Oncol* 2013;108:129-135. Available at: <https://www.ncbi.nlm.nih.gov/pubmed/23813600>.

594. Gomez D, Wetherill C, Cheong J, et al. The Liverpool uveal melanoma liver metastases pathway: outcome following liver resection. *J Surg Oncol* 2014;109:542-547. Available at: <https://www.ncbi.nlm.nih.gov/pubmed/24357463>.

595. Akyuz M, Yazici P, Dural C, et al. Laparoscopic management of liver metastases from uveal melanoma. *Surg Endosc* 2016;30:2567-2571. Available at: <https://www.ncbi.nlm.nih.gov/pubmed/26310535>.

596. Mariani P, Almubarak MM, Kollen M, et al. Radiofrequency ablation and surgical resection of liver metastases from uveal melanoma. *Eur J Surg Oncol* 2016;42:706-712. Available at: <https://www.ncbi.nlm.nih.gov/pubmed/26968227>.

597. Aoyama T, Mastrangelo MJ, Berd D, et al. Protracted survival after resection of metastatic uveal melanoma. *Cancer* 2000;89:1561-1568. Available at: <https://www.ncbi.nlm.nih.gov/pubmed/11013372>.

598. Adam R, Chiche L, Aloia T, et al. Hepatic resection for noncolorectal nonendocrine liver metastases: analysis of 1,452 patients and development of a prognostic model. *Ann Surg* 2006;244:524-535. Available at: <https://www.ncbi.nlm.nih.gov/pubmed/16998361>.

599. de Ridder J, van Walsum M, Verhoef C, et al. Hepatic resection for metastatic melanoma in The Netherlands: survival and prognostic factors. *Melanoma Res* 2013;23:27-32. Available at: <https://www.ncbi.nlm.nih.gov/pubmed/23164992>.

600. Yang XY, Xie F, Tao R, et al. Treatment of liver metastases from uveal melanoma: a retrospective single-center analysis. *Hepatobiliary Pancreat Dis Int* 2013;12:602-606. Available at: <https://www.ncbi.nlm.nih.gov/pubmed/24322745>.

601. Servois V, Bouhadiba T, Dureau S, et al. Iterative treatment with surgery and radiofrequency ablation of uveal melanoma liver metastasis: Retrospective analysis of a series of very long-term survivors. *Eur J Surg Oncol* 2019;45:1717-1722. Available at: <https://www.ncbi.nlm.nih.gov/pubmed/31266665>.

602. Pawlik TM, Zorzi D, Abdalla EK, et al. Hepatic resection for metastatic melanoma: distinct patterns of recurrence and prognosis for ocular versus cutaneous disease. *Ann Surg Oncol* 2006;13:712-720. Available at: <https://www.ncbi.nlm.nih.gov/pubmed/16538410>.



603. Eschelmann DJ, Gonsalves CF, Sato T. Transhepatic therapies for metastatic uveal melanoma. *Semin Intervent Radiol* 2013;30:39-48. Available at: <https://www.ncbi.nlm.nih.gov/pubmed/24436516>.

604. Glazer ES, Zager JS. Chemosaturation With Percutaneous Hepatic Perfusion in Unresectable Hepatic Metastases. *Cancer Control* 2017;24:96-101. Available at: <https://www.ncbi.nlm.nih.gov/pubmed/28178721>.

605. Broman KK, Zager JS. Intra-arterial perfusion-based therapies for regionally metastatic cutaneous and uveal melanoma. *Melanoma Manag* 2019;6:MMT26. Available at: <https://www.ncbi.nlm.nih.gov/pubmed/31807277>.

606. Breedis C, Young G. The blood supply of neoplasms in the liver. *Am J Pathol* 1954;30:969-977. Available at: <https://www.ncbi.nlm.nih.gov/pubmed/13197542>.

607. Reddy SK, Kesmodel SB, Alexander HR, Jr. Isolated hepatic perfusion for patients with liver metastases. *Ther Adv Med Oncol* 2014;6:180-194. Available at: <https://www.ncbi.nlm.nih.gov/pubmed/25057304>.

608. Alexander HR, Libutti SK, Bartlett DL, et al. A phase I-II study of isolated hepatic perfusion using melphalan with or without tumor necrosis factor for patients with ocular melanoma metastatic to liver. *Clin Cancer Res* 2000;6:3062-3070. Available at: <https://www.ncbi.nlm.nih.gov/pubmed/10955785>.

609. Alexander HR, Jr., Libutti SK, Pingpank JF, et al. Hyperthermic isolated hepatic perfusion using melphalan for patients with ocular melanoma metastatic to liver. *Clin Cancer Res* 2003;9:6343-6349. Available at: <https://www.ncbi.nlm.nih.gov/pubmed/14695133>.

610. Noter SL, Rothbarth J, Pijl ME, et al. Isolated hepatic perfusion with high-dose melphalan for the treatment of uveal melanoma metastases confined to the liver. *Melanoma Res* 2004;14:67-72. Available at: <https://www.ncbi.nlm.nih.gov/pubmed/15091197>.

611. Olofsson R, Cahlin C, All-Ericsson C, et al. Isolated hepatic perfusion for ocular melanoma metastasis: registry data suggests a survival benefit. *Ann Surg Oncol* 2014;21:466-472. Available at: <https://www.ncbi.nlm.nih.gov/pubmed/24141377>.

612. Varghese S, Xu H, Bartlett D, et al. Isolated hepatic perfusion with high-dose melphalan results in immediate alterations in tumor gene expression in patients with metastatic ocular melanoma. *Ann Surg Oncol* 2010;17:1870-1877. Available at: <https://www.ncbi.nlm.nih.gov/pubmed/20221901>.

613. Ben-Shabat I, Belgrano V, Ny L, et al. Long-Term Follow-Up Evaluation of 68 Patients with Uveal Melanoma Liver Metastases Treated with Isolated Hepatic Perfusion. *Ann Surg Oncol* 2016;23:1327-1334. Available at: <https://www.ncbi.nlm.nih.gov/pubmed/26628434>.

614. van Iersel LB, Hoekman EJ, Gelderblom H, et al. Isolated hepatic perfusion with 200 mg melphalan for advanced noncolorectal liver metastases. *Ann Surg Oncol* 2008;15:1891-1898. Available at: <https://www.ncbi.nlm.nih.gov/pubmed/18470571>.

615. Ben-Shabat I, Belgrano V, Hansson C, Olofsson Bagge R. The effect of perfusate buffering on toxicity and response in isolated hepatic perfusion for uveal melanoma liver metastases. *Int J Hyperthermia* 2017;33:483-488. Available at: <https://www.ncbi.nlm.nih.gov/pubmed/28110582>.

616. de Leede EM, Burgmans MC, Kapiteijn E, et al. Isolated (hypoxic) hepatic perfusion with high-dose chemotherapy in patients with unresectable liver metastases of uveal melanoma: results from two experienced centres. *Melanoma Res* 2016;26:588-594. Available at: <https://www.ncbi.nlm.nih.gov/pubmed/27513071>.

617. Cantore M, Fiorentini G, Aitini E, et al. Intra-arterial hepatic carboplatin-based chemotherapy for ocular melanoma metastatic to the liver. Report of a phase II study. *Tumori* 1994;80:37-39. Available at: <https://www.ncbi.nlm.nih.gov/pubmed/8191596>.



618. Leyvraz S, Spataro V, Bauer J, et al. Treatment of ocular melanoma metastatic to the liver by hepatic arterial chemotherapy. *J Clin Oncol* 1997;15:2589-2595. Available at:

<https://www.ncbi.nlm.nih.gov/pubmed/9215829>.

619. Egerer G, Lehnert T, Max R, et al. Pilot study of hepatic intraarterial fotemustine chemotherapy for liver metastases from uveal melanoma: a single-center experience with seven patients. *Int J Clin Oncol* 2001;6:25-28. Available at: <https://www.ncbi.nlm.nih.gov/pubmed/11706523>.

620. Vera-Aguilera J, Bedikian AY, Bassett RL, et al. Phase I/II Study of Hepatic Arterial Infusion of Nab-paclitaxel in Patients With Metastatic Melanoma to the Liver. *Am J Clin Oncol* 2018;41:1132-1136. Available at: <https://www.ncbi.nlm.nih.gov/pubmed/29509591>.

621. Jansen YJL, Verset G, Schats K, et al. Phase I clinical trial of decitabine (5-aza-2'-deoxycytidine) administered by hepatic arterial infusion in patients with unresectable liver-predominant metastases. *ESMO Open* 2019;4:e000464. Available at:

<https://www.ncbi.nlm.nih.gov/pubmed/30962963>.

622. Peters S, Voelter V, Zografos L, et al. Intra-arterial hepatic fotemustine for the treatment of liver metastases from uveal melanoma: experience in 101 patients. *Ann Oncol* 2006;17:578-583. Available at:

<https://www.ncbi.nlm.nih.gov/pubmed/16469752>.

623. Siegel R, Hauschild A, Kettelhack C, et al. Hepatic arterial Fotemustine chemotherapy in patients with liver metastases from cutaneous melanoma is as effective as in ocular melanoma. *Eur J Surg Oncol* 2007;33:627-632. Available at:

<https://www.ncbi.nlm.nih.gov/pubmed/17196362>.

624. Melichar B, Voboril Z, Lojik M, Krajina A. Liver metastases from uveal melanoma: clinical experience of hepatic arterial infusion of cisplatin, vinblastine and dacarbazine. *Hepatogastroenterology* 2009;56:1157-1162. Available at:

<https://www.ncbi.nlm.nih.gov/pubmed/19760961>.

625. Farolfi A, Ridolfi L, Guidoboni M, et al. Liver metastases from melanoma: hepatic intra-arterial chemotherapy. A retrospective study. *J Chemother* 2011;23:300-305. Available at:

<https://www.ncbi.nlm.nih.gov/pubmed/22005064>.

626. Heusner TA, Antoch G, Wittkowski-Sterczewski A, et al. Transarterial hepatic chemoperfusion of uveal melanoma metastases: survival and response to treatment. *Rofo* 2011;183:1151-1160. Available at: <https://www.ncbi.nlm.nih.gov/pubmed/22033849>.

627. de Leede EM, Burgmans MC, Meijer TS, et al. Prospective Clinical and Pharmacological Evaluation of the Delcath System's Second-Generation (GEN2) Hemofiltration System in Patients Undergoing Percutaneous Hepatic Perfusion with Melphalan. *Cardiovasc Intervent Radiol* 2017;40:1196-1205. Available at:

<https://www.ncbi.nlm.nih.gov/pubmed/28451811>.

628. Hughes MS, Zager J, Faries M, et al. Results of a Randomized Controlled Multicenter Phase III Trial of Percutaneous Hepatic Perfusion Compared with Best Available Care for Patients with Melanoma Liver Metastases. *Ann Surg Oncol* 2016;23:1309-1319. Available at:

<https://www.ncbi.nlm.nih.gov/pubmed/26597368>.

629. Meijer TS, Burgmans MC, Fiocco M, et al. Safety of Percutaneous Hepatic Perfusion with Melphalan in Patients with Unresectable Liver Metastases from Ocular Melanoma Using the Delcath Systems' Second-Generation Hemofiltration System: A Prospective Non-randomized Phase II Trial. *Cardiovasc Intervent Radiol* 2019;42:841-852. Available at: <https://www.ncbi.nlm.nih.gov/pubmed/30767147>.

630. Vogl TJ, Koch SA, Lotz G, et al. Percutaneous Isolated Hepatic Perfusion as a Treatment for Isolated Hepatic Metastases of Uveal Melanoma: Patient Outcome and Safety in a Multi-centre Study. *Cardiovasc Intervent Radiol* 2017;40:864-872. Available at:

<https://www.ncbi.nlm.nih.gov/pubmed/28144756>.



631. Karydis I, Gangi A, Wheeler MJ, et al. Percutaneous hepatic perfusion with melphalan in uveal melanoma: A safe and effective treatment modality in an orphan disease. *J Surg Oncol* 2018;117:1170-1178. Available at: <https://www.ncbi.nlm.nih.gov/pubmed/29284076>.

632. Artzner C, Mossakowski O, Heffernan G, et al. Chemosaturation with percutaneous hepatic perfusion of melphalan for liver-dominant metastatic uveal melanoma: a single center experience. *Cancer Imaging* 2019;19:31. Available at: <https://www.ncbi.nlm.nih.gov/pubmed/31146793>.

633. Mavligit GM, Charnsangavej C, Carrasco CH, et al. Regression of ocular melanoma metastatic to the liver after hepatic arterial chemoembolization with cisplatin and polyvinyl sponge. *JAMA* 1988;260:974-976. Available at: <https://www.ncbi.nlm.nih.gov/pubmed/3398202>.

634. Bedikian AY, Legha SS, Mavligit G, et al. Treatment of uveal melanoma metastatic to the liver: a review of the M. D. Anderson Cancer Center experience and prognostic factors. *Cancer* 1995;76:1665-1670. Available at: <https://www.ncbi.nlm.nih.gov/pubmed/8635073>.

635. Dayani PN, Gould JE, Brown DB, et al. Hepatic metastasis from uveal melanoma: angiographic pattern predictive of survival after hepatic arterial chemoembolization. *Arch Ophthalmol* 2009;127:628-632. Available at: <https://www.ncbi.nlm.nih.gov/pubmed/19433711>.

636. Schuster R, Lindner M, Wacker F, et al. Transarterial chemoembolization of liver metastases from uveal melanoma after failure of systemic therapy: toxicity and outcome. *Melanoma Res* 2010;20:191-196. Available at: <https://www.ncbi.nlm.nih.gov/pubmed/20335820>.

637. Gupta S, Bedikian AY, Ahrar J, et al. Hepatic artery chemoembolization in patients with ocular melanoma metastatic to the liver: response, survival, and prognostic factors. *Am J Clin Oncol* 2010;33:474-480. Available at: <https://www.ncbi.nlm.nih.gov/pubmed/19935383>.

638. Duran R, Chapiro J, Frangakis C, et al. Uveal Melanoma Metastatic to the Liver: The Role of Quantitative Volumetric Contrast-Enhanced MR Imaging in the Assessment of Early Tumor Response after Transarterial Chemoembolization. *Transl Oncol* 2014;7:447-455. Available at: <https://www.ncbi.nlm.nih.gov/pubmed/24953419>.

639. Gonsalves CF, Eschelmann DJ, Thornburg B, et al. Uveal Melanoma Metastatic to the Liver: Chemoembolization With 1,3-Bis-(2-Chloroethyl)-1-Nitrosourea. *AJR Am J Roentgenol* 2015;205:429-433. Available at: <https://www.ncbi.nlm.nih.gov/pubmed/25905562>.

640. Shibayama Y, Namikawa K, Sone M, et al. Efficacy and toxicity of transarterial chemoembolization therapy using cisplatin and gelatin sponge in patients with liver metastases from uveal melanoma in an Asian population. *Int J Clin Oncol* 2017;22:577-584. Available at: <https://www.ncbi.nlm.nih.gov/pubmed/28144882>.

641. Patel K, Sullivan K, Berd D, et al. Chemoembolization of the hepatic artery with BCNU for metastatic uveal melanoma: results of a phase II study. *Melanoma Res* 2005;15:297-304. Available at: <https://www.ncbi.nlm.nih.gov/pubmed/16034309>.

642. Huppert PE, Fierlbeck G, Pereira P, et al. Transarterial chemoembolization of liver metastases in patients with uveal melanoma. *Eur J Radiol* 2010;74:e38-44. Available at: <https://www.ncbi.nlm.nih.gov/pubmed/19467811>.

643. Yamamoto A, Chervoneva I, Sullivan KL, et al. High-dose immunoembolization: survival benefit in patients with hepatic metastases from uveal melanoma. *Radiology* 2009;252:290-298. Available at: <https://www.ncbi.nlm.nih.gov/pubmed/19561263>.

644. Edelhauser G, Schicher N, Berzaczy D, et al. Fotemustine chemoembolization of hepatic metastases from uveal melanoma: a retrospective single-center analysis. *AJR Am J Roentgenol* 2012;199:1387-1392. Available at: <https://www.ncbi.nlm.nih.gov/pubmed/23169735>.



645. Vogl T, Eichler K, Zangos S, et al. Preliminary experience with transarterial chemoembolization (TACE) in liver metastases of uveal malignant melanoma: local tumor control and survival. *J Cancer Res Clin Oncol* 2007;133:177-184. Available at: <https://www.ncbi.nlm.nih.gov/pubmed/17021903>.

646. Fiorentini G, Aliberti C, Del Conte A, et al. Intra-arterial hepatic chemoembolization (TACE) of liver metastases from ocular melanoma with slow-release irinotecan-eluting beads. Early results of a phase II clinical study. *In Vivo* 2009;23:131-137. Available at: <https://www.ncbi.nlm.nih.gov/pubmed/19368137>.

647. Rostas JW, Tam AL, Sato T, et al. Health-related quality of life during trans-arterial chemoembolization with drug-eluting beads loaded with doxorubicin (DEBDOX) for unresectable hepatic metastases from ocular melanoma. *Am J Surg* 2017;214:884-890. Available at: <https://www.ncbi.nlm.nih.gov/pubmed/28754534>.

648. Carling U, Dorenberg EJ, Haugvik SP, et al. Transarterial Chemoembolization of Liver Metastases from Uveal Melanoma Using Irinotecan-Loaded Beads: Treatment Response and Complications. *Cardiovasc Intervent Radiol* 2015;38:1532-1541. Available at: <https://www.ncbi.nlm.nih.gov/pubmed/25832764>.

649. Valpione S, Aliberti C, Parrozzani R, et al. A retrospective analysis of 141 patients with liver metastases from uveal melanoma: a two-cohort study comparing transarterial chemoembolization with CPT-11 charged microbeads and historical treatments. *Melanoma Res* 2015;25:164-168. Available at: <https://www.ncbi.nlm.nih.gov/pubmed/25521594>.

650. Sharma KV, Gould JE, Harbour JW, et al. Hepatic arterial chemoembolization for management of metastatic melanoma. *AJR Am J Roentgenol* 2008;190:99-104. Available at: <https://www.ncbi.nlm.nih.gov/pubmed/18094299>.

651. Sato T, Eschelman DJ, Gonsalves CF, et al. Immunoembolization of malignant liver tumors, including uveal melanoma, using granulocyte-macrophage colony-stimulating factor. *J Clin Oncol* 2008;26:5436-5442. Available at: <https://www.ncbi.nlm.nih.gov/pubmed/18838710>.

652. Valsecchi ME, Terai M, Eschelman DJ, et al. Double-blinded, randomized phase II study using embolization with or without granulocyte-macrophage colony-stimulating factor in uveal melanoma with hepatic metastases. *J Vasc Interv Radiol* 2015;26:523-532 e522. Available at: <https://www.ncbi.nlm.nih.gov/pubmed/25678394>.

653. Kennedy AS, Nutting C, Jakobs T, et al. A first report of radioembolization for hepatic metastases from ocular melanoma. *Cancer Invest* 2009;27:682-690. Available at: <https://www.ncbi.nlm.nih.gov/pubmed/19219675>.

654. Gonsalves CF, Eschelman DJ, Sullivan KL, et al. Radioembolization as salvage therapy for hepatic metastasis of uveal melanoma: a single-institution experience. *AJR Am J Roentgenol* 2011;196:468-473. Available at: <https://www.ncbi.nlm.nih.gov/pubmed/21257902>.

655. Klingenstein A, Haug AR, Zech CJ, Schaller UC. Radioembolization as locoregional therapy of hepatic metastases in uveal melanoma patients. *Cardiovasc Intervent Radiol* 2013;36:158-165. Available at: <https://www.ncbi.nlm.nih.gov/pubmed/22526099>.

656. Eldredge-Hindy H, Ohri N, Anne PR, et al. Yttrium-90 Microsphere Brachytherapy for Liver Metastases From Uveal Melanoma: Clinical Outcomes and the Predictive Value of Fluorodeoxyglucose Positron Emission Tomography. *Am J Clin Oncol* 2016;39:189-195. Available at: <https://www.ncbi.nlm.nih.gov/pubmed/24441583>.

657. Tulokas S, Maenpaa H, Peltola E, et al. Selective internal radiation therapy (SIRT) as treatment for hepatic metastases of uveal melanoma: a Finnish nation-wide retrospective experience. *Acta Oncol* 2018;57:1373-1380. Available at: <https://www.ncbi.nlm.nih.gov/pubmed/29683787>.

658. Ponti A, Denys A, Digkila A, et al. First-Line Selective Internal Radiation Therapy in Patients with Uveal Melanoma Metastatic to the Liver. *J Nucl Med* 2020;61:350-356. Available at: <https://www.ncbi.nlm.nih.gov/pubmed/31481579>.



659. Gonsalves CF, Eschelman DJ, Adamo RD, et al. A Prospective Phase II Trial of Radioembolization for Treatment of Uveal Melanoma Hepatic Metastasis. *Radiology* 2019;293:223-231. Available at: <https://www.ncbi.nlm.nih.gov/pubmed/31453767>.

660. Putzer D, Schullian P, Bale R. Locoregional ablative treatment of melanoma metastases. *Int J Hyperthermia* 2019;36:59-63. Available at: <https://www.ncbi.nlm.nih.gov/pubmed/31537161>.

661. Holzwanger DJ, Madoff DC. Role of interventional radiology in the management of hepatocellular carcinoma: current status. *Chin Clin Oncol* 2018;7:49. Available at: <https://www.ncbi.nlm.nih.gov/pubmed/30180753>.

662. Glassberg MB, Ghosh S, Clymer JW, et al. Microwave ablation compared with radiofrequency ablation for treatment of hepatocellular carcinoma and liver metastases: a systematic review and meta-analysis. *Onco Targets Ther* 2019;12:6407-6438. Available at: <https://www.ncbi.nlm.nih.gov/pubmed/31496742>.

663. Poulou LS, Botsa E, Thanou I, et al. Percutaneous microwave ablation vs radiofrequency ablation in the treatment of hepatocellular carcinoma. *World J Hepatol* 2015;7:1054-1063. Available at: <https://www.ncbi.nlm.nih.gov/pubmed/26052394>.

664. Lewandowski RJ, Salem R. Microwave or radiofrequency ablation: clinically equivalent? *Lancet Gastroenterol Hepatol* 2018;3:291-292. Available at: <https://www.ncbi.nlm.nih.gov/pubmed/29503248>.

665. Facciorusso A, Di Maso M, Muscatiello N. Microwave ablation versus radiofrequency ablation for the treatment of hepatocellular carcinoma: A systematic review and meta-analysis. *Int J Hyperthermia* 2016;32:339-344. Available at: <https://www.ncbi.nlm.nih.gov/pubmed/26794414>.

666. Huo YR, Eslick GD. Microwave Ablation Compared to Radiofrequency Ablation for Hepatic Lesions: A Meta-Analysis. *J Vasc Interv Radiol* 2015;26:1139-1146 e1132. Available at: <https://www.ncbi.nlm.nih.gov/pubmed/26027937>.

667. Vietti Violi N, Duran R, Guiu B, et al. Efficacy of microwave ablation versus radiofrequency ablation for the treatment of hepatocellular carcinoma in patients with chronic liver disease: a randomised controlled phase 2 trial. *Lancet Gastroenterol Hepatol* 2018;3:317-325. Available at: <https://www.ncbi.nlm.nih.gov/pubmed/29503247>.

668. Mahnken AH, Konig AM, Figiel JH. Current Technique and Application of Percutaneous Cryotherapy. *Rofo* 2018;190:836-846. Available at: <https://www.ncbi.nlm.nih.gov/pubmed/29665588>.

669. Shiina S, Sato K, Tateishi R, et al. Percutaneous Ablation for Hepatocellular Carcinoma: Comparison of Various Ablation Techniques and Surgery. *Can J Gastroenterol Hepatol* 2018;2018:4756147. Available at: <https://www.ncbi.nlm.nih.gov/pubmed/29974040>.

670. Bala MM, Riemsma RP, Wolff R, et al. Cryotherapy for liver metastases. *Cochrane Database Syst Rev* 2019;7:CD009058. Available at: <https://www.ncbi.nlm.nih.gov/pubmed/31291464>.

671. Wu S, Hou J, Ding Y, et al. Cryoablation Versus Radiofrequency Ablation for Hepatic Malignancies: A Systematic Review and Literature-Based Analysis. *Medicine (Baltimore)* 2015;94:e2252. Available at: <https://www.ncbi.nlm.nih.gov/pubmed/26656371>.

672. Pearson AS, Izzo F, Fleming RY, et al. Intraoperative radiofrequency ablation or cryoablation for hepatic malignancies. *Am J Surg* 1999;178:592-599. Available at: <https://www.ncbi.nlm.nih.gov/pubmed/10670879>.

673. Huang YZ, Zhou SC, Zhou H, Tong M. Radiofrequency ablation versus cryosurgery ablation for hepatocellular carcinoma: a meta-analysis. *Hepatogastroenterology* 2013;60:1131-1135. Available at: <https://www.ncbi.nlm.nih.gov/pubmed/23321123>.

674. Eichler K, Zangos S, Gruber-Rouh T, et al. MR-guided laser-induced thermotherapy (LITT) in patients with liver metastases of uveal melanoma. *J Eur Acad Dermatol Venereol* 2014;28:1756-1760. Available at: <https://www.ncbi.nlm.nih.gov/pubmed/24593299>.



NCCN Guidelines Version 2.2021

Melanoma: Uveal

675. Bale R, Schullian P, Schmuth M, et al. Stereotactic Radiofrequency Ablation for Metastatic Melanoma to the Liver. *Cardiovasc Intervent Radiol* 2016;39:1128-1135. Available at: <https://www.ncbi.nlm.nih.gov/pubmed/27055850>.

676. White ML, Atwell TD, Kurup AN, et al. Recurrence and Survival Outcomes After Percutaneous Thermal Ablation of Oligometastatic Melanoma. *Mayo Clin Proc* 2016;91:288-296. Available at: <https://www.ncbi.nlm.nih.gov/pubmed/26827235>.

677. Rozeman EA, Prevoo W, Meier MAJ, et al. Phase Ib/II trial testing combined radiofrequency ablation and ipilimumab in uveal melanoma (SECIRA-UM). *Melanoma Res* 2020. Available at: <https://www.ncbi.nlm.nih.gov/pubmed/31895753>.

678. Bedikian AY, Papadopoulos N, Plager C, et al. Phase II evaluation of temozolomide in metastatic choroidal melanoma. *Melanoma Res* 2003;13:303-306. Available at: <https://www.ncbi.nlm.nih.gov/pubmed/12777987>.

679. Homsy J, Bedikian AY, Papadopoulos NE, et al. Phase 2 open-label study of weekly docosahexaenoic acid-paclitaxel in patients with metastatic uveal melanoma. *Melanoma Res* 2010;20:507-510. Available at: <https://www.ncbi.nlm.nih.gov/pubmed/20881508>.

680. Bedikian AY, Plager C, Papadopoulos N, et al. Phase II evaluation of paclitaxel by short intravenous infusion in metastatic melanoma. *Melanoma Res* 2004;14:63-66. Available at: <https://www.ncbi.nlm.nih.gov/pubmed/15091196>.

681. Schmittl A, Schmidt-Hieber M, Martus P, et al. A randomized phase II trial of gemcitabine plus treosulfan versus treosulfan alone in patients with metastatic uveal melanoma. *Ann Oncol* 2006;17:1826-1829. Available at: <https://www.ncbi.nlm.nih.gov/pubmed/16971664>.

682. Schmidt-Hieber M, Schmittl A, Thiel E, Keilholz U. A phase II study of bendamustine chemotherapy as second-line treatment in metastatic uveal melanoma. *Melanoma Res* 2004;14:439-442. Available at: <https://www.ncbi.nlm.nih.gov/pubmed/15577312>.

683. Bedikian AY, Papadopoulos NE, Kim KB, et al. A pilot study with vincristine sulfate liposome infusion in patients with metastatic melanoma. *Melanoma Res* 2008;18:400-404. Available at: <https://www.ncbi.nlm.nih.gov/pubmed/19011511>.

684. Carvajal RD, Piperno-Neumann S, Kapiteijn E, et al. Selumetinib in Combination With Dacarbazine in Patients With Metastatic Uveal Melanoma: A Phase III, Multicenter, Randomized Trial (SUMIT). *J Clin Oncol* 2018;36:1232-1239. Available at: <https://www.ncbi.nlm.nih.gov/pubmed/29528792>.

685. Carvajal RD, Sosman JA, Quevedo JF, et al. Effect of selumetinib vs chemotherapy on progression-free survival in uveal melanoma: a randomized clinical trial. *JAMA* 2014;311:2397-2405. Available at: <https://www.ncbi.nlm.nih.gov/pubmed/24938562>.

686. Sacco JJ, Nathan PD, Danson S, et al. Sunitinib versus dacarbazine as first-line treatment in patients with metastatic uveal melanoma. *J Clin Oncol* 2013;31:9031-9031. Available at: https://ascopubs.org/doi/abs/10.1200/jco.2013.31.15_suppl.9031.

687. Luke JJ, Olson DJ, Allred JB, et al. Randomized Phase II Trial and Tumor Mutational Spectrum Analysis from Cabozantinib versus Chemotherapy in Metastatic Uveal Melanoma (Alliance A091201). *Clin Cancer Res* 2019. Available at: <https://www.ncbi.nlm.nih.gov/pubmed/31558480>.

688. Kim KB, Bedikian AY, Camacho LH, et al. A phase II trial of arsenic trioxide in patients with metastatic melanoma. *Cancer* 2005;104:1687-1692. Available at: <https://www.ncbi.nlm.nih.gov/pubmed/16130126>.

689. Hofmann UB, Kauczok-Vetter CS, Houben R, Becker JC. Overexpression of the KIT/SCF in uveal melanoma does not translate into clinical efficacy of imatinib mesylate. *Clin Cancer Res* 2009;15:324-329. Available at: <https://www.ncbi.nlm.nih.gov/pubmed/19118061>.



690. Penel N, Delcambre C, Durando X, et al. O-Mel-Inib: a Cancero-pole Nord-Ouest multicenter phase II trial of high-dose imatinib mesylate in metastatic uveal melanoma. *Invest New Drugs* 2008;26:561-565. Available at: <https://www.ncbi.nlm.nih.gov/pubmed/18551246>.

691. Mouriaux F, Servois V, Parienti JJ, et al. Sorafenib in metastatic uveal melanoma: efficacy, toxicity and health-related quality of life in a multicentre phase II study. *Br J Cancer* 2016;115:20-24. Available at: <https://www.ncbi.nlm.nih.gov/pubmed/27253171>.

692. Mahipal A, Tijani L, Chan K, et al. A pilot study of sunitinib malate in patients with metastatic uveal melanoma. *Melanoma Res* 2012;22:440-446. Available at: <https://www.ncbi.nlm.nih.gov/pubmed/23114504>.

693. Shoushtari AN, Kudchadkar RR, Panageas K, et al. A randomized phase 2 study of trametinib with or without GSK2141795 in patients with advanced uveal melanoma. *J Clin Oncol* 2016;34:9511-9511. Available at: http://ascopubs.org/doi/abs/10.1200/JCO.2016.34.15_suppl.9511.

694. Falchook GS, Lewis KD, Infante JR, et al. Activity of the oral MEK inhibitor trametinib in patients with advanced melanoma: a phase 1 dose-escalation trial. *Lancet Oncol* 2012;13:782-789. Available at: <https://www.ncbi.nlm.nih.gov/pubmed/22805292>.

695. Daud A, Kluger HM, Kurzrock R, et al. Phase II randomised discontinuation trial of the MET/VEGF receptor inhibitor cabozantinib in metastatic melanoma. *Br J Cancer* 2017;116:432-440. Available at: <https://www.ncbi.nlm.nih.gov/pubmed/28103611>.

696. Shah S, Luke JJ, Jacene HA, et al. Results from phase II trial of HSP90 inhibitor, STA-9090 (ganetespib), in metastatic uveal melanoma. *Melanoma Res* 2018;28:605-610. Available at: <https://www.ncbi.nlm.nih.gov/pubmed/30211813>.

697. Shoushtari AN, Ong LT, Schoder H, et al. A phase 2 trial of everolimus and pasireotide long-acting release in patients with metastatic uveal melanoma. *Melanoma Res* 2016;26:272-277. Available at: <https://www.ncbi.nlm.nih.gov/pubmed/26795274>.

698. Tarhini AA, Frankel P, Margolin KA, et al. Aflibercept (VEGF Trap) in inoperable stage III or stage IV melanoma of cutaneous or uveal origin. *Clin Cancer Res* 2011;17:6574-6581. Available at: <https://www.ncbi.nlm.nih.gov/pubmed/21880788>.

699. Ellerhorst JA, Bedikian AY, Smith TM, et al. Phase II trial of 9-nitrocamptothecin (RFS 2000) for patients with metastatic cutaneous or uveal melanoma. *Anticancer Drugs* 2002;13:169-172. Available at: <https://www.ncbi.nlm.nih.gov/pubmed/11901310>.

700. Sato T, Nathan PD, Hernandez-Aya LF, et al. Intra-patient escalation dosing strategy with IMCgp100 results in mitigation of T-cell based toxicity and preliminary efficacy in advanced uveal melanoma. *J Clin Oncol* 2017;35:9531-9531. Available at: https://ascopubs.org/doi/abs/10.1200/JCO.2017.35.15_suppl.9531.

701. Chandran SS, Somerville RPT, Yang JC, et al. Treatment of metastatic uveal melanoma with adoptive transfer of tumour-infiltrating lymphocytes: a single-centre, two-stage, single-arm, phase 2 study. *Lancet Oncol* 2017;18:792-802. Available at: <https://www.ncbi.nlm.nih.gov/pubmed/28395880>.

702. Bol KF, Mensink HW, Aarntzen EH, et al. Long overall survival after dendritic cell vaccination in metastatic uveal melanoma patients. *Am J Ophthalmol* 2014;158:939-947. Available at: <https://www.ncbi.nlm.nih.gov/pubmed/25038326>.

703. Borden EC, Jacobs B, Hollovary E, et al. Gene regulatory and clinical effects of interferon beta in patients with metastatic melanoma: a phase II trial. *J Interferon Cytokine Res* 2011;31:433-440. Available at: <https://www.ncbi.nlm.nih.gov/pubmed/21235385>.

704. Zimmer L, Vaubel J, Mohr P, et al. Phase II DeCOG-study of ipilimumab in pretreated and treatment-naïve patients with metastatic uveal melanoma. *PLoS One* 2015;10:e0118564. Available at: <https://www.ncbi.nlm.nih.gov/pubmed/25761109>.



705. Joshua AM, Monzon JG, Mihalciou C, et al. A phase 2 study of tremelimumab in patients with advanced uveal melanoma. *Melanoma Res* 2015;25:342-347. Available at:

<https://www.ncbi.nlm.nih.gov/pubmed/26050146>.

706. Piulats Rodriguez JM, Ochoa de Olza M, Codes M, et al. Phase II study evaluating ipilimumab as a single agent in the first-line treatment of adult patients (Pts) with metastatic uveal melanoma (MUM): The GEM-1 trial. *J Clin Oncol* 2014;32:9033-9033. Available at:

https://ascopubs.org/doi/abs/10.1200/jco.2014.32.15_suppl.9033.

707. Johnson DB, Bao R, Ancell KK, et al. Response to Anti-PD-1 in Uveal Melanoma Without High-Volume Liver Metastasis. *J Natl Compr Canc Netw* 2019;17:114-117. Available at:

<https://www.ncbi.nlm.nih.gov/pubmed/30787124>.

708. van der Kooij MK, Joosse A, Speetjens FM, et al. Anti-PD1 treatment in metastatic uveal melanoma in the Netherlands. *Acta Oncol* 2017;56:101-103. Available at:

<https://www.ncbi.nlm.nih.gov/pubmed/27911126>.

709. Rossi E, Pagliara MM, Orteschi D, et al. Pembrolizumab as first-line treatment for metastatic uveal melanoma. *Cancer Immunol Immunother* 2019;68:1179-1185. Available at:

<https://www.ncbi.nlm.nih.gov/pubmed/31175402>.

710. Schadendorf D, Ascierto PA, Haanen JBAG, et al. Efficacy and safety of nivolumab (NIVO) in patients with advanced melanoma (MEL) and poor prognostic factors who progressed on or after ipilimumab (IPI): Results from a phase II study (CheckMate 172). *J Clin Oncol* 2017;35:9524-9524. Available at:

https://ascopubs.org/doi/abs/10.1200/JCO.2017.35.15_suppl.9524.

711. Pelster M, Gruschus SK, Bassett R, et al. Phase II study of ipilimumab and nivolumab (ipi/nivo) in metastatic uveal melanoma (UM). *J Clin Oncol* 2019;37:9522-9522. Available at:

https://ascopubs.org/doi/abs/10.1200/JCO.2019.37.15_suppl.9522.

712. Piulats JM, Ochoa-de-Olza M, Lopez-Martin JA, et al. Phase II study evaluating Ipilimumab monotherapy in the first-line treatment of adult patients with metastatic uveal melanoma (MUM): The GEM1 trial [abstract]. *Pigment Cell Melanoma Res* 2014;27:1209. Available at:

<https://onlinelibrary.wiley.com/doi/10.1111/pcmr.12317>.

713. Piulats JM, De La Cruz-Merino L, Curiel Garcia MT, et al. Phase II multicenter, single arm, open label study of nivolumab (NIVO) in combination with ipilimumab (IPI) as first line in adult patients (pts) with metastatic uveal melanoma (MUM): GEM1402 NCT02626962. *J Clin Oncol* 2017;35:9533-9533. Available at:

http://ascopubs.org/doi/abs/10.1200/JCO.2017.35.15_suppl.9533.

714. Schmittel A, Schuster R, Bechrakis NE, et al. A two-cohort phase II clinical trial of gemcitabine plus treosulfan in patients with metastatic uveal melanoma. *Melanoma Res* 2005;15:447-451. Available at:

<https://www.ncbi.nlm.nih.gov/pubmed/16179873>.

715. Corrie PG, Shaw J, Spanswick VJ, et al. Phase I trial combining gemcitabine and treosulfan in advanced cutaneous and uveal melanoma patients. *Br J Cancer* 2005;92:1997-2003. Available at:

<https://www.ncbi.nlm.nih.gov/pubmed/15886706>.

716. Keilholz U, Schuster R, Schmittel A, et al. A clinical phase I trial of gemcitabine and treosulfan in uveal melanoma and other solid tumours. *Eur J Cancer* 2004;40:2047-2052. Available at:

<https://www.ncbi.nlm.nih.gov/pubmed/15341977>.

717. Terheyden P, Bocker EB, Becker JC. Clinical evaluation of in vitro chemosensitivity testing: the example of uveal melanoma. *J Cancer Res Clin Oncol* 2004;130:395-399. Available at:

<https://www.ncbi.nlm.nih.gov/pubmed/15160290>.

718. Pföhler C, Cree IA, Ugurel S, et al. Treosulfan and gemcitabine in metastatic uveal melanoma patients: results of a multicenter feasibility study. *Anticancer Drugs* 2003;14:337-340. Available at:

<https://www.ncbi.nlm.nih.gov/pubmed/12782938>.



719. Schmitt A, Scheulen ME, Bechrakis NE, et al. Phase II trial of cisplatin, gemcitabine and treosulfan in patients with metastatic uveal melanoma. *Melanoma Res* 2005;15:205-207. Available at: <https://www.ncbi.nlm.nih.gov/pubmed/15917703>.

720. O'Neill PA, Butt M, Eswar CV, et al. A prospective single arm phase II study of dacarbazine and treosulfan as first-line therapy in metastatic uveal melanoma. *Melanoma Res* 2006;16:245-248. Available at: <https://www.ncbi.nlm.nih.gov/pubmed/16718271>.

721. Schinzari G, Rossi E, Cassano A, et al. Cisplatin, dacarbazine and vinblastine as first line chemotherapy for liver metastatic uveal melanoma in the era of immunotherapy: a single institution phase II study. *Melanoma Res* 2017;27:591-595. Available at: <https://www.ncbi.nlm.nih.gov/pubmed/29076951>.

722. Lee CK, Jung M, Choi HJ, et al. Results of a Phase II Study to Evaluate the Efficacy of Docetaxel and Carboplatin in Metastatic Malignant Melanoma Patients Who Failed First-Line Therapy Containing Dacarbazine. *Cancer Res Treat* 2015;47:781-789. Available at: <https://www.ncbi.nlm.nih.gov/pubmed/25687848>.

723. Bedikian AY, Legha SS, Eton O, et al. Phase II trial of tirapazamine combined with cisplatin in chemotherapy of advanced malignant melanoma. *Ann Oncol* 1997;8:363-367. Available at: <https://www.ncbi.nlm.nih.gov/pubmed/9209666>.

724. Kivela T, Suci S, Hansson J, et al. Bleomycin, vincristine, lomustine and dacarbazine (BOLD) in combination with recombinant interferon alpha-2b for metastatic uveal melanoma. *Eur J Cancer* 2003;39:1115-1120. Available at: <https://www.ncbi.nlm.nih.gov/pubmed/12736111>.

725. Pyrhonen S, Hahka-Kemppinen M, Muhonen T, et al. Chemoimmunotherapy with bleomycin, vincristine, lomustine, dacarbazine (BOLD), and human leukocyte interferon for metastatic uveal melanoma. *Cancer* 2002;95:2366-2372. Available at: <https://www.ncbi.nlm.nih.gov/pubmed/12436444>.

726. Becker JC, Terheyden P, Kampgen E, et al. Treatment of disseminated ocular melanoma with sequential fotemustine, interferon alpha, and interleukin 2. *Br J Cancer* 2002;87:840-845. Available at: <https://www.ncbi.nlm.nih.gov/pubmed/12373596>.

727. Nathan FE, Berd D, Sato T, et al. BOLD+interferon in the treatment of metastatic uveal melanoma: first report of active systemic therapy. *J Exp Clin Cancer Res* 1997;16:201-208. Available at: <https://www.ncbi.nlm.nih.gov/pubmed/9261748>.

728. McWilliams RR, Allred JB, Slostad JA, et al. NCCTG N0879 (Alliance): A randomized phase 2 cooperative group trial of carboplatin, paclitaxel, and bevacizumab +/- everolimus for metastatic melanoma. *Cancer* 2018;124:537-545. Available at: <https://www.ncbi.nlm.nih.gov/pubmed/29044496>.

729. Guenterberg KD, Grignol VP, Relekar KV, et al. A pilot study of bevacizumab and interferon-alpha2b in ocular melanoma. *Am J Clin Oncol* 2011;34:87-91. Available at: <https://www.ncbi.nlm.nih.gov/pubmed/20458209>.

730. Solti M, Berd D, Mastrangelo MJ, Sato T. A pilot study of low-dose thalidomide and interferon alpha-2b in patients with metastatic melanoma who failed prior treatment. *Melanoma Res* 2007;17:225-231. Available at: <https://www.ncbi.nlm.nih.gov/pubmed/17625452>.

731. Bhatia S, Moon J, Margolin KA, et al. Phase II trial of sorafenib in combination with carboplatin and paclitaxel in patients with metastatic uveal melanoma: SWOG S0512. *PLoS One* 2012;7:e48787. Available at: <https://www.ncbi.nlm.nih.gov/pubmed/23226204>.

732. Piperno-Neumann S, Diallo A, Etienne-Grimaldi MC, et al. Phase II Trial of Bevacizumab in Combination With Temozolomide as First-Line Treatment in Patients With Metastatic Uveal Melanoma. *Oncologist* 2016;21:281-282. Available at: <https://www.ncbi.nlm.nih.gov/pubmed/26911405>.



NCCN Guidelines Version 2.2021

Melanoma: Uveal

733. Flaherty LE, Unger JM, Liu PY, et al. Metastatic melanoma from intraocular primary tumors: the Southwest Oncology Group experience in phase II advanced melanoma clinical trials. *Am J Clin Oncol* 1998;21:568-572. Available at: <https://www.ncbi.nlm.nih.gov/pubmed/9856657>.

734. Heppt MV, Steeb T, Schlager JG, et al. Immune checkpoint blockade for unresectable or metastatic uveal melanoma: A systematic review. *Cancer Treat Rev* 2017;60:44-52. Available at: <https://www.ncbi.nlm.nih.gov/pubmed/28881222>.

735. Steeb T, Wessely A, Ruzicka T, et al. How to MEK the best of uveal melanoma: A systematic review on the efficacy and safety of MEK inhibitors in metastatic or unresectable uveal melanoma. *Eur J Cancer* 2018;103:41-51. Available at: <https://www.ncbi.nlm.nih.gov/pubmed/30205280>.

736. Hodi FS, O'Day SJ, McDermott DF, et al. Improved survival with ipilimumab in patients with metastatic melanoma. *N Engl J Med* 2010;363:711-723. Available at: <http://www.ncbi.nlm.nih.gov/pubmed/20525992>.

737. Larkin J, Minor D, D'Angelo S, et al. Overall Survival in Patients With Advanced Melanoma Who Received Nivolumab Versus Investigator's Choice Chemotherapy in CheckMate 037: A Randomized, Controlled, Open-Label Phase III Trial. *J Clin Oncol* 2018;36:383-390. Available at: <https://www.ncbi.nlm.nih.gov/pubmed/28671856>.

738. Ascierto PA, Long GV, Robert C, et al. Survival Outcomes in Patients With Previously Untreated BRAF Wild-Type Advanced Melanoma Treated With Nivolumab Therapy: Three-Year Follow-up of a Randomized Phase 3 Trial. *JAMA Oncol* 2019;5:187-194. Available at: <https://www.ncbi.nlm.nih.gov/pubmed/30422243>.

739. Hodi FS, Chiarion-Sileni V, Gonzalez R, et al. Nivolumab plus ipilimumab or nivolumab alone versus ipilimumab alone in advanced melanoma (CheckMate 067): 4-year outcomes of a multicentre, randomised, phase 3 trial. *Lancet Oncol* 2018;19:1480-1492. Available at: <https://www.ncbi.nlm.nih.gov/pubmed/30361170>.

740. Schachter J, Ribas A, Long GV, et al. Pembrolizumab versus ipilimumab for advanced melanoma: final overall survival results of a multicentre, randomised, open-label phase 3 study (KEYNOTE-006). *Lancet* 2017;390:1853-1862. Available at: <https://www.ncbi.nlm.nih.gov/pubmed/28822576>.

741. Long GV, Flaherty KT, Stroyakovskiy D, et al. Dabrafenib plus trametinib versus dabrafenib monotherapy in patients with metastatic BRAF V600E/K-mutant melanoma: long-term survival and safety analysis of a phase 3 study. *Ann Oncol* 2017;28:1631-1639. Available at: <https://www.ncbi.nlm.nih.gov/pubmed/28475671>.

742. Robert C, Karaszewska B, Schachter J, et al. Improved overall survival in melanoma with combined dabrafenib and trametinib. *N Engl J Med* 2015;372:30-39. Available at: <http://www.ncbi.nlm.nih.gov/pubmed/25399551>.

743. Ascierto PA, McArthur GA, Dreno B, et al. Cobimetinib combined with vemurafenib in advanced BRAF(V600)-mutant melanoma (coBRIM): updated efficacy results from a randomised, double-blind, phase 3 trial. *Lancet Oncol* 2016;17:1248-1260. Available at: <https://www.ncbi.nlm.nih.gov/pubmed/27480103>.

744. Dummer R, Ascierto PA, Gogas HJ, et al. Encorafenib plus binimetinib versus vemurafenib or encorafenib in patients with BRAF-mutant melanoma (COLUMBUS): a multicentre, open-label, randomised phase 3 trial. *Lancet Oncol* 2018;19:603-615. Available at: <https://www.ncbi.nlm.nih.gov/pubmed/29573941>.

745. Zeldis JB, Heller C, Seidel G, et al. A randomized phase II trial comparing two doses of lenalidomide for the treatment of stage IV ocular melanoma. *J Clin Oncol* 2009;27:e20012-e20012. Available at: https://ascopubs.org/doi/abs/10.1200/jco.2009.27.15_suppl.e20012.

746. Atzpodien J, Terfloth K, Fluck M, Reitz M. Cisplatin, gemcitabine and treosulfan is effective in chemotherapy-pretreated relapsed stage IV uveal melanoma patients. *Cancer Chemother Pharmacol* 2008;62:685-688. Available at: <https://www.ncbi.nlm.nih.gov/pubmed/18084763>.



747. Nathan PD, Marshall E, Smith CT, et al. A Cancer Research UK two-stage multicenter phase II study of imatinib in the treatment of patients with c-kit positive metastatic uveal melanoma (ITEM). *J Clin Oncol* 2012;30:8523-8523. Available at:

https://ascopubs.org/doi/abs/10.1200/jco.2012.30.15_suppl.8523.

748. Kaempgen E, Schmid M, Erdmann M, et al. Predictable clinical responses to sorafenib in stage IV uveal melanoma. *J Clin Oncol* 2012;30:e19032-e19032. Available at:

https://ascopubs.org/doi/abs/10.1200/jco.2012.30.15_suppl.e19032.

749. Wallander ML, Layfield LJ, Emerson LL, et al. KIT mutations in ocular melanoma: frequency and anatomic distribution. *Mod Pathol* 2011;24:1031-1035. Available at:

<https://www.ncbi.nlm.nih.gov/pubmed/21478825>.

750. Dogrusoz M, Jager MJ. Genetic prognostication in uveal melanoma. *Acta Ophthalmol* 2018;96:331-347. Available at:

<https://www.ncbi.nlm.nih.gov/pubmed/29105334>.

751. Atkinson TM, Hay JL, Shoushtari A, et al. Relationship between physician-adjudicated adverse events and patient-reported health-related quality of life in a phase II clinical trial (NCT01143402) of patients with metastatic uveal melanoma. *J Cancer Res Clin Oncol* 2017;143:439-445. Available at: <https://www.ncbi.nlm.nih.gov/pubmed/27921276>.

752. Maio M, Danielli R, Chiarion-Sileni V, et al. Efficacy and safety of ipilimumab in patients with pre-treated, uveal melanoma. *Ann Oncol* 2013;24:2911-2915. Available at:

<https://www.ncbi.nlm.nih.gov/pubmed/24067719>.

753. Khatkhat MA, Fisher R, Hughes P, et al. Ipilimumab activity in advanced uveal melanoma. *Melanoma Res* 2013;23:79-81. Available at:

<https://www.ncbi.nlm.nih.gov/pubmed/23211837>.

754. Kelderman S, van der Kooij MK, van den Eertwegh AJ, et al. Ipilimumab in pretreated metastatic uveal melanoma patients. Results of the Dutch Working group on Immunotherapy of Oncology (WIN-O). *Acta Oncol* 2013;52:1786-1788. Available at:

<https://www.ncbi.nlm.nih.gov/pubmed/23607756>.

755. Danielli R, Ridolfi R, Chiarion-Sileni V, et al. Ipilimumab in pretreated patients with metastatic uveal melanoma: safety and clinical efficacy. *Cancer Immunol Immunother* 2012;61:41-48. Available at:

<https://www.ncbi.nlm.nih.gov/pubmed/21833591>.

756. Ahmad SS, Qian W, Ellis S, et al. Ipilimumab in the real world: the UK expanded access programme experience in previously treated advanced melanoma patients. *Melanoma Res* 2015;25:432-442. Available at: <https://www.ncbi.nlm.nih.gov/pubmed/26225580>.

757. Shaw H, Larkin J, Corrie P, et al. Ipilimumab for Advanced Melanoma in an Expanded Access Programme (EAP): Ocular, Mucosal and Acral Subtype UK Experience. *Ann Oncol* 2012;23:ix374. Available at: <http://www.sciencedirect.com/science/article/pii/S0923753420337042>.

758. Jung M, Lee J, Kim TM, et al. Ipilimumab Real-World Efficacy and Safety in Korean Melanoma Patients from the Korean Named-Patient Program Cohort. *Cancer Res Treat* 2017;49:44-53. Available at:

<https://www.ncbi.nlm.nih.gov/pubmed/27121719>.

759. Kottschade LA, McWilliams RR, Markovic SN, et al. The use of pembrolizumab for the treatment of metastatic uveal melanoma. *Melanoma Res* 2016;26:300-303. Available at:

<https://www.ncbi.nlm.nih.gov/pubmed/26848796>.

760. Middleton MR, McAlpine C, Woodcock VK, et al. Tebentafusp, A TCR/Anti-CD3 Bispecific Fusion Protein Targeting gp100, Potently Activated Antitumor Immune Responses in Patients with Metastatic Melanoma. *Clin Cancer Res* 2020. Available at:

<https://www.ncbi.nlm.nih.gov/pubmed/32816891>.



761. Huguenin PU, Kieser S, Glanzmann C, et al. Radiotherapy for metastatic carcinomas of the kidney or melanomas: an analysis using palliative end points. *Int J Radiat Oncol Biol Phys* 1998;41:401-405. Available at: <https://www.ncbi.nlm.nih.gov/pubmed/9607358>.